



**PATIENT**

Lucy Stepinsky

**SPECIES**

Canine

**BREED**

Miniature Pinscher

**SEX**

Spayed Female

**AGE**

13 years

**WEIGHT**

17 lbs

**INTERPRETED BY**

Eric Lindquist, DMV  
DABVP, Cert. IVUSS

**IMAGING PERFORMED BY**

Peter Nelson

**HOSPITAL NAME**

Valley VS

**REFERRING VET**

Dr. Crum

**INVOICE**

96739

**DATE**

3/9/22

**PRESENTING CLINICAL SIGNS**

History: Vomiting and diarrhea 2/24/22. Bloody stool and wobbly on 3/1/22 (on tramadol). Not eating. Bacteria and blood in urine. Doing better on Enrofloxacin  
Abnormal PE/Chem/CBC/UA Results: 2/24 ALT 336, ALKP 630 otherwise within normal

**ULTRASONOGRAPHIC EXAMINATION OF THE ABDOMEN**

**Urinary System**

The **urinary bladder**, trigone, and pelvic urethra presented normal thicknesses and normal tone. The ureters were not visible which is normal. No uroliths or sediment were visualized and anechoic urine was present. No evidence of inflammatory or neoplastic changes was noted. Ureteral papillae were normal.

The **kidneys** revealed largely normal size and structure, corticomedullary definition and ratio (cortex 1/3 of medulla) were essentially maintained with some age-related loss of curvilinear patterns regarding the capsule and C/M junction. The cortices presented largely uniform texture with some increased echogenicity expected for this age patient. Medullary structure differed distinctly from that of the cortex and no evidence of pelvic dilation was present. The left kidney measured 4.0 cm. The right kidney measured 4.0 cm.

**Adrenal Glands**

Both **adrenal glands** were visualized and recognized as having normal shape, size, position and echogenicity for this breed. The phrenic vasculature, glandular echogenicity and detail were unremarkable. Capsule, cortex, and medullary definition were normal for this age patient. The right adrenal gland measured 0.5 cm in maximum width.

**Spleen**

The **spleen** presented a smooth homogeneous parenchyma hyperechoic to liver and renal cortical parenchyma. The capsule was smooth without noticeable expansion or deviation from within the spleen or adjacent pathology. The splenic vasculature demonstrated normal volume without signs of congestion or thrombosis. No sonographic evidence of acute or chronic inflammatory, neoplastic, or infarctual changes was noted.

**Liver**

The **liver** revealed slightly increased portal markings with coarse architecture. History of cholangitis is likely. The gallbladder presented acceptably thin walls with primarily anechoic content. The cystic and common bile ducts were normal. No pathological hepatic lymphadenopathy was evident. No overt structural evidence of inflammatory, infiltrative or regenerative pathology was evident.



**PATIENT**

**Gastrointestinal**

Lucy Stepinsky

Examination of the **gastrointestinal tract** revealed a stomach and intestine free of stasis, of normal wall thickness, acceptable curvilinear mural detail, and peristaltic activity. Small and large intestine demonstrated normal luminal chyme and stool consistency respectively. No obstructive or overt infiltrative disease was noted. No associated abnormal lymphatic activity was noted.

**SPECIES**

Canine

**BREED**

Miniature Pinscher

**Pancreas**

The base and limbs of the **pancreas** were observed to be largely isoechoic to surrounding omental fat. Pancreatic duct and capsular contour were acceptably normal and parenchyma respected normal curvilinear patterns. No overt evidence of active inflammatory or neoplastic disease was noted.

**SEX**

Spayed Female

**ULTRASONOGRAPHIC FINDINGS**

Hepatic remodeling. History of cholangitis.

**AGE**

13 years

**INTERPRETATION OF THE FINDINGS & FURTHER RECOMMENDATIONS**

**WEIGHT**

17 lbs

Bile acid profile is recommended. Supportive care for GI upset is indicated as well as FNA of the liver to assess inflammatory cell type. Core liver biopsy would be ideal of the liver especially if the bile acids are elevated. Leptospirosis titers are warranted to ensure a subclinical infection is not present.

**INTERPRETED BY**

Eric Lindquist, DMV  
DABVP, Cert. IVUSS

**IMAGING PERFORMED BY**

Peter Nelson

**HOSPITAL NAME**

Valley VS

**REFERRING VET**

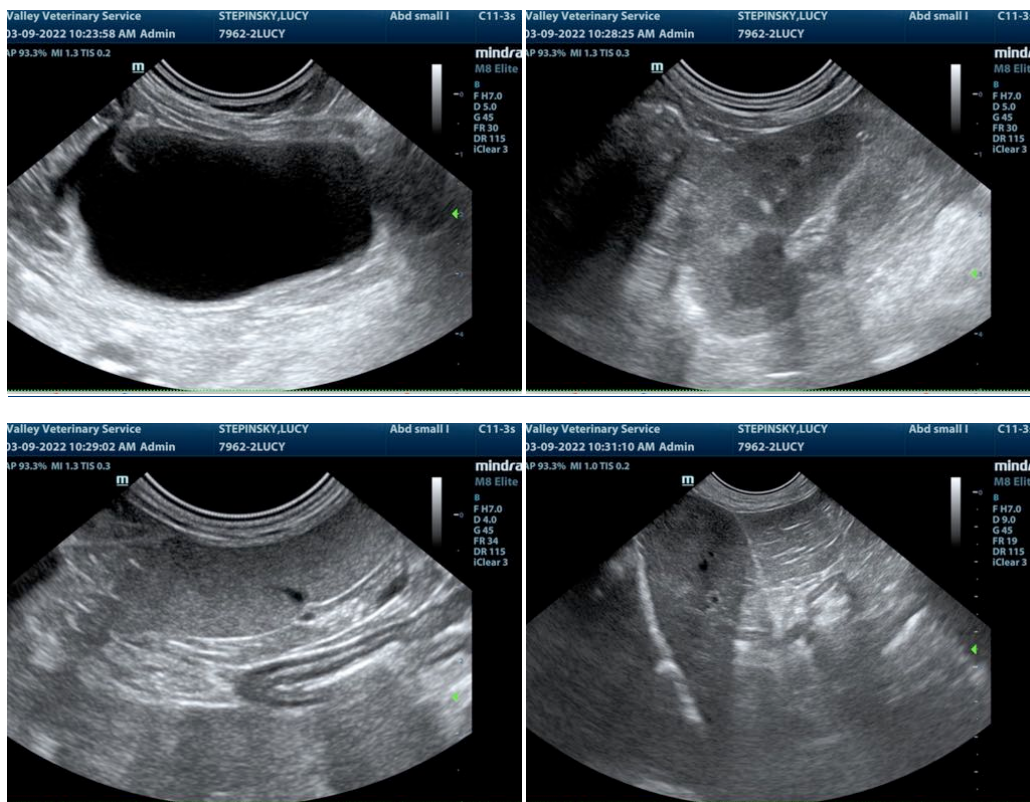
Dr. Crum

**INVOICE**

96739

**DATE**

3/9/22





**PATIENT**

Lucy Stepinsky

**SPECIES**

Canine

**BREED**

Miniature Pinscher

**SEX**

Spayed Female

**AGE**

13 years

**WEIGHT**

17 lbs

**INTERPRETED BY**

Eric Lindquist, DMV  
DABVP, Cert. IVUSS

**IMAGING PERFORMED BY**

Peter Nelson

**HOSPITAL NAME**

Valley VS

**REFERRING VET**

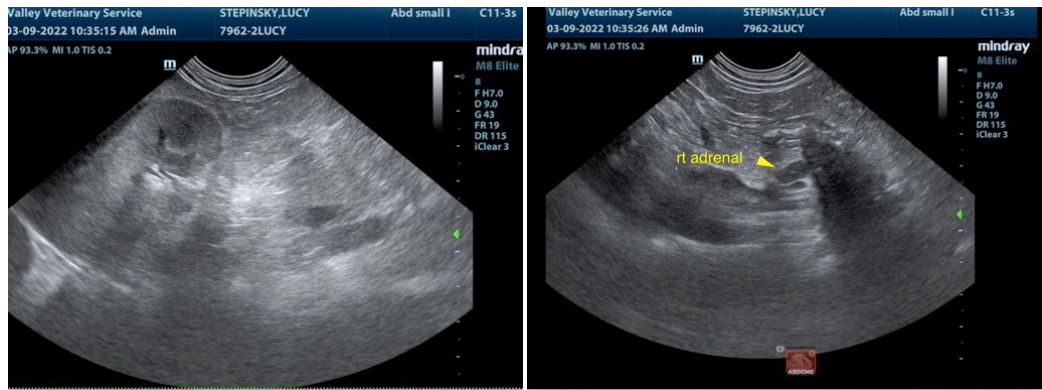
Dr. Crum

**INVOICE**

96739

**DATE**


3/9/22



The information and recommendations provided are based on the images presented by the referring veterinarian/sonographer. No evaluation can be communicated regarding pathology that was not visible in the image/video clips provided.

Thank you for this referral. If the clinical or image interpretation does not parallel your findings or if I can be of any further assistance please contact me.

Eric Lindquist, DMV, DABVP, Cert. IVUSS, CEO of SonoPath.com  
info@SonoPath.com



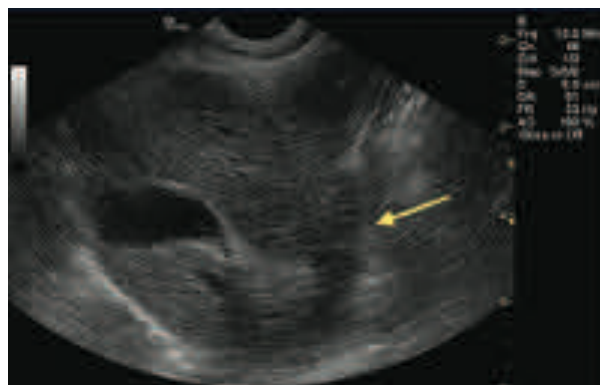The following is an applicable excerpt from the *Curbside Guide to Diagnosis & Treatment of Sonographic Disease* offered by [SonoPath.com](http://sonopath.com) Lindquist, Frank, Lobetti, and Modler.

An essential quick guide for every general practitioner and sonographer.

<https://sonopath.com/products/curbside-guide-editing-due-release-12012015>

**Canine Liver Disease & Treatment Recommendations**

<http://www.sonopath.com/K9LiverDisease>



Long axis image of the liver showing a slightly echogenic and thickened gall bladder with mild coarsely echogenic portal markings. The parenchyma is hypoechoic to falciform fat in the near field and mild lobar swelling (arrow) is noted suggestive for an acute process. Diagnosis: Acute on early chronic cholangiohepatitis. The patient was leptospirosis positive and responded to Ampicillin therapy.



**PATIENT**

Lucy Stepinsky

**Description:** The etiologic causes of canine hepatic disease are vast and varied. Some cases may progress fairly rapidly, while others will remain static for a considerable length of time or even eventually reverse. Regardless of the cause, management is crucial to maintaining and optimizing quality of life. If possible, practitioners should obtain and be guided by a pathologic diagnosis so they can administer a treatment attuned to the underlying disease and arrive at a more exact prognosis.

**SPECIES**

Canine

**Dietary Management:** A lower protein diet to support liver dysfunction should be initiated, especially in cases where hepatic encephalopathy is also present. Since dietary protein is low, the protein quality and bioavailability must conversely be high. It should be noted that a protein-restricted diet is not appropriate in all cases of hepatic disease, especially during the early phases, as protein restriction is unnecessary when there are no signs of significant hepatic dysfunction.

**BREED**

Miniature Pinscher

Therapeutic diets, such as Hill's® i/d® and Royal Canin® Hepatic™, are excellent choices and contain enhanced levels of nutrients such as, but not limited to:

**SEX**

Spayed Female

- Branched chain amino acids, which bypass liver metabolism and are used directly for skeletal muscle accretion.
- Vitamin E, which helps minimize and reduce oxidative damage and stress from free radicals produced by stressed hepatocytes.
- Vitamin B complex, which helps drive intermediary metabolism.
- Reduced copper.
- Extremely digestible protein sources with high biologic values, which help minimize the total amount of dietary protein needed and thus reduce blood ammonia levels.
- Carnitine, which helps drive fatty acids into the mitochondria for beta-oxidation and positive cellular energy balance.

**AGE**

13 years

**WEIGHT**

17 lbs

**INTERPRETED BY**

Eric Lindquist, DMV  
DABVP, Cert. IVUSS

**Medical Management:** The following list of medications is commonly used in the management of various hepatopathies or in the face of hepatic failure; however, each patient should be managed as an individual, and not all of the medications listed here are appropriate for each animal. One must always consider the definitive diagnosis of one's patient when developing a therapeutic plan. What follows is an outline of medical management recommendations for cholangiohepatitis and inflammatory hepatopathy/chronic hepatitis.

**IMAGING PERFORMED BY**

Peter Nelson

**Cholangiohepatitis**

1. *Broad-spectrum antibiotics*

**HOSPITAL NAME**

Valley VS

a) Amoxicillin: Give 20 mg/kg BID or amoxicillin/clavulanic acid (13.75 mg/kg PO BID) for potential suppurative hepatitis. Options: ampicillin: 20 mg/kg IV TID; cephalexin: 20 mg/kg IV or PO TID; enrofloxacin: 2.5-5 mg/kg PO BID if cholangiohepatitis is present or to decrease ammonia production; gentamycin: 2 mg/kg TID IM or SC for 5-7 days if sepsis or peritonitis is present. Monitor renal function if aminoglycosides are utilized.

**REFERRING VET**

Dr. Crum

b) Metronidazole: Give 10-20 mg/kg BID in combination with amoxicillin/clavulanic acid or enrofloxacin for cholangiohepatitis because of its efficacy against anaerobic bacteria and/or for its immunomodulating effects. The dose is decreased to 7.5 mg/kg PO TID in the face of hepatic failure and/or encephalopathy. Controls ammonia production in the colon, decreases bacteria absorbed through portal circulation, and reduces cell-mediated immune responses (anti-inflammatory properties).

**INVOICE**

96739

**DATE**

3/9/22

2. *Hepatic support*



**PATIENT**

Lucy Stepinsky

a) S-adenosylmethionine (SAME): Give 20 mg/kg/day PO on an empty stomach (1-2 hours before feeding). It is available in 90 mg tablets that are not to be broken. SAME replenishes glutathione and aids in cellular detoxification; it also has anti-arthritis effects. SAME is an anti-inflammatory and antioxidant. It also promotes hepatocellular regeneration and rectifies RBC membrane abnormalities in dogs with liver disease or oxidative damage.

**SPECIES**

Canine

**BREED**

Miniature Pinscher

b) Milk Thistle: Administer as silybin or silymarin extracts (a high-quality supplement is essential). Acts as an antioxidant and free radical scavenger; decreases hepatotoxin binding; improves glutathione concentrations; aids in iron chelating; and promotes cholestasis. Give 5-15 mg/kg/day PO.

**SEX**

Spayed Female

c) Ursodiol (Actigall): Give 10-15 mg/kg PO once daily, with food, to stimulate bile flow and decrease cholestasis. Tablets (250 mg) or capsules (300 mg) are available; however, ursodiol can also be compounded into a liquid to dose small patients. It has immunomodulatory, anti-fibrotic, and choleric effects, anti-copper storage benefits, and stabilizes mitochondrial function.

**AGE**

13 years

d) Vitamin E: Must be coupled with good nutrition and other antioxidants to avoid accumulation of tocopheroxyl radicals. To that end, supplementation with SAME may help ensure that adequate GSH (mitochondrial glutathione) concentrations are achieved. Give 10-15 IU/kg/day PO (100-400 IU) in a water-soluble form twice daily, as well as with Vitamin C 25 mg/kg/day.

**WEIGHT**

17 lbs

**INTERPRETED BY**

Eric Lindquist, DMV  
DABVP, Cert. IVUSS

e) Cobalamin and Thiamine (B12 and B1): Give 250ug SC weekly.

**IMAGING PERFORMED BY**

Peter Nelson

**Inflammatory hepatopathy/chronic hepatitis**

*1. Immunosuppressive agents*

**HOSPITAL NAME**

Valley VS

a) Prednisone or prednisolone: Administer if inflammatory disease has been diagnosed by biopsy, beginning at 2 mg/kg/day for 2-4 weeks; subsequently reduce to 1 mg/kg/day. Once remission has been achieved, taper to 0.5 mg/kg/day (or to the lowest tolerable dose) over 2-4 weeks. Steroids may be discontinued if a different immunosuppressive medication is effective at controlling inflammation (i.e., azathioprine or cyclosporine) since they are contraindicated with hepatic encephalopathy. Possible negative sequelae of corticosteroids include increased water retention and potentiation of gastrointestinal ulceration. In the face of portal hypertension and ascites, dexamethasone is preferred—it does not exhibit mineralocorticoid activity and thus does not potentiate water retention as compared to prednisone—at 0.2-0.4 mg/kg orally once daily. Taper in a similar manner.

**REFERRING VET**

Dr. Crum

b) Azathioprine (Imuran): Give 50 mg/m<sup>2</sup>/day or 2 mg/kg/day as a long-term alternative to prednisone. The dose can be decreased to 1 mg/kg and eventually given every other day if there is a positive response. Check CBC and platelet count biweekly for the first 2 months and then monthly thereafter. Taper every 2-4 weeks to the lowest effective dose while monitoring transaminase levels. It can often be dosed on alternate days to prednisone. Possible negative side effects include bone marrow suppression and hepatic necrosis. Cyclosporine has been proposed as an alternative immunosuppressant in the management of chronic hepatitis and may allow one to cease concurrent steroid therapy; however, this has not been thoroughly investigated as of yet.

**INVOICE**

96739

**DATE**

3/9/22



<b>PATIENT</b>	<b>2. Hepatic Support</b>
Lucy Stepinsky	See medications listed in the previous section.
<b>SPECIES</b>	<b>3. Anti-fibrotics</b>
Canine	a) Colchicine: Give 0.03 mg/kg/day. Colchicine acts as an anti-inflammatory agent, stabilizes membranes, and stimulates collagenase production, thereby diminishing fibrosis. Colchicine should be used to treat hepatic fibrosis based on biopsy results; however, it can also be considered when ascites is present, and when hepatic fibrosis and cirrhosis are highly suspected based on sonographic appearance and clinical findings. It can result in adverse effects, including vomiting, diarrhea, and inappetence. Discontinue until clinical signs resolve, and reinstitute at a lower dose and up-titrate slowly.
<b>BREED</b>	<b>4. Hepatic Encephalopathy</b>
Miniature Pinscher	a) Lactulose: Give 0.5 ml/kg orally 2-3 times daily to soften the stool. It helps manage hepatic encephalopathy by combining with ammonium in the GI tract and thus decreasing circulating ammonia levels. Use in conjunction with low dose metronidazole. Lactulose can also be given as a retention enema in an encephalopathic crisis.
<b>SEX</b>	b) Metronidazole: Give at 7.5 mg/kg PO TID. Neomycin is an alternative and can be administered at 22 mg/kg PO BID-TID.
Spayed Female	c) L-Carnitine: Give 200-400 mg/day. Normally synthesized by the liver, L-Carnitine enhances ammonia elimination and is indicated in cases of hepatic encephalopathy and lipidosis. Carnitine must be in the L-form.
<b>AGE</b>	<b>5. Copper Chelation</b>
13 years	Use chelation when copper toxicity has been documented on biopsy and quantification has been performed to confirm toxic levels.
<b>WEIGHT</b>	a) D-penicillamine: Give 10-15 mg/kg PO BID on an empty stomach. This is a copper chelator and should only be used based on a quantitative analysis of copper. Possible side effects include vomiting and inappetence. Do not give in conjunction with zinc.
17 lbs	b) 2,3,2 Tetramine (Syprine, Cuprid): Give 5-7 mg/kg PO BID on an empty stomach (1-2 hours before eating). An alternative to D-penicillamine for those dogs that are intolerant.
<b>INTERPRETED BY</b>	c) Zinc gluconate, acetate, or sulfate (acetate is best tolerated): Give 15-10 mg/kg elemental zinc divided BID for 2-6 months as a loading dose. Administer on an empty stomach (30-60 minutes before eating). Reduce to half the dose during the maintenance phase. A low copper diet is preferred (i.e., therapeutic diets, such as Hill's I/d® or Royal Canin® Hepatic™, are advisable). Zinc binds with intestinal copper to avoid absorption in the gastrointestinal tract and may be used alone in mild cases of copper toxicity. The goal is to reach zinc serum levels of 200-600 ug/dl; levels should initially be measured every 2-3 months. Give this medication on an empty stomach or with tuna fish to avoid vomiting. Zinc is not as effective as D-penicillamine and is only used in mild cases. It is not used in conjunction with D-penicillamine.
Eric Lindquist, DMV DABVP, Cert. IVUSS	<b>6. Portal Hypertension and Ascites</b>
<b>IMAGING PERFORMED BY</b>	a) Spironolactone: If ascites is present secondary to portal hypertension, spironolactone can be dosed at 1-2 mg/kg PO BID; it is the diuretic of choice. Alternatively, spironolactone can be used in conjunction with furosemide (0.5-1 mg/kg PO BID) or hydrochlorothiazide; one should administer 1 mg/kg PO BID if given in conjunction with another diuretic. Monitor renal function and electrolytes
Peter Nelson	
<b>HOSPITAL NAME</b>	
Valley VS	
<b>REFERRING VET</b>	
Dr. Crum	
<b>INVOICE</b>	
96739	
<b>DATE</b>	
3/9/22	



**PATIENT** diligently.

Lucy Stepinsky b) Famotidine: Give 0.5 mg/kg PO BID in cases of portal hypertension that result in gastrointestinal bleeding/melena.

**SPECIES** **General Notes on Therapeutic Management:** Given that a primary function of the liver is to metabolize oral medications via the portal system (first past effect), numerous medications may result in higher systemic exposure to parent compounds in the face of hepatic insufficiency or failure. Drugs that are inactivated by the liver, produce hepatic damage, or require hepatic metabolism should be avoided. These include: lincomycin, clindamycin, streptomycin, chloramphenicol, sulfonamides, erythromycin, hetacillin, phenobarbital, diazepam, oxy- or chloro-tetracyclines,azole antifungals, nonsteroidal anti-inflammatory drugs (NSAIDs), theophylline or chloramphenicol, combinations of cimetidine and metronidazole, and combinations of enrofloxacin and theophylline or cisapride. In cases of hepatic lipidosis, glucocorticoids, anabolic steroids, and lipotropic agents containing methionine should be avoided as they result in the production of encephalopathic toxins (metacarpans). Glucocorticoids are indicated for cholangitis, but only after lymphoma and hepatic lipidosis have been ruled out.

Canine

**BREED**

Miniature Pinscher

**SEX**

Spayed Female

**AGE**

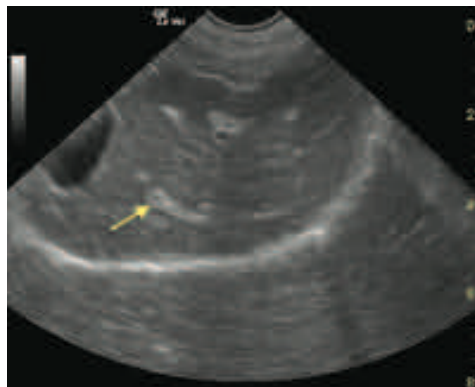13 years

**WEIGHT**

17 lbs

**INTERPRETED BY**

Eric Lindquist, DMV  
DABVP, Cert. IVUSS



Short axis of the liver in a dog with leptospirosis and chronic hepatitis. Note the overall increase in echogenicity typically seen in chronic disease. Multifocal hyperechoic patches and increased portal markings (arrow) are present.

**IMAGING PERFORMED BY**

Peter Nelson

**HOSPITAL NAME**

Valley VS

**REFERRING VET**

Dr. Crum

**INVOICE**

96739

**DATE**

3/9/22

**References:**

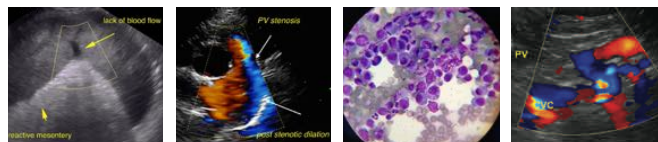
Bauer E. Hepatic disease, nutritional therapy, and the metabolic environment. *J Am Vet Med Assoc* 1996;209(11):1850-54.

Bradley AM and Twedt DC. Cyclosporine therapy for canine chronic hepatitis: a retrospective study. Proceedings from the American College of Veterinary Internal Medicine, Anaheim, CA, June 15-18, 2011.

Center SA. Chronic hepatitis, cirrhosis, breed-specific hepatopathies, copper storage hepatopathy, suppurative hepatitis, granulomatous hepatitis, and idiopathic hepatic fibrosis. In: Guilford WG, Center SA, Strombeck DR, Williams DA, and Meyer DJ, eds: *Strombeck's Small Animal Gastroenterology 3rd ed.* Philadelphia, PA: WB Saunders; 1996:705-65.

Center S. Metabolic, antioxidant, nutraceutical, probiotic, and herbal therapies relating to the management of hepatobiliary disorders. *Vet Clin North Am Small Anim Pract* 2004;34(1):67-172.

Center SA. Diagnostic and managerial pearls for selected hepatobiliary disorders. Proceedings from the American College of Veterinary Internal Medicine. New Orleans, LA, May 30-June 2, 2012.



**PATIENT**

Davenport D. Antimicrobial therapy for gastrointestinal, pancreatic, and hepatic disorders. *Probl Vet Med* 1990;2(2):374-93.

Lucy Stepinsky

**SPECIES**

Hackett T, Twedt D, Gustafson D. Milk thistle and its derivative compounds: a review of opportunities for treatment of liver disease. *J Vet Intern Med* 2013;27(1):10-16.

Canine

Thompson M, Meyer D, Senior D. Effects of treatment with ursodeoxycholic acid on bile acid profiles in a dog with chronic hepatic disease. *J Vet Intern Med* 1991;5(2):130.

**BREED**

Miniature Pinscher

**SEX**

Spayed Female

**AGE**

13 years

**WEIGHT**

17 lbs

**INTERPRETED BY**

Eric Lindquist, DMV  
DABVP, Cert. IVUSS

**IMAGING  
PERFORMED BY**

Peter Nelson

**HOSPITAL NAME**

Valley VS

**REFERRING VET**

Dr. Crum

**INVOICE**

96739

**DATE**

3/9/22