



PATIENT

Jameson Foley

SPECIES

Canine

BREED

Bulldog Mix

SEX

Neutered male

AGE

9 years

WEIGHT

79.4 lbs

INTERPRETED BY

Eric Lindquist, DMV
DABVP, Cert. IVUSS

IMAGING PERFORMED BY

M Kermendy CVT

HOSPITAL NAME

Wauwautosa VC

REFERRING VET

Dr. Haynes

INVOICE

96728

DATE

3/9/22

PRESENTING CLINICAL SIGNS

History: History of seizures, IBD, allergies, UTI. Starting in November 2021 dog presented for being PU/PD. He was diagnosed with a UTI that cultured E-coli. Since November 2021 UTIs have recurred off and on. Pet is on several different medications for his issues. Seizures are mostly controlled (pet on phenobarbital, KBr, and Keppra). Currently on ciprofloxacin. for UTI. Screening for urinary tract stones, kidney disease, neoplasia, other.

ULTRASONOGRAPHIC EXAMINATION OF THE ABDOMEN

Urinary System

The **urinary bladder**, trigone, and pelvic urethra presented normal thicknesses and normal tone. The pelvic urethra was imaged 3.0 cm beyond the cystourethral junction. The ureters were not visible which is normal. No uroliths or sediment were visualized and anechoic urine was present. No evidence of inflammatory or neoplastic changes was noted. Ureteral papillae were normal.

The **kidneys** revealed normal size and structure, corticomedullary definition and ratio for this age. The cortices presented largely uniform texture with normal echogenic relationship to liver and spleen. Medullary structure differed distinctly from the cortex. The capsules were acceptably uniform without significant irregularities. The left kidney measured 6.68 cm. The right kidney measured 7.68 cm with slight pyelectasia.

Adrenal Glands

Both **adrenal glands** were visualized and recognized as having normal shape, size, position and echogenicity for this breed. The phrenic vasculature, glandular echogenicity and detail were unremarkable. Capsule, cortex, and medullary definition were normal for this age patient.

Spleen

The **spleen** was folded upon itself and is mildly enlarged. This is typical for the breed.

Liver

The **liver** images from right and left intercostal as well as subcostal views revealed subjectively normal liver size, contour, and structure. Some age-related parenchymal remodeling was noted but likely not clinically significant at this time. Vascular and biliary tracts were of normal volume and no evidence of congestion was noted. The gallbladder presented some dependent debris with essentially normal contour. The cystic and common bile ducts were normal. No overt evidence of active inflammatory, infiltrative or regenerative pathology was noted but should be paired with current or past LE elevations regarding any clinical significance to this presentation. The hepatic lymph nodes were unremarkable.

Gastrointestinal

Examination of the **gastrointestinal tract** revealed a stomach and intestine free of stasis, of normal wall thickness, acceptable curvilinear mural detail, and peristaltic activity. Small and large intestine



PATIENT

demonstrated normal luminal chyme and stool consistency respectively. No obstructive or overt infiltrative disease was noted. No associated abnormal lymphatic activity was noted.

Jameson Foley

SPECIES

Pancreas

Canine

The base and limbs of the **pancreas** were observed to be largely isoechoic to surrounding omental fat. Pancreatic duct and capsular contour were acceptably normal and parenchyma respected normal curvilinear patterns. No overt evidence of active inflammatory or neoplastic disease was noted.

BREED

Bulldog Mix

ULTRASONOGRAPHIC FINDINGS

SEX

Unremarkable lower urinary tract, slight pyelectasia of the right kidney.

Neutered male

INTERPRETATION OF THE FINDINGS & FURTHER RECOMMENDATIONS

AGE

Longer treatment for UTI may be appropriate. There was no evidence of neoplasia or calculi.

9 years

WEIGHT

Canine Chronic UTI Protocol

79.4 lbs

I recommend **Enrofloxacin** (5-10 mg/kg SID PO) (In patients > 1 year of age) in late pm after urination to maximize urinary concentrations overnight. This assumes that culture supports this use. Repeat **culture** at 3-4 weeks and continue treatment at least 7-10 days post negative urinary sediment and negative culture. *Note: Negative culture does not necessarily mean lack of UTI.* Other favorite antibiotics for chronic UTI include third generation Cefa (Ceftiafur or similar s.i.d. injectable) or Clavamox. If suspicion of occult urinary incontinence is present then **phenylpropanolamine (PPA)** (1-2 mg/kg BID) can be employed long term to enhance urethral tone.

INTERPRETED BY

Eric Lindquist, DMV
DABVP, Cert. IVUSS

IMAGING PERFORMED BY

M Kermendy CVT

HOSPITAL NAME

Wauwautosa VC

REFERRING VET

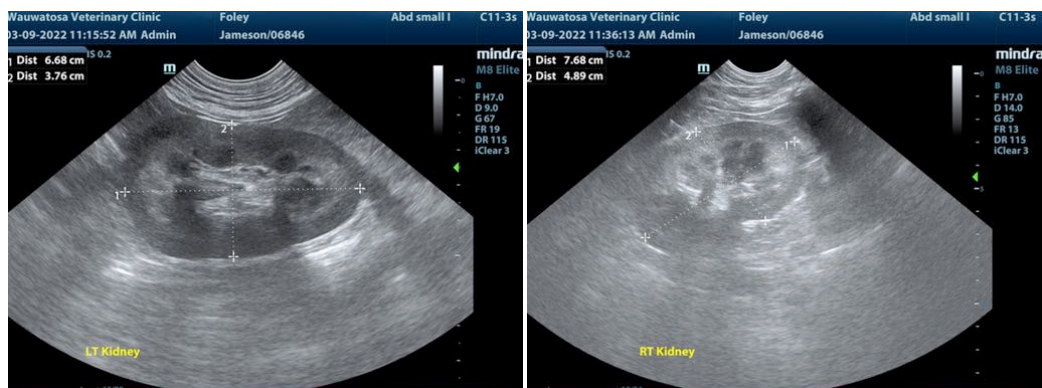
Dr. Haynes

INVOICE

96728

DATE

3/9/22





PATIENT

Jameson Foley

SPECIES

Canine

BREED

Bulldog Mix

SEX

Neutered male

AGE

9 years

WEIGHT

79.4 lbs

INTERPRETED BY

Eric Lindquist, DMV
DABVP, Cert. IVUS

IMAGING PERFORMED BY

M Kermendy CVT

HOSPITAL NAME

Wauwautosa VC

REFERRING VET

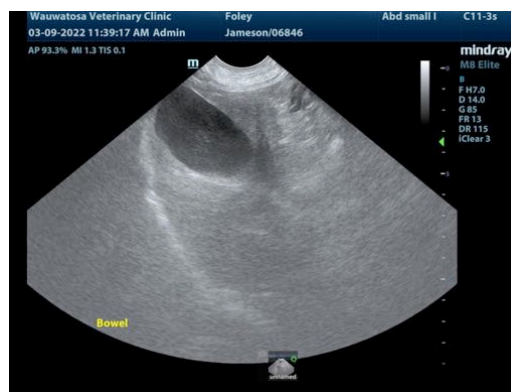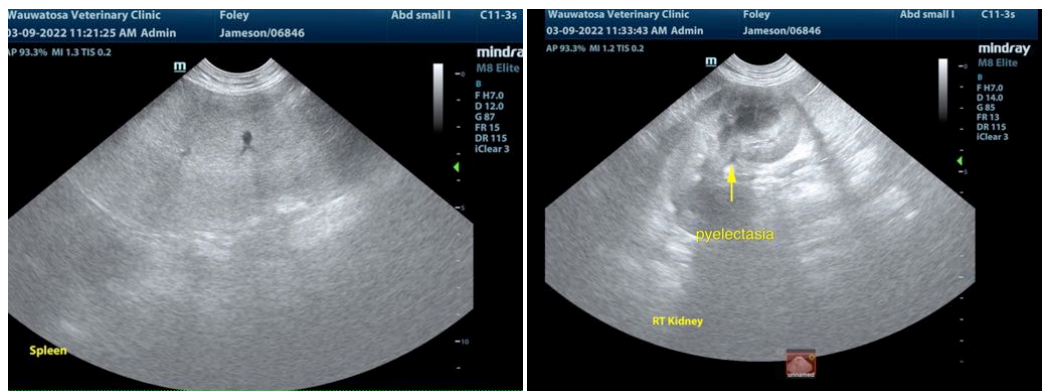
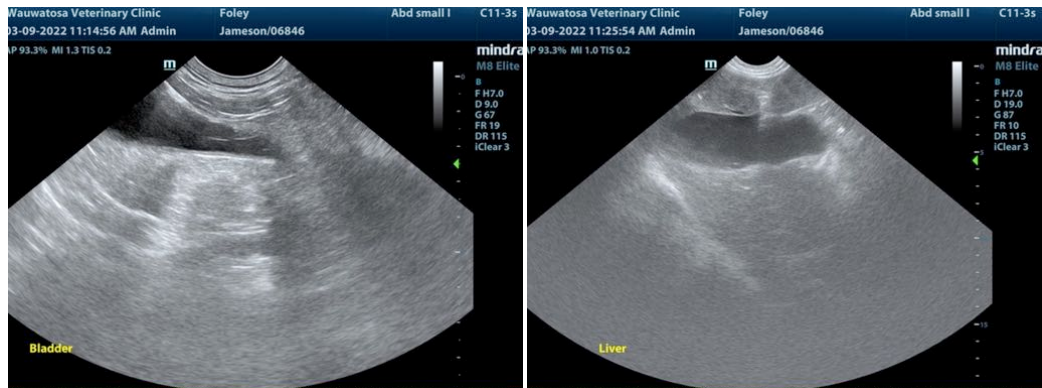Dr. Haynes

INVOICE

96728

DATE

3/9/22



The information and recommendations provided are based on the images presented by the referring veterinarian/sonographer. No evaluation can be communicated regarding pathology that was not visible in the image/video clips provided.

Thank you for this referral. If the clinical or image interpretation does not parallel your findings or if I can be of any further assistance please contact me.



PATIENT

Jameson Foley

Eric Lindquist, DMV, DABVP, Cert. IVUSS, CEO of SonoPath.com
info@SonoPath.com

SPECIES

Canine

BREED

Bulldog Mix

SEX

Neutered male

AGE

9 years

WEIGHT

79.4 lbs

INTERPRETED BY

Eric Lindquist, DMV
DABVP, Cert. IVUSS

**IMAGING
PERFORMED BY**

M Kermendy CVT

HOSPITAL NAME

Wauwautosa VC

REFERRING VET

Dr. Haynes

INVOICE

96728

DATE

3/9/22