



PATIENT

Cali Maxwell

SPECIES

Canine

BREED

Golden Retriever

SEX

Spayed Female

AGE

13.5 Pounds

WEIGHT

31.8 kg

INTERPRETED BY

Eric Lindquist, DMV

DABVP, Cert. IVUSS

IMAGING PERFORMED BY

Dr. Laura De Cordon

HOSPITAL NAME

Mason Dixon Animal
Emergency Hospital

REFERRING VET

Dr. Laura De Cordon

INVOICE

36002

DATE

3/9/22

PRESENTING CLINICAL SIGNS

Diagnosed w/ Pancreatitis and colitis on 3/8. vomiting, anorexia, diarrhea. mild dehydration, no fever, normal lytes; high normal bun/creat - r/o prerenal azotemia since phosphorus is normal. On xray prominent rugal folds; gas filled SI and LI.

ULTRASONOGRAPHIC EXAMINATION OF THE ABDOMEN

Urinary System

The **urinary bladder**, trigone, and pelvic urethra presented normal thicknesses and normal tone. The ureters were not visible which is normal. No uroliths or sediment were visualized and anechoic urine was present. No evidence of inflammatory or neoplastic changes were noted. Ureteral papillae were normal. The pelvic urethra was imaged 1.0 cm beyond the cystourethral junction.

The **kidneys** revealed largely normal size and structure, corticomedullary definition and ratio (cortex 1/3 of medulla) were essentially maintained with some age-related loss of curvilinear patterns regarding the capsule and C/M junction. The cortices presented largely uniform texture with some increased echogenicity expected for his age patient. Medullary structure differed distinctly from that of the cortex and no evidence of pelvic dilation was present. The kidneys measured 6.0 cm each.

Adrenal Glands

The **adrenal glands** were not visualized.

Spleen

The **spleen** presented a smooth homogeneous parenchyma hyperechoic to liver and renal cortical parenchyma. The capsule was smooth without noticeable expansion or deviation from within the spleen or adjacent pathology. The splenic vasculature demonstrated normal volume without signs of congestion or thrombosis. No sonographic evidence of acute or chronic inflammatory, neoplastic, or infarctual changes were noted.

Liver

The **liver** revealed heterogeneous parenchymal changes with a 3.0 cm right medial hyperechoic nodule with irregular contour. The gallbladder and common bile duct were unremarkable.

Gastrointestinal

Examination of the **gastrointestinal tract** revealed a stomach and intestine free of stasis, of normal wall thickness, acceptable curvilinear mural detail, and peristaltic activity. Small and large intestine demonstrated normal luminal chyme and stool consistency respectively. No obstructive or overt infiltrative disease was noted. No associated abnormal lymphatic activity was noted.

Pancreas

The base and limbs of the **pancreas** were observed to be largely isoechoic to surrounding omental fat. Some parenchymal remodeling, however, with mild deviation from curvilinear normalcy was observed. Pancreatic duct and capsular irregularities were present consistent with age related changes. If pain upon imaging (+ Murphy sign) was present or if the patient is focally painful in subxyphoid palpation then low-grade smoldering chronic pancreatitis should be suspected.

ULTRASONOGRAPHIC FINDINGS

- Hepatic remodeling
- Age related renal changes



PATIENT

Cali Maxwell

INTERPRETATION OF THE FINDINGS & FURTHER RECOMMENDATIONS

No evidence of significant disease. Possibility of low-grade pancreatitis, yet changes were minor. Supportive care should prove effective.

SPECIES

Canine

BREED

Golden Retriever

SEX

Spayed Female

AGE

13.5 Pounds

WEIGHT

31.8 kg

INTERPRETED BY

Eric Lindquist, DMV

DABVP, Cert. IVUSS

IMAGING PERFORMED BY

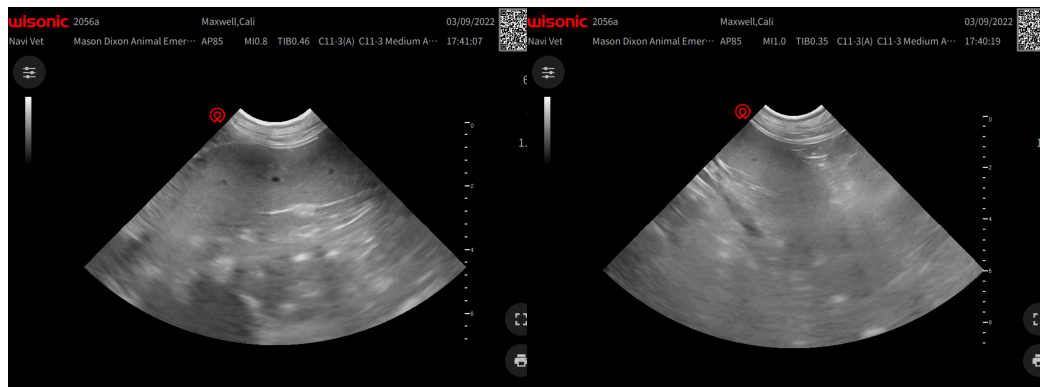
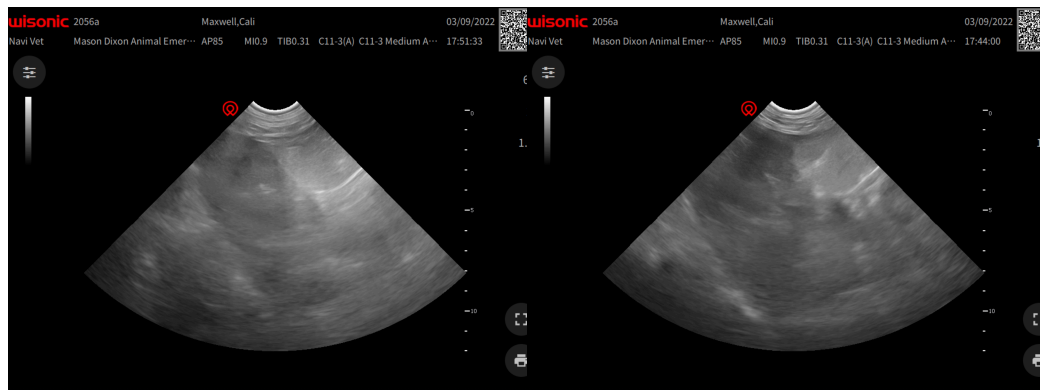
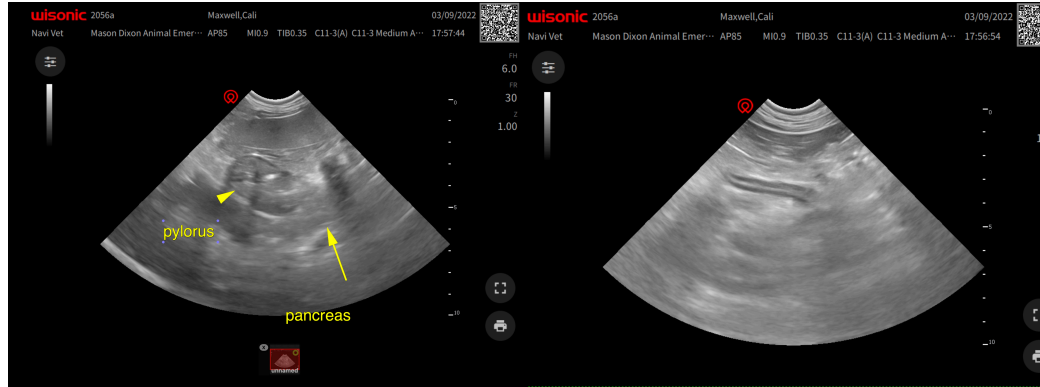
Dr. Laura De Cordon

HOSPITAL NAME

Mason Dixon Animal Emergency Hospital

REFERRING VET

Dr. Laura De Cordon



INVOICE

36002

DATE

3/9/22



PATIENT

Cali Maxwell

SPECIES

Canine

BREED

Golden Retriever

SEX

Spayed Female

AGE

13.5 Pounds

WEIGHT

31.8 kg

INTERPRETED BY

Eric Lindquist, DMV

DABVP, Cert. IVUSS

IMAGING PERFORMED BY

Dr. Laura De Cordon

HOSPITAL NAME

Mason Dixon Animal Emergency Hospital

REFERRING VET

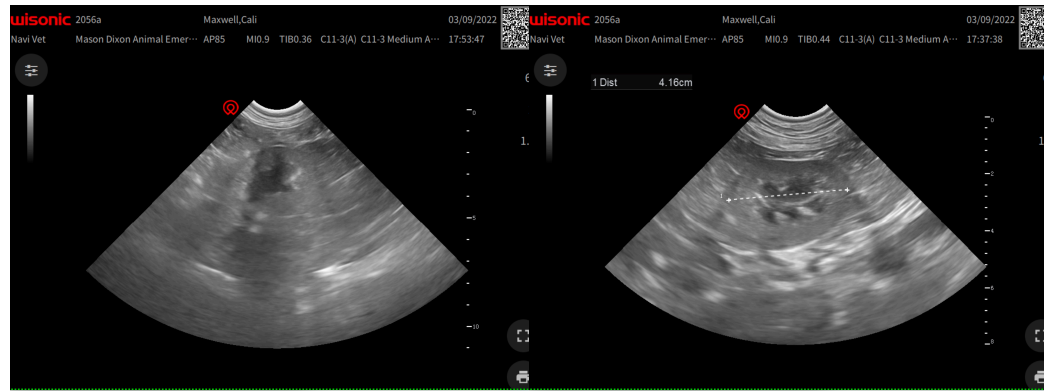
Dr. Laura De Cordon

INVOICE

36002

DATE

3/9/22



The information and recommendations provided are based on the images presented by the referring veterinarian/sonographer. No evaluation can be communicated regarding pathology that was not visible in the image/video clips provided.

Thank you for this referral. If the clinical or image interpretation does not parallel your findings or if I can be of any further assistance please contact me.

Eric Lindquist, DMV, DABVP, Cert. IVUSS, CEO of SonoPath.com

info@SonoPath.com