



PATIENT PRESENTING CLINICAL SIGNS

Bella Preete History: Ultrasound for neighbouring clinic. Lameness in Jan, started on metacam, presented in March for bloodwork and was mildly anemic with elevated BUN. Cranial abdomen felt full on exam
Abnormal PE/Chem/CBC/UA Results: mm sl pale, CRT <2sec. CBC-significant findings: RBC 3,75 10⁶/mm³ L 5.50 8.50 HGB 9,80 g/dL L 12.00 18.00 HCT 26,70 % L 37.00 55.00 Chem- BUN- 11,21 mmol/l H 3.21 10.35, creat and remainder of chem normal

SPECIES

Canine

BREED

Labrador

SEX

Spayed Female

AGE

11 years

WEIGHT

31 kg

ULTRASONOGRAPHIC EXAMINATION OF THE ABDOMEN

Urinary System

The **urinary bladder**, trigone, and pelvic urethra presented normal thicknesses and normal tone. The pelvic urethra was imaged 2.0 cm beyond the cystourethral junction. The ureters were not visible which is normal. No uroliths or sediment were visualized and anechoic urine was present. No evidence of inflammatory or neoplastic changes was noted. Ureteral papillae were normal.

The uterine stump was unremarkable. The stump measured 0.5 cm.

The **kidneys** revealed normal size and structure, corticomedullary definition and ratio for this age. The cortices presented largely uniform texture with normal echogenic relationship to liver and spleen. Medullary structure differed distinctly from the cortex and no evidence of pelvic dilation was present. The capsules were acceptably uniform without significant irregularities. The right kidney measured 6.0 cm.

Adrenal Glands

Both **adrenal glands** were visualized and recognized as having normal shape, size, position and echogenicity for this breed. The phrenic vasculature, glandular echogenicity and detail were unremarkable. Capsule, cortex, and medullary definition were normal for this age patient. The left adrenal gland measured 0.34 cm. The right adrenal gland measured 0.5 cm.

INTERPRETED BY

Eric Lindquist, DMV DABVP, Cert. IVUSS

IMAGING PERFORMED BY

Dr. Biederbeck

HOSPITAL NAME

Lomsnes VH

REFERRING VET

Dr. Biederbeck

Spleen

The **spleen** presented a smooth homogeneous parenchyma hyperechoic to liver and renal cortical parenchyma. The capsule was smooth without noticeable expansion or deviation from within the spleen or adjacent pathology. The splenic vasculature demonstrated normal volume without signs of congestion or thrombosis. No sonographic evidence of acute or chronic inflammatory, neoplastic, or infarctual changes was noted.

Liver

The **liver** images submitted revealed subjectively normal liver size, contour, and structure. Parenchymal echogenicity was naturally coarse and hypoechoic to the spleen. Vascular and biliary tracts were of normal volume with no evidence of congestion. The gallbladder presented acceptably thin walls with primarily anechoic content. The cystic and common bile ducts were normal. No pathological hepatic lymphadenopathy was evident. No overt structural evidence of inflammatory, infiltrative or regenerative pathology was evident.

INVOICE

96734

DATE

3/9/22



PATIENT

Gastrointestinal

Bella Preete

Examination of the **gastrointestinal tract** revealed a stomach and intestine free of stasis, of normal wall thickness, acceptable curvilinear mural detail, and peristaltic activity. Small and large intestine demonstrated normal luminal chyme and stool consistency respectively. No obstructive or overt infiltrative disease was noted. No associated abnormal lymphatic activity was noted.

SPECIES

Canine

BREED

Labrador

Pancreas

The base and limbs of the **pancreas** were observed to be largely isoechoic to surrounding omental fat. Pancreatic duct and capsular contour were acceptably normal and parenchyma respected normal curvilinear patterns. No overt evidence of active inflammatory or neoplastic disease was noted.

SEX

Spayed Female

ULTRASONOGRAPHIC FINDINGS

Structurally unremarkable abdomen.

AGE

11 years

INTERPRETATION OF THE FINDINGS & FURTHER RECOMMENDATIONS

WEIGHT

31 kg

I cannot rule out a gastrointestinal hemorrhage in this patient even though structurally the GI tract appears unremarkable. CBC path review +/- bone marrow aspirate would be appropriate. GI protectant protocol is warranted such as the following. There was no evidence of neoplasia. Any NSAID therapy should be stopped until the presentation resolves.

INTERPRETED BY

Eric Lindquist, DMV
DABVP, Cert. IVUSS

Helicobacter/Gastritis protocol

A clinical trial of **Zithromax (Dogs: 5-10 mg/kg p.o. q24h. May increase dosing interval to q48h after 3-5 days of treatment)**, **Metronidazole (10-20 mg/kg p.o. b.i.d.)**, **Sucralfate (0.5-2 g/dog PO)** and **Omeprazole (1 mg/kg p.o. s.i.d.)** over the next 3 weeks along with a **novel-protein or hydrolyzed diet** with slurry feeding b.i.d./t.i.d. over the next 2-4 days and then increase to canned diet bid. Dry food should be avoided over the next 4 weeks. A recheck sonogram to assess GI improvement or progression would be ideal in 4 weeks.

IMAGING PERFORMED BY

Dr. Biederbeck

HOSPITAL NAME

Lomsnes VH

REFERRING VET

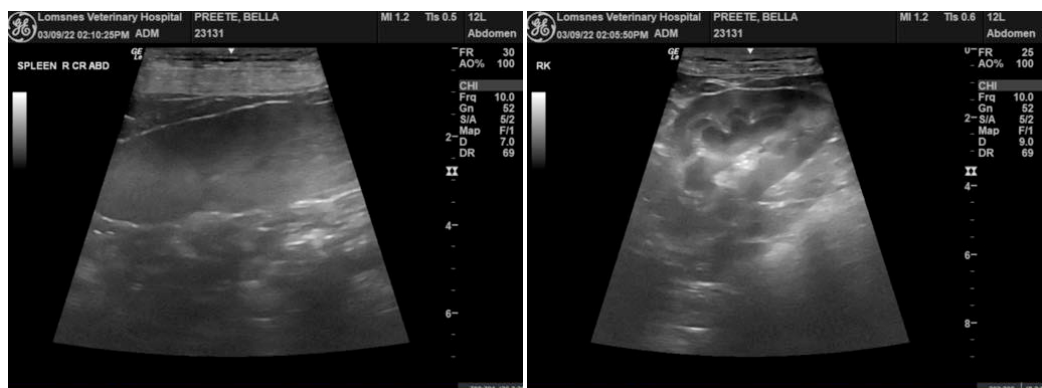
Dr. Biederbeck

INVOICE

96734

DATE

3/9/22





PATIENT

Bella Preete

SPECIES

Canine

BREED

Labrador

SEX

Spayed Female

AGE

11 years

WEIGHT

31 kg

INTERPRETED BY

Eric Lindquist, DMV
DABVP, Cert. IVUSS

IMAGING PERFORMED BY

Dr. Biederbeck

HOSPITAL NAME

Lomsnes VH

REFERRING VET

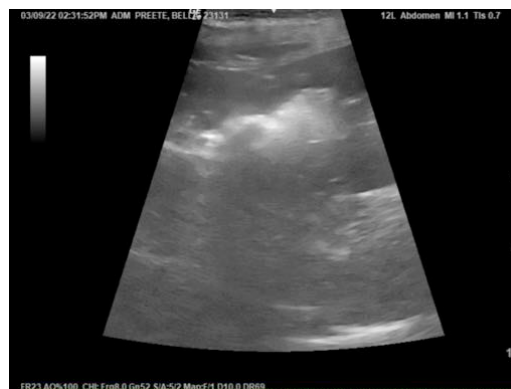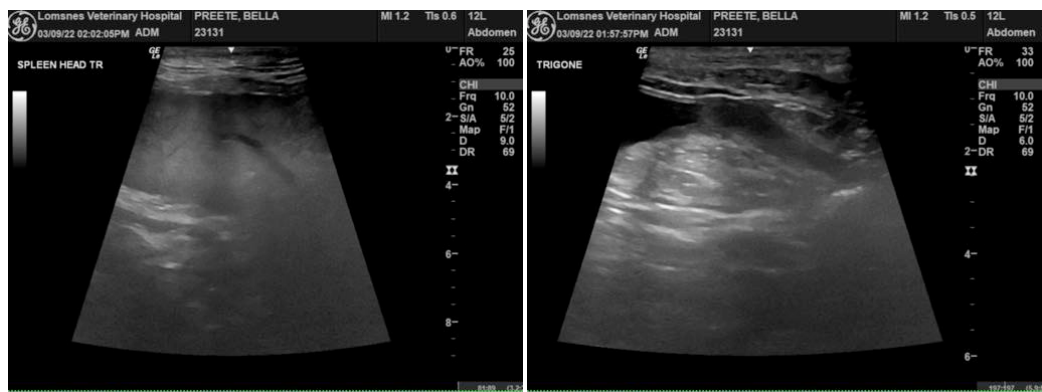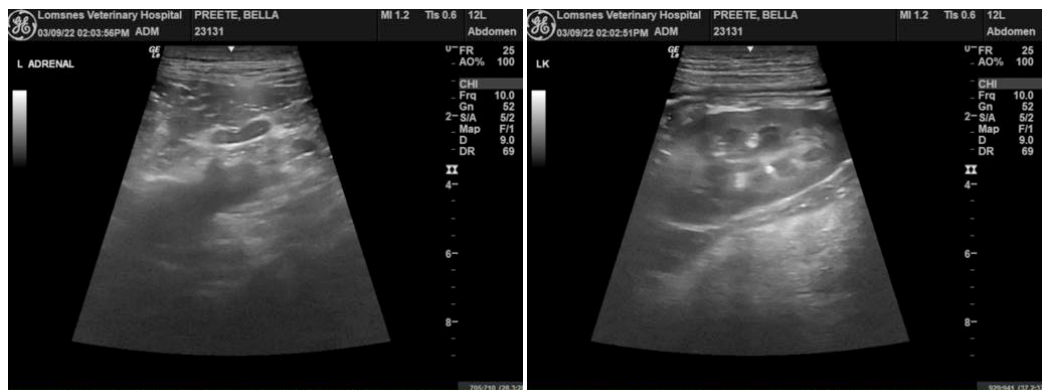
Dr. Biederbeck

INVOICE

96734

DATE

3/9/22



The information and recommendations provided are based on the images presented by the referring veterinarian/sonographer. No evaluation can be communicated regarding pathology that was not visible in the image/video clips provided.

Thank you for this referral. If the clinical or image interpretation does not parallel your findings or if I can be of any further assistance please contact me.

Eric Lindquist, DMV, DABVP, Cert. IVUSS, CEO of SonoPath.com



PATIENT

info@SonoPath.com

Bella Preete

SPECIES

Canine

BREED

Labrador

SEX

Spayed Female

AGE

11 years

WEIGHT

31 kg

INTERPRETED BY

Eric Lindquist, DMV
DABVP, Cert. IVUSS

**IMAGING
PERFORMED BY**

Dr. Biederbeck

HOSPITAL NAME

Lomsnes VH

REFERRING VET

Dr. Biederbeck

INVOICE

96734

DATE

3/9/22