


PATIENT

Watson Woods

SPECIES

Canine

BREED

Chihuahua Cross

SEX

Spayed female

AGE

11 years

WEIGHT

15.4 lbs

INTERPRETED BY

 Eric Lindquist, DMV
 DABVP, Cert. IVUSS

IMAGING PERFORMED BY

Dr. Gunther

HOSPITAL NAME

New Frontier AMC

REFERRING VET

Dr. Gunther

INVOICE

43200

DATE

3/8/23

PRESENTING CLINICAL SIGNS

 History: Hx of MMVD (B2 in Jan 2022, had Echo) Diagnosed with CHF in Feb 2023, started Furosemide (based on radiographs) Meds: Vetmedin Enalapril Furosemide
 Abnormal PE/Chem/CBC/UA Results: CHEM unremarkable normotensive

ULTRASONOGRAPHIC EXAMINATION OF THE HEART

The echocardiogram in this patient revealed persistent valvular disease with insufficiency of the mitral and tricuspid valve, yet the volumes were contained. Contractility was adequate and there was no pericardial or pleural effusion. The hepatic veins were not dilated.

	CANINE	MR	TR	LA/AO	LA/AO	FS	EF	EPSS
CARDIAC PARAMETERS		VMAX (m/s)	VMAX (m/s)	(Boon method)	(Heart Base;)	(%)	(%)	(cm)
NORMAL PARAMETER		4.5-5.5	<2.7	1.3	<1.6	28-40	40-100	<0.6
PATIENT		5.5		1.3	1.7	42	76	0.23
	CANINE	HR	AV	PV	BODY WEIGHT	LA	LVIDd	LVIDs
CARDIAC PARAMETERS		(BPM)	VMAX (m/s)	MAX (m/s)		2D short axis Base view (cm)	Avg; 2D and m-mode short axis (cm)	Avg; 2D and m-mode short axis (cm)
NORMAL PARAMETER		50-100	0.7-1.7	0.7-1.6	BELOW	BELOW	BELOW	BELOW
PATIENT				1.1	15.4 lbs	2.4 max	2.1	

ULTRASONOGRAPHIC FINDINGS

Compensated mitral insufficiency on the current protocol.

INTERPRETATION OF THE FINDINGS & FURTHER RECOMMENDATIONS

I recommend to continue the current protocol with a recheck echocardiogram in 6 months or earlier if murmur grade increases or clinical signs initiate.



PATIENT

Watson Woods

SPECIES

Canine

BREED

Chihuahua Cross

SEX

Spayed female

AGE

11 years

WEIGHT

15.4 lbs

INTERPRETED BY

Eric Lindquist, DMV
DABVP, Cert. IVUSS

IMAGING PERFORMED BY

Dr. Gunther

HOSPITAL NAME

New Frontier AMC

REFERRING VET

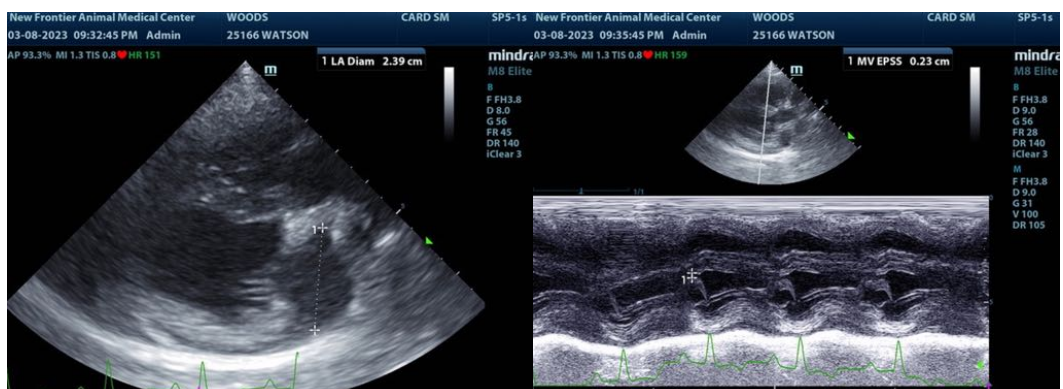
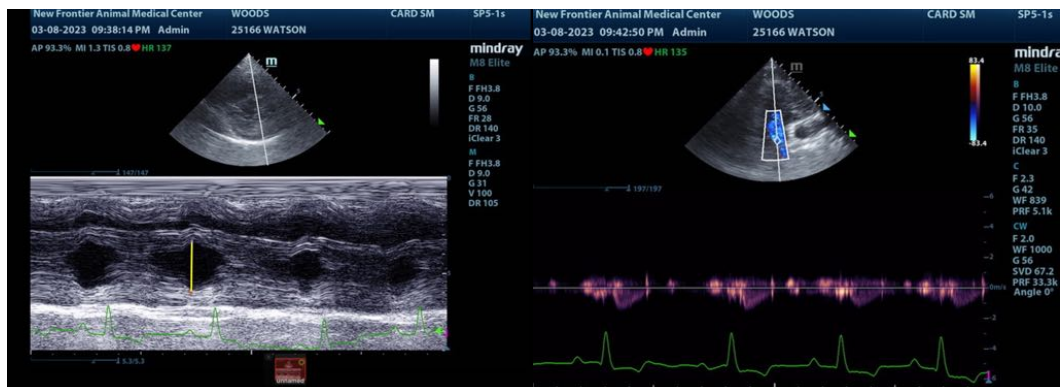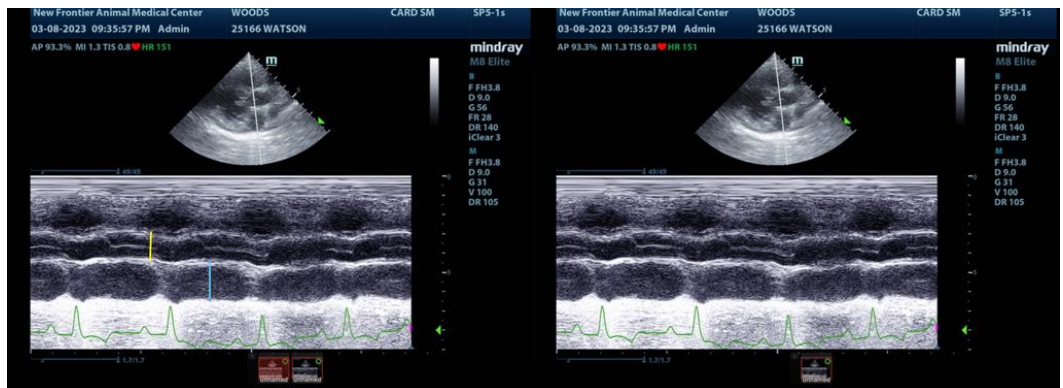
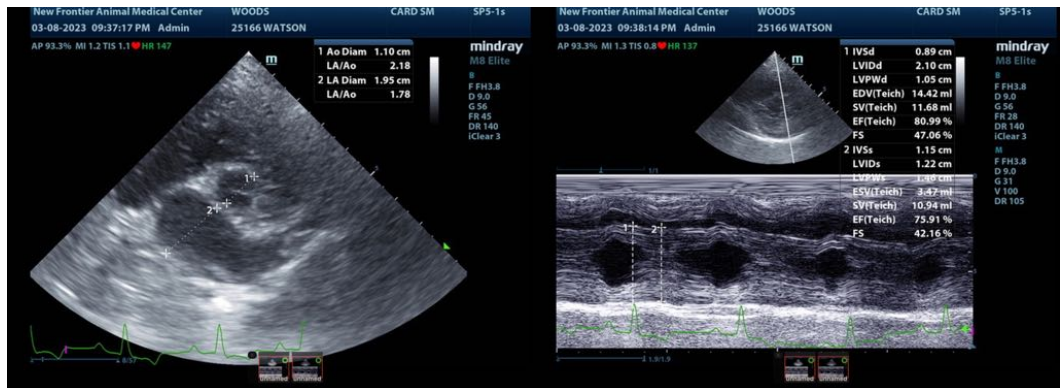
Dr. Gunther

INVOICE

43200

DATE

3/8/23





PATIENT

Watson Woods

SPECIES

Canine

BREED

Chihuahua Cross

SEX

Spayed female

AGE

11 years

WEIGHT

15.4 lbs

INTERPRETED BY

Eric Lindquist, DMV
DABVP, Cert. IVUSS

**IMAGING
PERFORMED BY**

Dr. Gunther

HOSPITAL NAME

New Frontier AMC

REFERRING VET

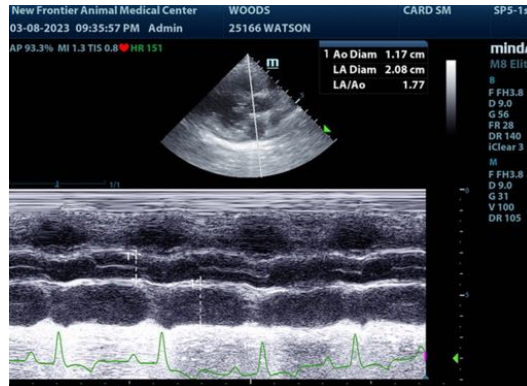
Dr. Gunther

INVOICE

43200

DATE

3/8/23



The information and recommendations provided are based on the images presented by the referring veterinarian/sonographer. No evaluation can be communicated regarding pathology that was not visible in the image/video clips provided.

Thank you for this referral. If the clinical or image interpretation does not parallel your findings or if I can be of any further assistance please contact me.

Eric Lindquist, DMV, DABVP, Cert. IVUSS, CEO of SonoPath.com
info@SonoPath.com