



PATIENT PRESENTING CLINICAL SIGNS

Buckley Caponegro

History: recheck prev u/s yesterday showed ingsta within the gastric lumen -delayed gastric emptying even though patient was fasted

SPECIES

Canine

ULTRASONOGRAPHIC EXAMINATION OF THE ABDOMEN

Gastrointestinal

BREED

Poodle Mix

The upper **gastrointestinal tract** was empty in this patient. There was no evidence of retention of ingesta or foreign body. The colon revealed normal stool.

The pancreas and regional structures were unremarkable.

SEX

Neutered male

ULTRASONOGRAPHIC FINDINGS

Resolved GI presentation.

AGE

6 years

INTERPRETATION OF THE FINDINGS & FURTHER RECOMMENDATIONS

WEIGHT

30 lbs

There was no evidence of foreign body or further delayed outflow. The upper gastrointestinal tract was empty.

INTERPRETED BY

Eric Lindquist, DMV
DABVP, Cert. IVUS

IMAGING PERFORMED BY

Jenn

HOSPITAL NAME

Rockaway AH

REFERRING VET

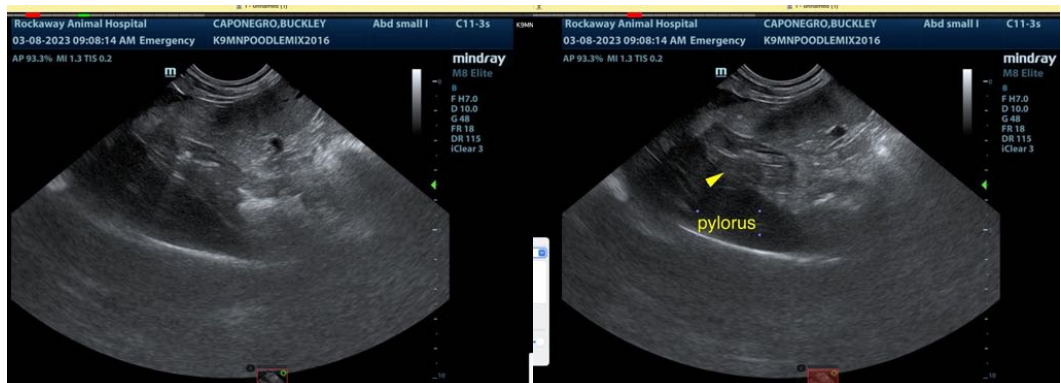
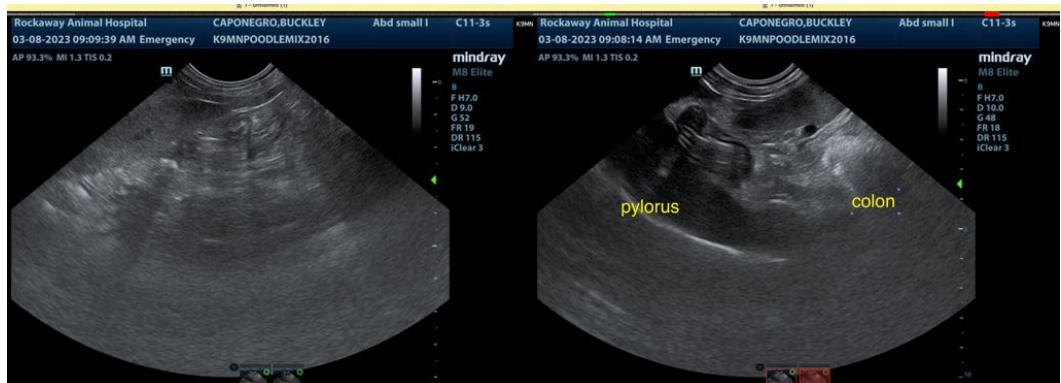
Dr. Maniar

INVOICE

43156

DATE

3/8/23





PATIENT

Buckley Caponegro

SPECIES

Canine

BREED

Poodle Mix

SEX

Neutered male

AGE

6 years

WEIGHT

30 lbs

INTERPRETED BY

Eric Lindquist, DMV
DABVP, Cert. IVUSS

IMAGING PERFORMED BY

Jenn

HOSPITAL NAME

Rockaway AH

REFERRING VET

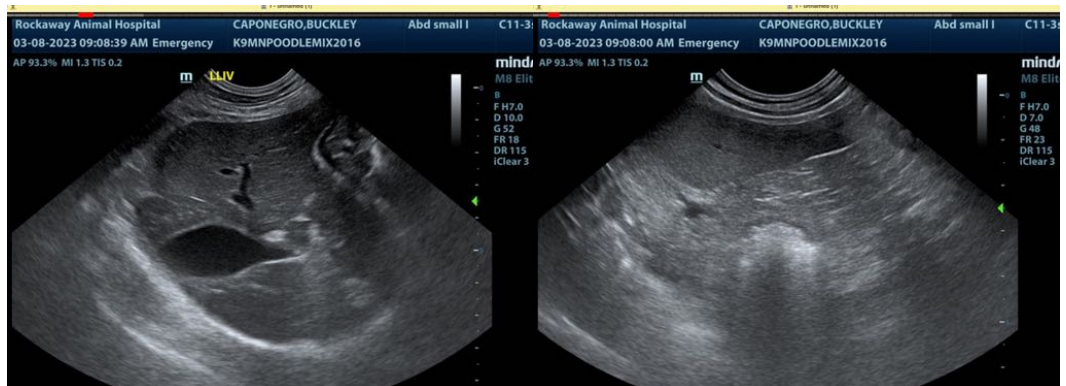
Dr. Maniar

INVOICE

43156

DATE

3/8/23



The information and recommendations provided are based on the images presented by the referring veterinarian/sonographer. No evaluation can be communicated regarding pathology that was not visible in the image/video clips provided.

Thank you for this referral. If the clinical or image interpretation does not parallel your findings or if I can be of any further assistance please contact me.

Eric Lindquist, DMV, DABVP, Cert. IVUSS, CEO of SonoPath.com
info@SonoPath.com