

PATIENT

Olivia Gray

SPECIES

Canine

BREED

Sheepadoodle

SEX

Spayed Female

AGE

1 Years

WEIGHT

53 Pounds

INTERPRETED BY

Eric Lindquist, DMV

DABVP, Cert. IVUSS

IMAGING PERFORMED BY

Dr. Mayra Sanchez

HOSPITAL NAME

Sunset AH

REFERRING VET

Dr. Mayra Sanchez

INVOICE

36015

DATE

3/8/22

PRESENTING CLINICAL SIGNS

History of Clostridium Perfringens and chronic diarrhea Patient now has normal stool but began vomiting No FB ingestion per owner

Abnormal PE/Chem/CBC/UA Results: CBC/chem = NSF Fecal scan = NPS Radiographs = Gas-filled SI

ULTRASONOGRAPHIC EXAMINATION OF THE ABDOMEN

Urinary System

The **urinary bladder**, trigone, and pelvic urethra presented normal thicknesses and normal tone. The ureters were not visible which is normal. No uroliths or sediment were visualized and anechoic urine was present. No evidence of inflammatory or neoplastic changes were noted. Ureteral papillae were normal. The pelvic urethra was imaged 1.0 cm beyond the cystourethral junction.

The **kidneys** revealed normal size and structure, corticomedullary definition and ratio for this age. The cortices presented largely uniform texture with normal echogenic relationship to liver and spleen. Medullary structure differed distinctly from the cortex and no evidence of pelvic dilation was present. The capsules were acceptably uniform without significant irregularities. The left kidney measured 6.0 cm. The right kidney measured 6.0 cm.

Adrenal Glands

Both **adrenal glands** were visualized and recognized as having normal shape, size, position and echogenicity for this breed. The phrenic vasculature, glandular echogenicity and detail were unremarkable. Capsule, cortex, and medullary definition were normal for this age patient. The left adrenal gland measured 0.40 cm. The right adrenal gland measured 0.80 cm.

Spleen

The **spleen** was slightly enlarged, uniform, with midl granular appearance.

Liver

The **liver** images submitted revealed subjectively normal liver size, contour, and structure. Parenchymal echogenicity was naturally coarse and hypoechoic to the spleen. Vascular and biliary tracts were of normal volume with no evidence of congestion. The gallbladder presented acceptably thin walls with primarily anechoic content. The cystic and common bile ducts were normal. No pathological hepatic lymphadenopathy was evident. No overt structural evidence of inflammatory, infiltrative or regenerative pathology was evident.

Gastrointestinal

Examination of the **gastrointestinal tract** revealed a stomach and intestine free of stasis, of normal wall thickness, acceptable curvilinear mural detail, and peristaltic activity. Small and large intestine demonstrated normal luminal chyme and stool consistency respectively. No obstructive or overt infiltrative disease was noted. No associated abnormal lymphatic activity was noted.

Pancreas

The base and limbs of the **pancreas** were observed to be largely isoechoic to surrounding omental fat. Pancreatic duct and capsular contour were acceptably normal and parenchyma respected normal curvilinear patterns. No overt evidence of active inflammatory or neoplastic disease was noted.



PATIENT

Olivia Gray

ULTRASONOGRAPHIC FINDINGS

- Reactive spleen, unremarkable abdomen otherwise

SPECIES

Canine

INTERPRETATION OF THE FINDINGS & FURTHER RECOMMENDATIONS

Screening for occult Addison's warranted to ensure this is not an underlying issue. If weight loss is an issue, then splenic FNA would be indicated.

BREED

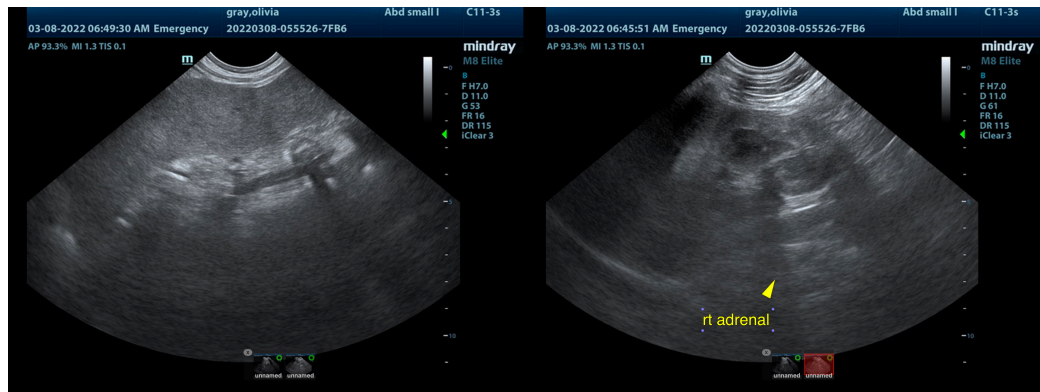
Sheepadoodle

SEX

Spayed Female

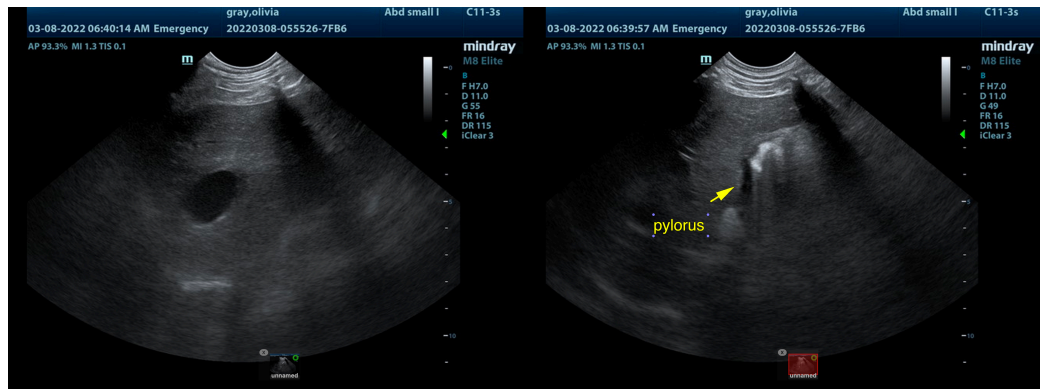
AGE

1 Years



WEIGHT

53 Pounds



INTERPRETED BY

Eric Lindquist, DMV
DABVP, Cert. IVUSS

IMAGING PERFORMED BY

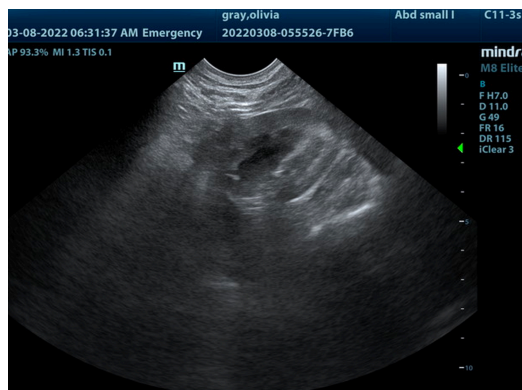
Dr. Mayra Sanchez

HOSPITAL NAME

Sunset AH

REFERRING VET

Dr. Mayra Sanchez



INVOICE

36015

DATE

3/8/22



PATIENT

Olivia Gray

The information and recommendations provided are based on the images presented by the referring veterinarian/sonographer. No evaluation can be communicated regarding pathology that was not visible in the image/video clips provided.

SPECIES

Canine

Thank you for this referral. If the clinical or image interpretation does not parallel your findings or if I can be of any further assistance please contact me.

Eric Lindquist, DMV, DABVP, Cert. IVUSS, CEO of SonoPath.com

info@SonoPath.com

BREED

Sheepadoodle

SEX

Spayed Female

AGE

1 Years

WEIGHT

53 Pounds

INTERPRETED BY

Eric Lindquist, DMV

DABVP, Cert. IVUSS

IMAGING PERFORMED BY

Dr. Mayra Sanchez

HOSPITAL NAME

Sunset AH

REFERRING VET

Dr. Mayra Sanchez

INVOICE

36015

DATE

3/8/22