



**PATIENT**

Lola Capobianco

**SPECIES**

Canine

**BREED**

Terrier X

**SEX**

Spayed Female

**AGE**

13.5 Years

**WEIGHT**

41.7 Pounds

**INTERPRETED BY**

Eric Lindquist, DMV

DABVP, Cert. IVUSS

**IMAGING PERFORMED BY**

Dr. Giuliani

**HOSPITAL NAME**

The Pet Hospital of Stratford

**REFERRING VET**

Dr. Giuliani

**INVOICE**

36011

**DATE**

3/8/22

**PRESENTING CLINICAL SIGNS**

Pt presented for possible UTI. O noted a couple weeks ago that pt was urinating more frequently outside, and this past week, pt has been having accidents in the house frequently and straining for minutes with only going a couple drops. Pt e/d/d normally, no v/d/c/s. BW/UA w/ cysto urine collection: wnl, no bacteria or wbc seen in urine, culture pending.

**ULTRASONOGRAPHIC EXAMINATION OF THE ABDOMEN**

**Urinary System**

The **urinary bladder** was significantly distended at the time of the sonogram. Suspended debris present. The pelvic urethra was not visualized.

The **kidneys** revealed largely normal size and structure, corticomedullary definition and ratio (cortex 1/3 of medulla) were essentially maintained with some age-related loss of curvilinear patterns regarding the capsule and C/M junction. The cortices presented largely uniform texture with some increased echogenicity expected for his age patient. Medullary structure differed distinctly from that of the cortex and no evidence of pelvic dilation was present. The left kidney measured 5.0 cm. Blood flow appeared adequate on color flow assessment.

**Adrenal Glands**

The **left adrenal gland** was visualized and recognized as having normal shape, size, position and echogenicity for this breed. The phrenic vasculature, glandular echogenicity and detail were unremarkable. Capsule, cortex, and medullary definition were normal for this age patient. The left adrenal gland measured 0.3 cm.

The **right adrenal gland** was not visualized.

**Spleen**

The **spleen** presented a smooth homogeneous parenchyma hyperechoic to liver and renal cortical parenchyma. The capsule was smooth without noticeable expansion or deviation from within the spleen or adjacent pathology. The splenic vasculature demonstrated normal volume without signs of congestion or thrombosis. No sonographic evidence of acute or chronic inflammatory, neoplastic, or infarctual changes were noted.

**Liver**

The **liver** images submitted revealed subjectively normal liver size, contour, and structure. Parenchymal echogenicity was naturally coarse and hypoechoic to the spleen. Vascular and biliary tracts were of normal volume with no evidence of congestion. The gallbladder presented acceptably thin walls with primarily anechoic content. The cystic and common bile ducts were normal. No pathological hepatic lymphadenopathy was evident. No overt structural evidence of inflammatory, infiltrative or regenerative pathology was evident.

**Gastrointestinal**

Examination of the **gastrointestinal tract** revealed a stomach and intestine free of stasis, of normal wall thickness, acceptable curvilinear mural detail, and peristaltic activity. Small and large intestine demonstrated normal luminal chyme and stool consistency respectively. No obstructive or overt infiltrative disease was noted. No associated abnormal lymphatic activity was noted.



**PATIENT**

Lola Capobianco

**SPECIES**

Canine

**BREED**

Terrier X

**SEX**

Spayed Female

**AGE**

13.5 Years

**WEIGHT**

41.7 Pounds

**INTERPRETED BY**

Eric Lindquist, DMV

DABVP, Cert. IVUSS

**IMAGING PERFORMED BY**

Dr. Giuliani

**HOSPITAL NAME**

The Pet Hospital of Stratford

**REFERRING VET**

Dr. Giuliani

**INVOICE**

36011

**DATE**

3/8/22

**Pancreas**

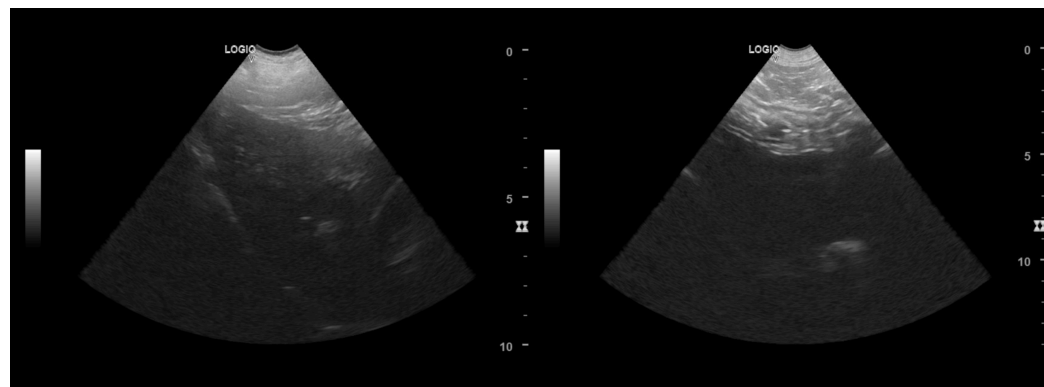
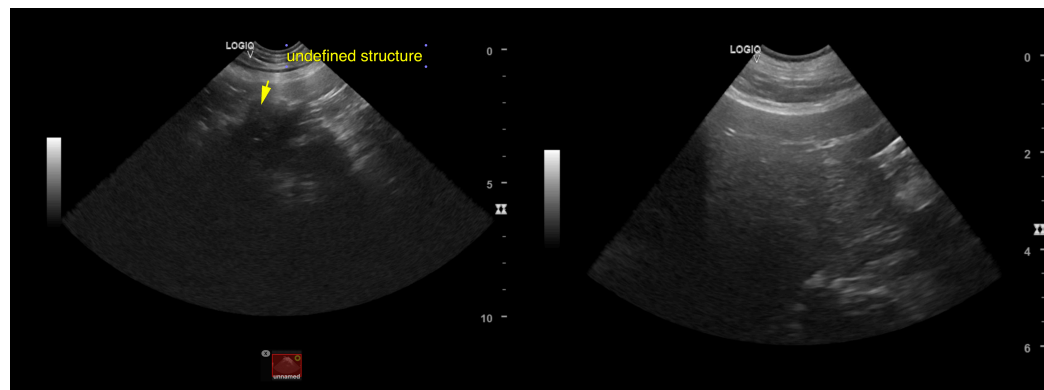
The base and limbs of the **pancreas** were observed to be largely isoechoic to surrounding omental fat. Pancreatic duct and capsular contour were acceptably normal and parenchyma respected normal curvilinear patterns. No overt evidence of active inflammatory or neoplastic disease was noted.

**ULTRASONOGRAPHIC FINDINGS**

- Overdistended bladder with excessive debris
- Age related abdominal changes with undefined structure

**INTERPRETATION OF THE FINDINGS & FURTHER RECOMMENDATIONS**

Imaging of the deep pelvic urethra indicated in this patient or cystoscopy, given the patient history, as there is concern for urethral pathology. Video #11 showed an approximately 2.0 cm hypoechoic, ill-defined structure. The exact location of this structure is unclear. It is suspected to be an iliac lymph node or possible adrenal, yet further imaging would be necessary of the right adrenal gland and pelvic urethra. Deep urethral pathology such as tumor is a strong potential in this patient. However, cystoscopy or further ultrasound imaging necessary.





**PATIENT**

Lola Capobianco

**SPECIES**

Canine

**BREED**

Terrier X

**SEX**

Spayed Female

**AGE**

13.5 Years

**WEIGHT**

41.7 Pounds

**INTERPRETED BY**

Eric Lindquist, DMV

DABVP, Cert. IVUSS

**IMAGING PERFORMED BY**

Dr. Giuliani

**HOSPITAL NAME**

The Pet Hospital of  
Stratford

**REFERRING VET**

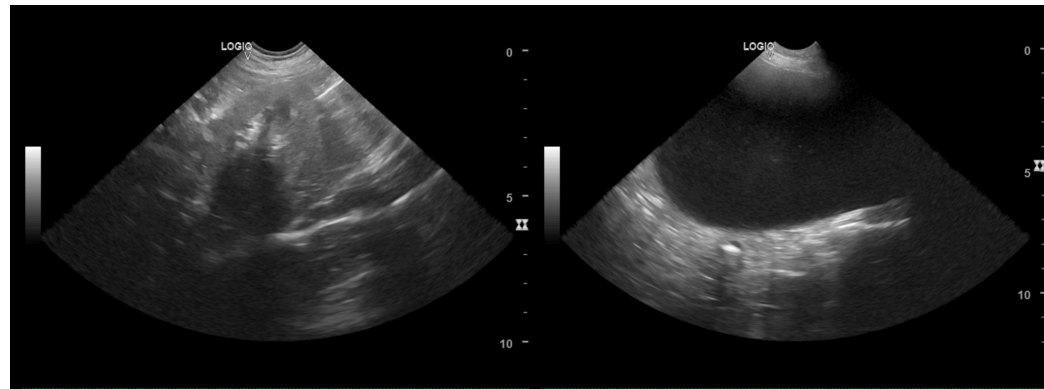
Dr. Giuliani

**INVOICE**

36011

**DATE**

3/8/22



The information and recommendations provided are based on the images presented by the referring veterinarian/sonographer. No evaluation can be communicated regarding pathology that was not visible in the image/video clips provided.

Thank you for this referral. If the clinical or image interpretation does not parallel your findings or if I can be of any further assistance please contact me.

Eric Lindquist, DMV, DABVP, Cert. IVUSS, CEO of SonoPath.com

[info@SonoPath.com](mailto:info@SonoPath.com)