

PATIENT

Jessie Murphy

SPECIES

Feline

BREED

Domestic Shorthair

SEX

Neutered male

AGE

9 years

WEIGHT

13.7 lbs

INTERPRETED BY

Eric Lindquist, DMV
DABVP, Cert. IVUSS

IMAGING PERFORMED BY

Shari Reffi, CVT

HOSPITAL NAME

Newton Vet

REFERRING VET

Dr. Verhalen

PRESENTING CLINICAL SIGNS

History: Chronic vomiting. Rads revealed splenomegaly and possible cardiomegaly. Current meds: Gabapentin for mild sedation. No other meds.
Abnormal PE/Chem/CBC/UA Results: NSF

ULTRASONOGRAPHIC EXAMINATION OF THE HEART

The echocardiogram in this patient demonstrated normal **left atrial** size based on 3 separate LA measurements. The cranial and caudal **mitral** valve leaflets presented normal linear structure and kinetics. The **left ventricle** presented normal thicknesses with linear contour and was not dilated nor restricted. The **myocardium** presented normal echogenicity without subjective evidence of significant fibrotic or ischemic disease. **Contractility** of the ventricular walls was adequate and in normal range for this patient evidenced by the fractional shortening measurement and subjective evaluation of the different regions and angles of the myocardium. The **left ventricular outflow** tract demonstrated normal laminar flow and subjective structural integrity. The **right atrium** and auricle revealed normal size, structure and content. No evidence of masses was noted or chamber overload. **Tricuspid** valvular assessment demonstrated adequate linear morphology and kinetics. The **right ventricle** was of normal size (1/3 diameter of LV), chordae structure, myocardial echogenicity and thickness. **Pulmonic** tract assessment revealed normal valve structure, laminar flow, and diameter (approx. 1:1 pa/ao ratio). No visible **pericardial** or free pleura fluid was noted or extra cardiac pathology in the visible planes. The cranial **mediastinum** and **pericardial** regions were free of masses in the visible window.

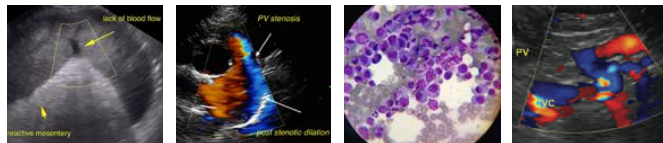
FELINE CARDIAC PARAMETERS	BODY WEIGHT (kg)	HR (BPM)	IVSd (cm)	LVIDd (cm)	LVWd (cm)	FS (%)	EF (%)
NORMAL PARAMETER	-----	150-240	0.3-0.6	1.0-2.1	0.25-0.6	35-67	80-100
PATIENT		224	0.54	1.5	0.52	37	72
FELINE CARDIAC PARAMETERS	LA/AO (Boon)	LA/AO HEART BASE (Sisson)	LA 2D 4-chamber long axis AS to FW (Sisson) (cm)	LVOT VEL. (m/s)	RVOT VEL. (m/s)	IVRT (m/)	
NORMAL PARAMETER	<1.5	0.88-1.79	0.7-1.7	<1.6	<1.3	40-60	
PATIENT	1.15	1.17		1.1	0.61	NM	
Adapted from June Boon, Veterinary Echocardiography, 1998 Sisson D et al. JVIM 1991; 5: 232, Jacobs et al. Am J Vet Res 1985; 46:1705							

INVOICE

96645

DATE

3/8/22



PATIENT

ULTRASONOGRAPHIC EXAMINATION OF THE ABDOMEN

Jessie Murphy

Urinary System

SPECIES

The **urinary bladder**, trigone, and pelvic urethra presented normal thicknesses and normal tone. The ureters were not visible which is normal. No uroliths or sediment were visualized and anechoic urine was present. No evidence of inflammatory or neoplastic changes was noted. Ureteral papillae were normal.

Feline

BREED

The **kidneys** revealed largely normal size and structure, corticomedullary definition and ratio (cortex 1/3 of medulla) were essentially maintained with some age-related loss of curvilinear patterns regarding the capsule and C/M junction. The cortices presented largely uniform texture with some increased echogenicity expected for this age patient. Medullary structure differed distinctly from that of the cortex and no evidence of pelvic dilation was present. The right kidney measured 4.6 cm. The left kidney measured 4.3 cm.

Domestic Shorthair

SEX

Neutered male

AGE

9 years

Adrenal Glands

Both **adrenal glands** were visualized and recognized as having normal shape, size, position and echogenicity for this breed. The phrenic vasculature, glandular echogenicity and detail were unremarkable. Capsule, cortex, and medullary definition were normal for this age patient. The left adrenal gland measured 0.41 cm.

WEIGHT

13.7 lbs

INTERPRETED BY

Spleen

Eric Lindquist, DMV
DABVP, Cert. IVUSS

The **spleen** was enlarged with an isoechoic 2.1 cm mass and 1.9 cm wide body of the parenchyma.

IMAGING PERFORMED BY

Liver

Shari Reffi, CVT

The **liver** images submitted revealed subjectively normal liver size, contour, and structure. Parenchymal echogenicity was naturally coarse and hypoechoic to the spleen. Vascular and biliary tracts were of normal volume with no evidence of congestion. The gallbladder presented acceptably thin walls with primarily anechoic content. The cystic and common bile ducts were normal. No pathological hepatic lymphadenopathy was evident. No overt structural evidence of inflammatory, infiltrative or regenerative pathology was evident.

HOSPITAL NAME

Newton Vet

REFERRING VET

Dr. Verhalen

Gastrointestinal

INVOICE

Examination of the **gastrointestinal tract** revealed a stomach and intestine free of stasis, of normal wall thickness, acceptable curvilinear mural detail, and peristaltic activity. Small and large intestine demonstrated normal luminal chyme and stool consistency respectively. No obstructive or overt infiltrative disease was noted. No associated abnormal lymphatic activity was noted.

96645

DATE

3/8/22



PATIENT

Pancreas

Jessie Murphy

The base and limbs of the **pancreas** were observed to be largely isoechoic to surrounding omental fat. Pancreatic duct and capsular contour were acceptably normal and parenchyma respected normal curvilinear patterns. No overt evidence of active inflammatory or neoplastic disease was noted.

SPECIES

Feline

ULTRASONOGRAPHIC FINDINGS

BREED

Normal echocardiogram.

Domestic Shorthair

Splenic infiltrative pattern with mass.

Age related renal changes.

SEX

Neutered male

INTERPRETATION OF THE FINDINGS & FURTHER RECOMMENDATIONS

AGE

9 years

There was no obvious metastatic disease noted. Round cell neoplasia is suspected of the spleen with a possibility of non-neoplastic reactive spleen, yet less likely. FNA of the spleen and liver is recommended for screening purposes or direct splenectomy can be considered. Although structurally the other organs appear unremarkable I cannot rule out that the spleen is a focal manifestation of systemic disease. If any alterations in the CBC are present then bone marrow aspirates may be indicated.

WEIGHT

13.7 lbs

INTERPRETED BY

Eric Lindquist, DMV
DABVP, Cert. IVUSS

IMAGING PERFORMED BY

Shari Reffi, CVT

HOSPITAL NAME

Newton Vet

REFERRING VET

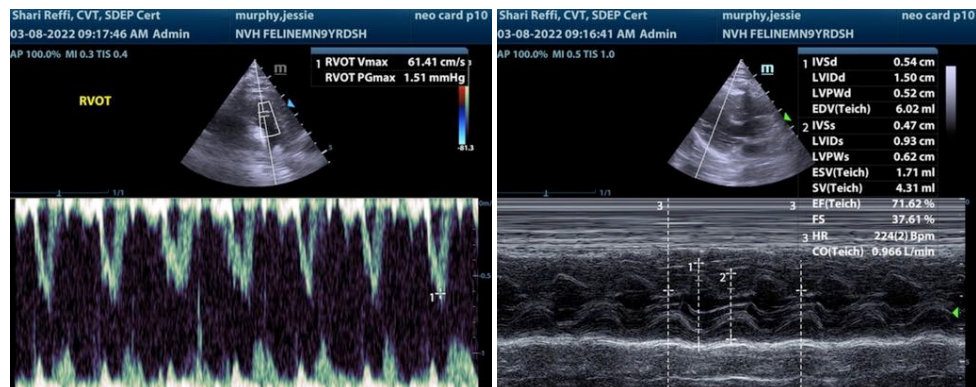
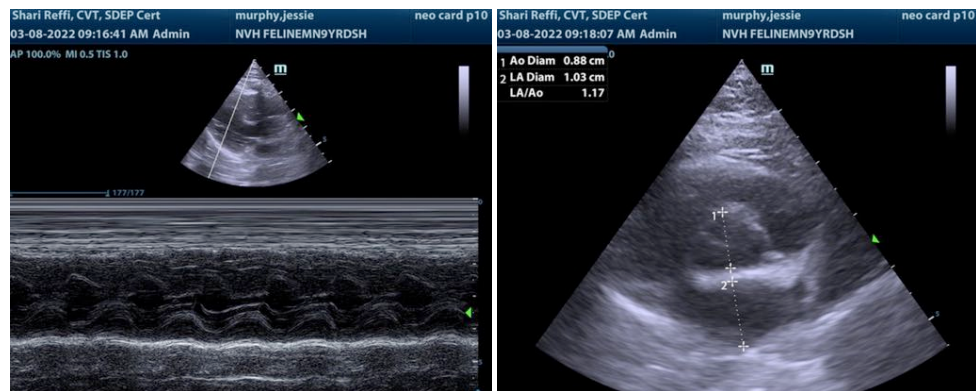
Dr. Verhalen

INVOICE

96645

DATE

3/8/22





PATIENT

Jessie Murphy

SPECIES

Feline

BREED

Domestic Shorthair

SEX

Neutered male

AGE

9 years

WEIGHT

13.7 lbs

INTERPRETED BY

Eric Lindquist, DMV
DABVP, Cert. IVUSS

IMAGING PERFORMED BY

Shari Reffi, CVT

HOSPITAL NAME

Newton Vet

REFERRING VET

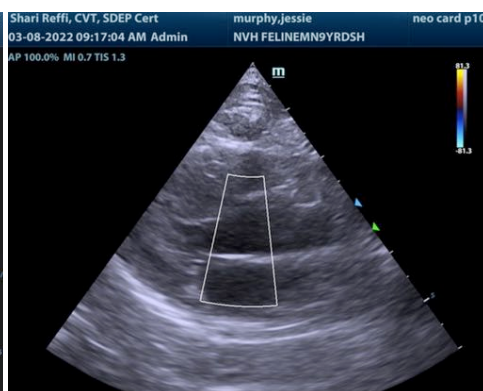
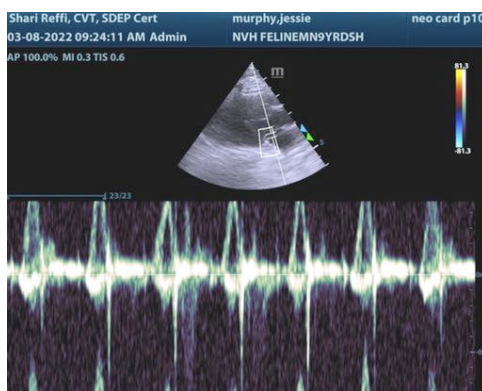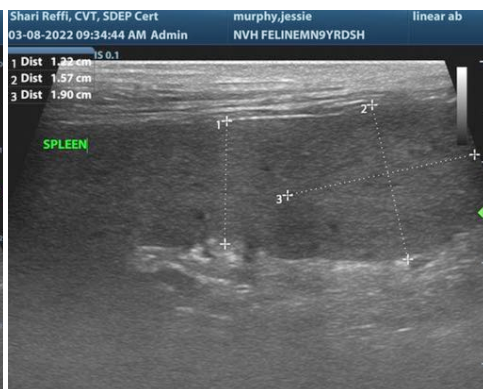
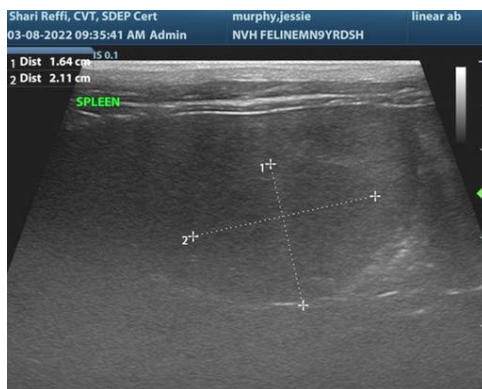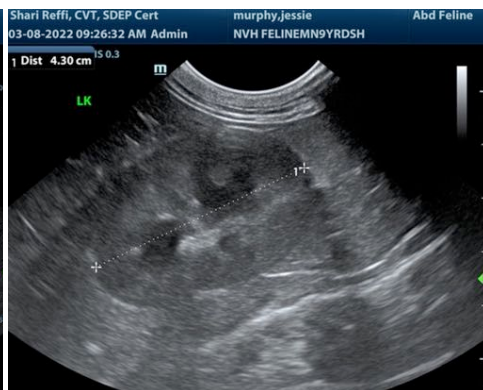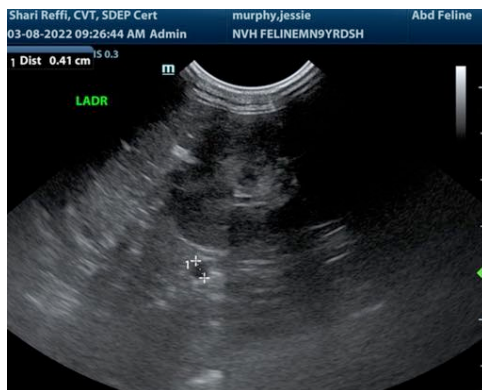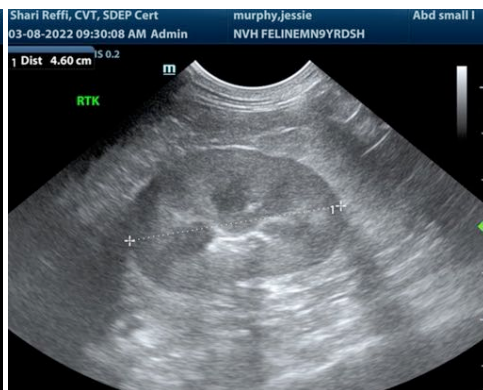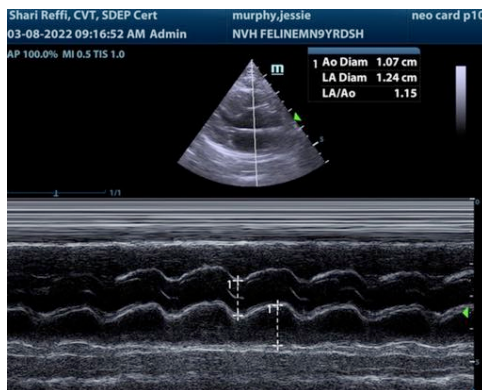
Dr. Verhalen

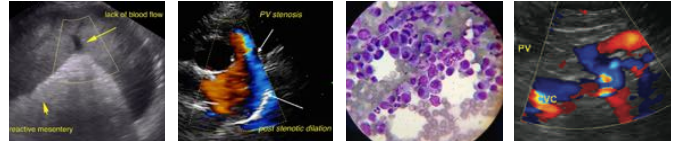
INVOICE

96645

DATE

3/8/22





PATIENT

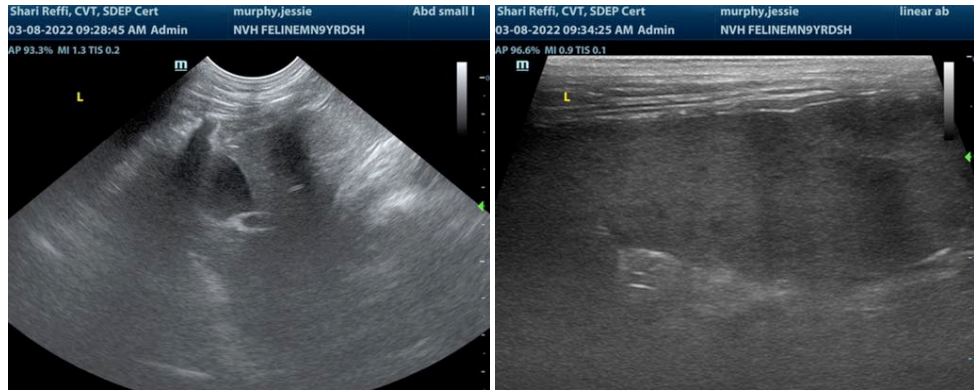
Jessie Murphy

SPECIES

Feline

BREED

Domestic Shorthair



SEX

Neutered male

AGE

9 years

WEIGHT

13.7 lbs

INTERPRETED BY

Eric Lindquist, DMV
DABVP, Cert. IVUSS

IMAGING PERFORMED BY

Shari Reffi, CVT

HOSPITAL NAME

Newton Vet

REFERRING VET

Dr. Verhalen

INVOICE

96645

DATE

3/8/22

The information and recommendations provided are based on the images presented by the referring veterinarian/sonographer. No evaluation can be communicated regarding pathology that was not visible in the image/video clips provided.

Thank you for this referral. If the clinical or image interpretation does not parallel your findings or if I can be of any further assistance please contact me.

Eric Lindquist, DMV, DABVP, Cert. IVUSS, CEO of SonoPath.com
Info@SonoPath.com