

IMAGING PERFORMED BY

IntraPet.com



SonoPath

Clinical Sonography & Telecytology

EDUCATIONAL TELECONSULTATION SERVICES™

1-800-838-4268 info@sonopath.com SonoPath.com

DATE

3/8/22

PATIENT

Dudley Pritchard

SPECIES

Canine

BREED

Yorkshire Terrier

SEX

Neutered Male

AGE

3/8/10

WEIGHT

16.1 Pounds

INTERPRETED BY

Eric Lindquist, DMV
DABVP, Cert. IVUSS

**IMAGING
PERFORMED BY**

Rachel Brilhart RDMS

HOSPITAL NAME

Animal Emergency
Hospital

REFERRING VET

Dr. Kalwa

INVOICE

35994

PRESENTING CLINICAL SIGNS

PC referral from Swan Creek for vomiting, diarrhea, Abnormal CPL. Hx of scrotal hernia- ultrasound performed on it, fat only- not a testicle. Appeared dehydrated. rDVM performed health profile CPL, x ray. No obvious heart murmur.

Current Medications: none given yet.

Lab Results: RDVM bloodwork- HCT 50%, retic high, neutrophil ct WNL, PLT WNL, Glucose WNL, kidney values WNL, ALT WNL, ALKP 238, K 5.9 (Na/K 25), low cl, CPL abnormal.

Radiographs: at RDVM- enlarged liver.

Date of Previous IntraPet Ultrasound: No previous.

Sedation: Not required to complete full diagnostic ultrasound.

Stat Report: Not requested.

ULTRASONOGRAPHIC EXAMINATION OF THE ABDOMEN

Urinary System

The **urinary bladder**, trigone, and pelvic urethra presented normal thicknesses and normal tone. The ureters were not visible which is normal. No uroliths or sediment were visualized and anechoic urine was present. No evidence of inflammatory or neoplastic changes were noted. Ureteral papillae were normal.

The **kidneys** revealed largely normal size and structure, corticomedullary definition and ratio (cortex 1/3 of medulla) were essentially maintained with some age-related loss of curvilinear patterns regarding the capsule and C/M junction. The cortices presented largely uniform texture with some increased echogenicity expected for his age patient. Medullary structure differed distinctly from that of the cortex. The left kidney measured 5.5 cm with trace pyelectasia of 0.34 cm. The right kidney measured 5.62 cm.

Adrenal Glands

The **adrenal glands** appeared slightly enlarged and swollen. No evidence of focal capsular expansion or invasion into the phrenic veins were noted. No overt suspicion of neoplasia was noted. This is considered likely a hyperplastic change associated with stress or adrenal endocrinopathy (PDH). If isosthenuria is persistently present and the patient morphologically suggests Cushing's disease then ACTH testing would be indicated. A hyperechoic nodule was noted in the mid left adrenal gland, measuring 0.68 cm x 0.62 cm. The left adrenal gland measured 2.42 cm x 0.72 cm at the caudal pole and 0.58 cm at the cranial pole. The right adrenal gland was upper limits of normal, measuring 2.13 cm x 0.65 cm at the caudal pole and 0.65 cm at the caudal pole and 0.62 cm at the cranial pole.

Spleen

The **spleen** revealed a focal 8.0 mm hypoechoic nodule in the mid body. Mild disruption of architecture noted. FNA indicated.

Liver

The **liver** was uniformly swollen and presented coarse architecture with mildly increased portal markings and subtle, mixed echogenic changes. This is consistent with vacuolar hepatopathy and some level of remodeling and history of inflammatory component. There was no overt suspicion of neoplasia. The gallbladder was overdilated with immobile bile. Some striation noted.

Gastrointestinal

Examination of the **gastrointestinal tract** revealed a stomach and intestine free of stasis, of normal wall thickness, acceptable curvilinear mural detail, and peristaltic activity. Small and large intestine demonstrated normal luminal chyme and stool consistency respectively. No obstructive or overt infiltrative disease was noted. No associated abnormal lymphatic activity was noted.

Pancreas

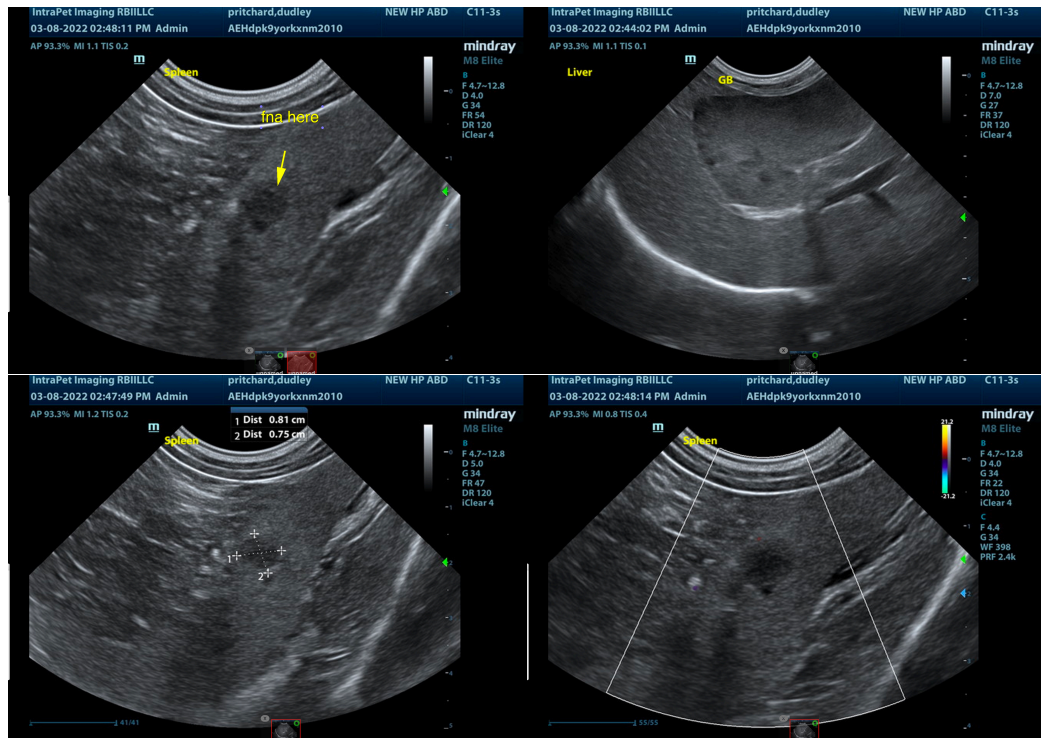
The pancreas presented heterogeneous parenchymal changes with undulating contour. Coarse architecture noted with remodeling.

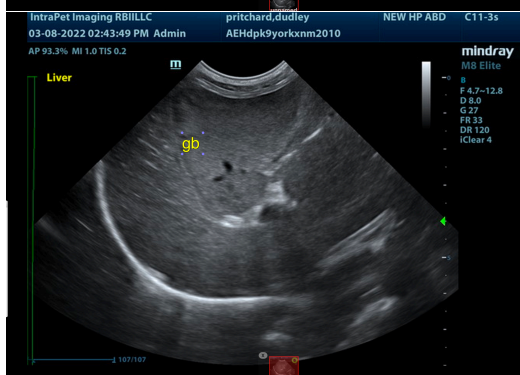
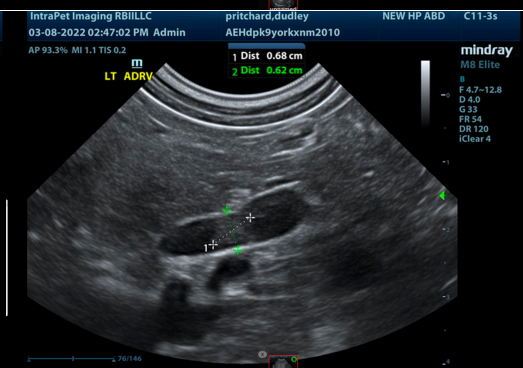
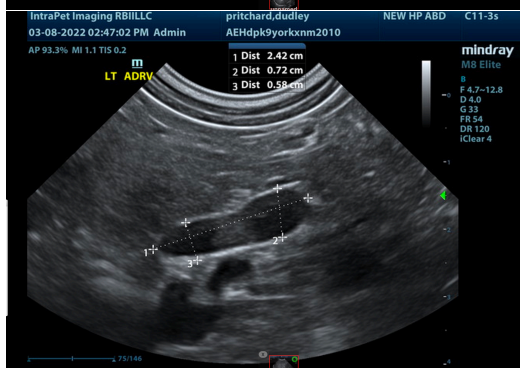
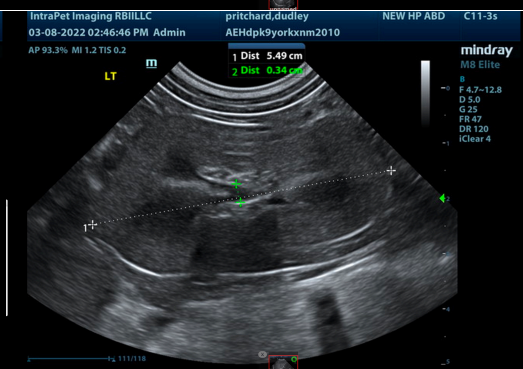
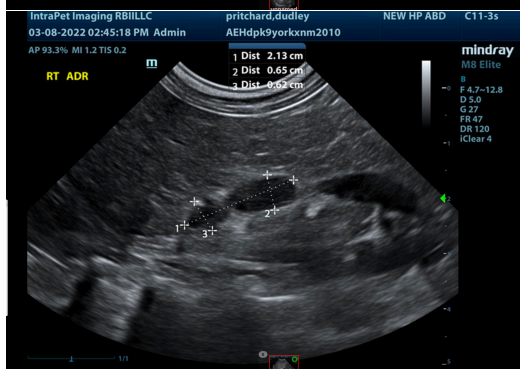
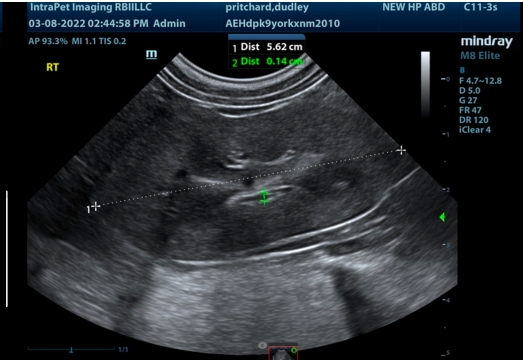
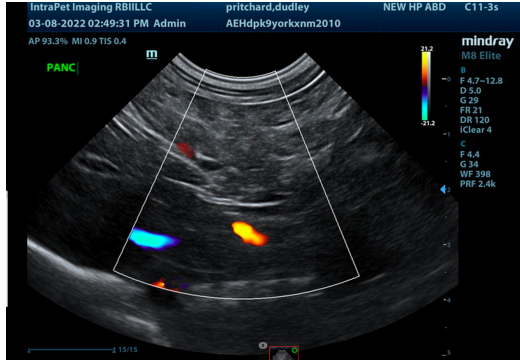
ULTRASONOGRAPHIC FINDINGS

- Subjectively benign hepatopathy with stable gallbladder mucocele
- Chronic pancreatic changes
- Splenic nodule – differentials include benign hyperplasia, abscessation, round cell neoplasia, emerging hemangiosarcoma
- Age related renal changes with slightly swollen adrenal glands

INTERPRETATION OF THE FINDINGS & FURTHER RECOMMENDATIONS

Gallbladder motility study warranted, treatment for pancreatitis, and FNA of the splenic nodule. If patient appears Cushingoid, and USG is <1.020 , then workup for PDH indicated. Ursodiol therapy recommended over the next 8 weeks and recheck of the gallbladder, pancreas, and splenic nodule also an option.





The information and recommendations provided are based on the images presented by the referring veterinarian/sonographer. No evaluation can be communicated regarding pathology that was not visible in the image/video clips provided.

Thank you for this referral. If the clinical or image interpretation does not parallel your findings or if I can be of any further assistance please contact me.

Eric Lindquist, DMV, DABVP, Cert. IVUSS, CEO of SonoPath.com
info@SonoPath.com