



PATIENT

Cali King

PRESENTING CLINICAL SIGNS

History: Decreased appetite, otherwise acting fine Recently had water report with E.coli contamination No V/D

SPECIES

Canine

ULTRASONOGRAPHIC EXAMINATION OF THE ABDOMEN

Urinary System

BREED

Pitbull

The **urinary bladder**, trigone, and pelvic urethra presented normal thicknesses and normal tone. The ureters were not visible which is normal. No uroliths or sediment were visualized and anechoic urine was present. No evidence of inflammatory or neoplastic changes was noted. Ureteral papillae were normal.

SEX

Spayed Female

The **kidneys** revealed largely normal size and structure, corticomedullary definition and ratio (cortex 1/3 of medulla) were essentially maintained with some age-related loss of curvilinear patterns regarding the capsule and C/M junction. The cortices presented largely uniform texture with some increased echogenicity expected for this age patient. Medullary structure differed distinctly from that of the cortex and no evidence of pelvic dilation was present. The left kidney measured 6.24 cm. The right kidney measured 5.12 cm.

AGE

11 years

WEIGHT

66 lbs

Adrenal Glands

The **adrenal glands** were not visualized.

INTERPRETED BY

Eric Lindquist, DMV
DABVP, Cert. IVUSS

Spleen

The **spleen** presented a smooth homogeneous parenchyma hyperechoic to liver and renal cortical parenchyma. The capsule was smooth without noticeable expansion or deviation from within the spleen or adjacent pathology. The splenic vasculature demonstrated normal volume without signs of congestion or thrombosis. No sonographic evidence of acute or chronic inflammatory, neoplastic, or infarctual changes was noted.

IMAGING PERFORMED BY

Chelsea Pastor

HOSPITAL NAME

Fredon AH

Liver

The **liver** was uniformly swollen with minor, excessive gallbladder debris and over distension with dependent and suspended bile without evidence of overt mucocele formation. However, excessive sludge was present. The liver presented coarse architecture with mildly increased portal markings and subtle, mixed echogenic changes. This is consistent with vacuolar hepatopathy and some level of remodeling and history of inflammatory component. There was no overt suspicion of neoplasia.

REFERRING VET

Dr. Grau

INVOICE

96675

Gastrointestinal

The **stomach** was filled with ingesta or soft shadowing material depending upon when the patient ate prior to the sonogram. The small intestine and colon were unremarkable.

DATE

3/8/22



PATIENT

Pancreas

Cali King

The base and limbs of the **pancreas** were observed to be largely isoechoic to surrounding omental fat. Pancreatic duct and capsular contour were acceptably normal and parenchyma respected normal curvilinear patterns. No overt evidence of active inflammatory or neoplastic disease was noted.

SPECIES

Canine

ULTRASONOGRAPHIC FINDINGS

BREED

Pitbull

Geriatric hepatic changes.

Full stomach. Consistent with post prandial presentation.

SEX

Spayed Female

INTERPRETATION OF THE FINDINGS & FURTHER RECOMMENDATIONS

There was no evidence of pathology. There is a potential for foreign matter if the patient was n.p.o. at the time of the sonogram.

AGE

11 years

WEIGHT

66 lbs

INTERPRETED BY

Eric Lindquist, DMV
DABVP, Cert. IVUSS

IMAGING PERFORMED BY

Chelsea Pastor

HOSPITAL NAME

Fredon AH

REFERRING VET

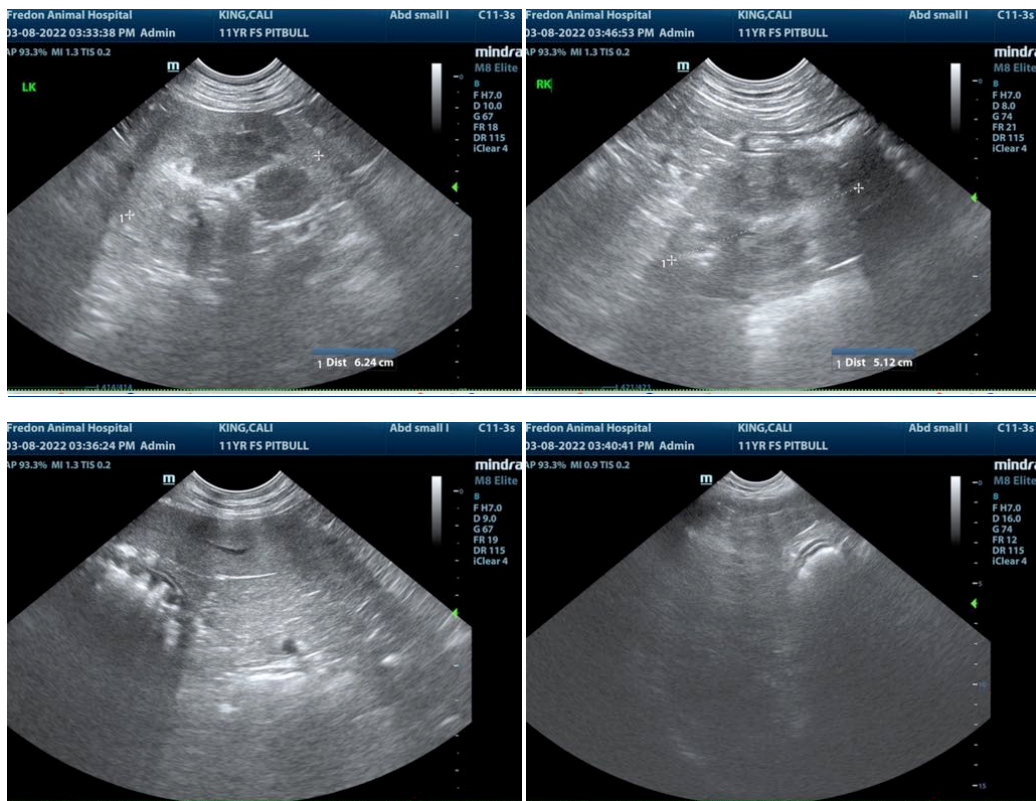
Dr. Grau

INVOICE

96675

DATE

3/8/22





PATIENT

Cali King

SPECIES

Canine

BREED

Pitbull

SEX

Spayed Female

AGE

11 years

WEIGHT

66 lbs

INTERPRETED BY

Eric Lindquist, DMV
DABVP, Cert. IVUSS

IMAGING PERFORMED BY

Chelsea Pastor

HOSPITAL NAME

Fredon AH

REFERRING VET

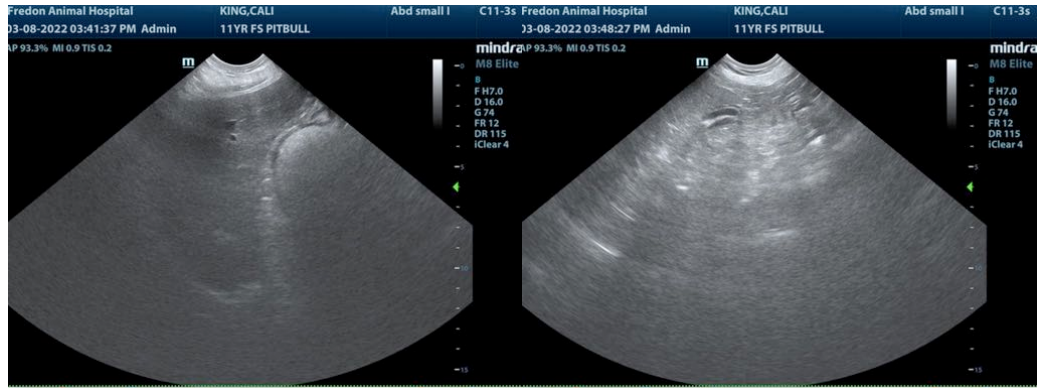
Dr. Grau

INVOICE

96675

DATE

3/8/22



The information and recommendations provided are based on the images presented by the referring veterinarian/sonographer. No evaluation can be communicated regarding pathology that was not visible in the image/video clips provided.

Thank you for this referral. If the clinical or image interpretation does not parallel your findings or if I can be of any further assistance please contact me.

Eric Lindquist, DMV, DABVP, Cert. IVUSS, CEO of SonoPath.com
info@SonoPath.com