



DATE PRESENTING CLINICAL SIGNS

03/07/26

Patient History: Transferred to MDAEH on 3/6/25. Owner took her to rDVM today for acute onset of hiding, inappetence, and abdominal pain. At Shiloh she was hospitalized and received IV fluids and antibiotics. She had a fever of 103.3 and she received Onsior (NSAID) and her temperature improved to 101.2, Serial radiographs were performed that showed gas dilation within the stomach, and some dilation within the small intestine. There was a concern for a foreign body obstruction, and she was transferred near 6:00 p.m.

PATIENT

Missy Heavenly Paws
Animal Shelter

PE: painful abdomen, guarding. Slightly fractious.

SPECIES

Feline

Current Medications: N/A.

BREED

Labwork Results: Labwork not submitted. Reported from rDVM as CBC-UES 0.02 (L), plt 98 (L).

Superchem- Glc 161 (H), BUN 13 (L), Glob 5.5 (H), ALT <10 (L), GGT 0, T bili 2.0 (H), catalyst pancreatic lipase 4.2 (normal).

DSH

Serial abdominal rads from rDVM with Antech radiology review:

SEX

Fluid and gas distention of the stomach and small intestine. Changes could be indicative of a more distal intestinal foreign body;

Spayed Female

however, discrete foreign material is not seen and size of the small intestine does not exceed the upper end of the normal size range.

AGE

Gastroenteritis and extra GI disease altering motility are also considerations. Given the clinical concern for mechanical obstruction,

03/06/15

abdominal ultrasound or upper GI series is recommended to help differentiate.

WEIGHT

Date of Previous IntraPet Ultrasound: No previous.

Sedation: Not required to complete full diagnostic ultrasound.

4.18 kg

Stat Report: Requested.

Imaging Performed by: Andi Parkinson, BS, RDMS.

INTERPRETED BY

ULTRASONOGRAPHIC EXAMINATION OF THE ABDOMEN

Eric Lindquist, DMV,
DABVP(CFM), Cert.
IVUSS

Urinary System

The **urinary bladder**, trigone, and pelvic urethra to a depth of 2.0 cm presented normal thicknesses and normal tone. The ureters were not visible which is normal. No uroliths or sediment were visualized, and anechoic urine was present. No evidence of inflammatory or neoplastic changes were noted. Ureteral papillae were normal.

HOSPITAL NAME

Mason Dixon Animal
Emergency

The **kidneys** revealed largely normal size and structure, corticomedullary definition and ratio (cortex 1/3 of medulla) were essentially maintained with some minor age-related loss of curvilinear patterns regarding the capsule and C/M junction. The cortices presented largely uniform texture with some increased echogenicity expected for his age patient. Medullary structure differed distinctly from that of the cortex and no evidence of pelvic dilation was present. The left kidney measured 3.45 cm in length. The right kidney measured 3.85 cm in length.

REFERRING VET

Not Provided

INVOICE

Adrenal Glands

14132

The **left adrenal gland** was visualized and recognized as having normal shape, size, position and echogenicity for this breed. The phrenic vasculature, glandular echogenicity and detail were unremarkable. Capsule, cortex, and medullary definition were normal for this age patient. The left adrenal gland measured 0.38 cm width.

The **right adrenal gland** was not visualized.

Spleen

The **spleen** was mildly enlarged with uniform, but subtly micronodular parenchyma, and undulating capsular contour. This is consistent with reactive spleen owing to immune stimulus or early infiltrative disease such as mast cell disease or lymphoma. 25-gauge FNA would be ideal if weight loss is an issue to differentiate early round cell neoplasia versus splenitis or reactive spleen all of which can present in this manner.

Liver

The **liver** images submitted revealed subjectively normal liver size, contour, and structure. Parenchymal echogenicity was naturally coarse and hypoechoic to the spleen. Vascular and biliary tracts were of normal volume with no evidence of congestion. The gallbladder presented acceptably thin walls with primarily anechoic content. The cystic and common bile ducts were normal. No pathological hepatic lymphadenopathy was evident. No overt structural evidence of inflammatory, infiltrative or regenerative pathology was evident.

Gastrointestinal

The **stomach** was empty. The pylorus was mildly thickened with increased submucosal echogenicity. Some spastic small intestine was noted without evidence of foreign matter. The distal small intestine was mildly thickened with reactive mesentery. The colon was unremarkable.

Pancreas

The right **pancreas** was observed to be largely isoechoic to surrounding omental fat. Some mild parenchymal remodeling, however, with mild deviation from curvilinear normalcy was observed. Pancreatic duct and capsular irregularities were present consistent with age related changes. If pain upon imaging (+ Murphy sign) was present or if the patient is focally painful in subxiphoid palpation, then low-grade smoldering chronic pancreatitis should be suspected. The pancreas measured 0.57 cm.

The caudal aspect of the left pancreatic limb was hypoechoic and irregular with mild enhanced surrounding mesentery suggestive of inflammation.

Free Abdomen

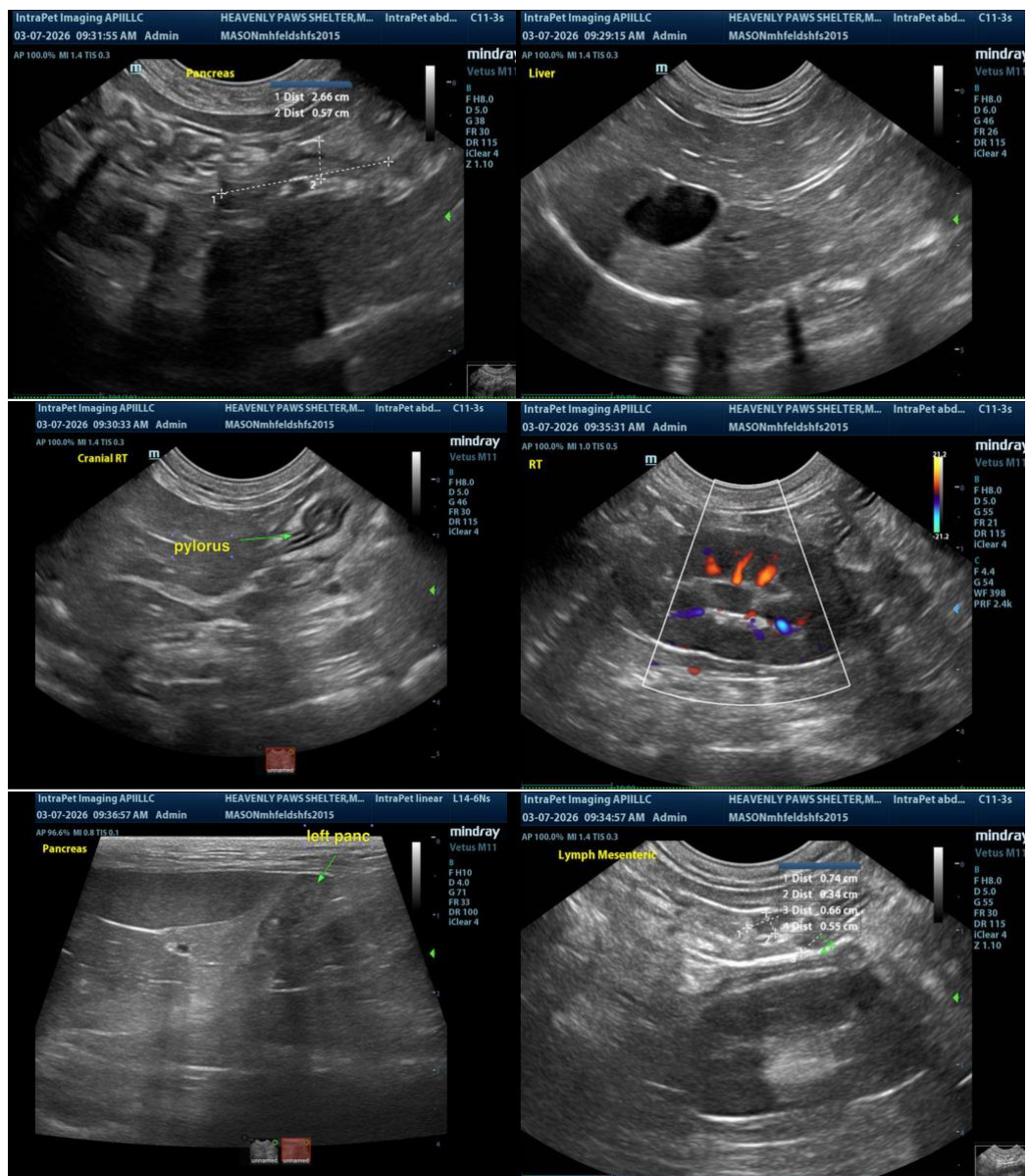
The mesenteric **lymph nodes** presented normal length to width ratio with slight, swollen contour. There was no loss of parenchymal detail. This is most consistent with reactive lymphadenitis or lymphatic hyperplasia. The lymph nodes measured up to 0.74 cm. Slightly enlarged rounded colic lymph nodes were also present measuring up to 0.62 cm.

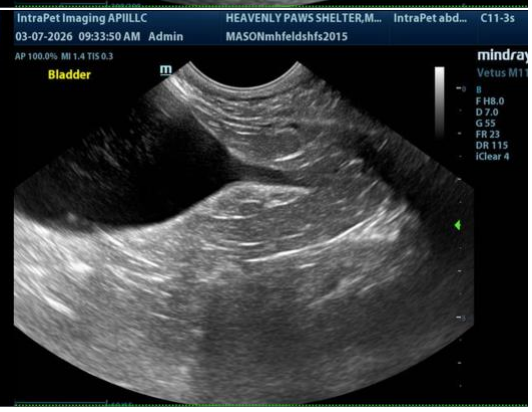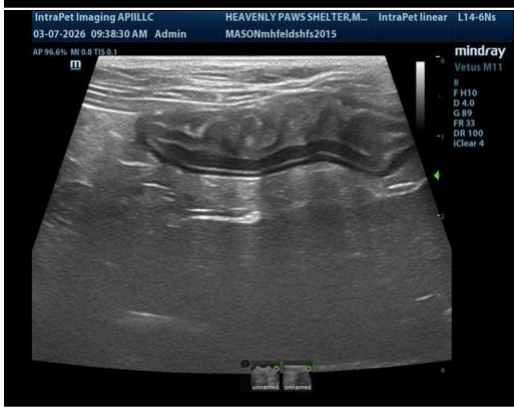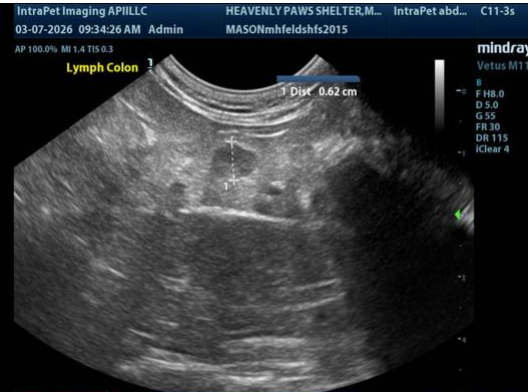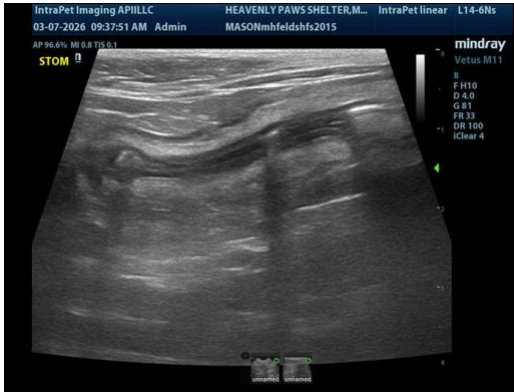ULTRASONOGRAPHIC FINDINGS

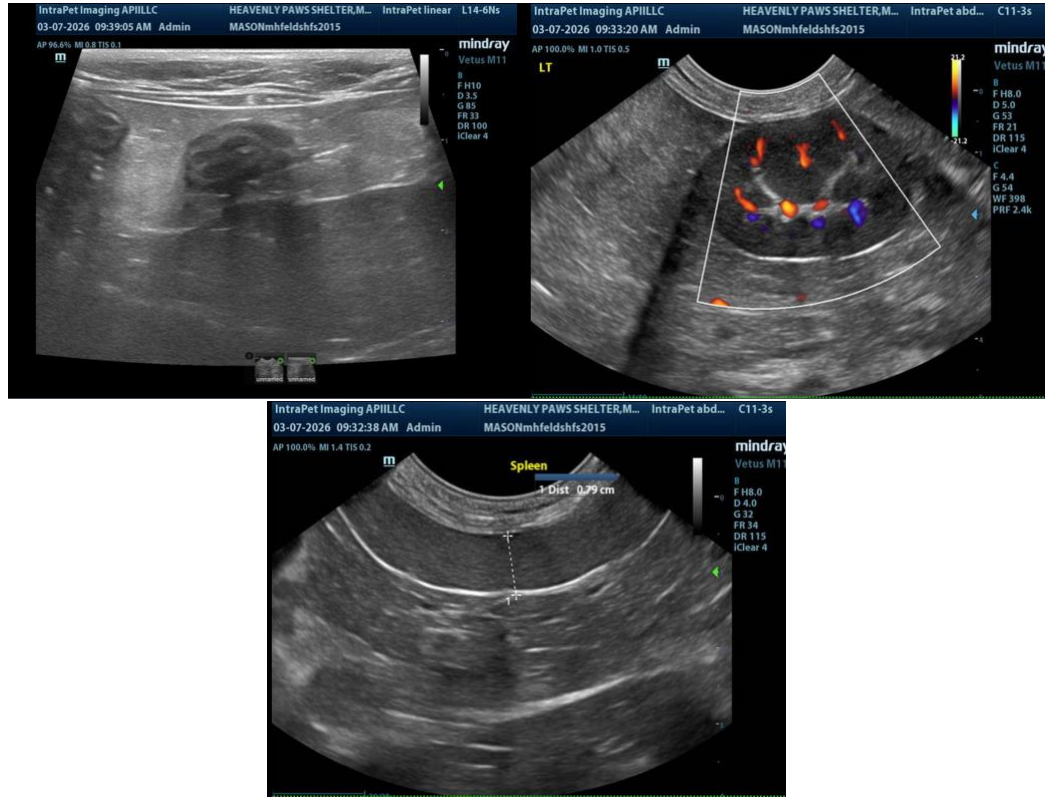
- Slight heterogenous hypoechoic right pancreatic changes- possible low-grade focal pancreatitis of the right pancreatic base.
- Mild splenic enlargement.
- Chronic gastritis pattern.
- Lymphoproliferative pattern- likely reactive.
- Age-related renal changes.
- Enteritis pattern.

INTERPRETATION OF THE FINDINGS & FURTHER RECOMMENDATIONS

Management for pancreatitis and gastritis is indicated. FNA of the spleen is indicated if weight loss is an issue. No overt evidence of neoplasia or foreign bodies. Pain management, IV fluid support and broad-spectrum antibiotics are all indicated. Underlying infectious agents should be considered if not already screened (toxoplasmosis, Bartonella or similar).







The information and recommendations provided are based on the images presented by the referring veterinarian/sonographer. No evaluation can be communicated regarding pathology that was not visible in the image/video clips provided.

Thank you for this referral. If the clinical or image interpretation does not parallel your findings or if I can be of any further assistance, please contact me.

Eric Lindquist, DMV, DABVP(CFM), Cert. IVUSS,

CEO, Owner, Founder -- SonoPath.com

info@SonoPath.com