



PATIENT

Mac Whitemire

SPECIES

Canine

BREED

Chihuahua Mix

SEX

Neutered male

AGE

10 years

WEIGHT

10 kg

INTERPRETED BY

Eric Lindquist, DMV
DABVP, Cert. IVUSS

IMAGING PERFORMED BY

Michael Schacher

HOSPITAL NAME

Emergency
Veterinarians of Idaho

REFERRING VET

Dr. Sorenson

INVOICE

72331

DATE

3/7/26

PRESENTING CLINICAL SIGNS

- BBD - 700 ALT found during pre-op bloodwork
- Very painful on right side

ULTRASONOGRAPHIC EXAMINATION OF THE ABDOMEN

Urinary System

The **urinary bladder**, trigone, and pelvic urethra presented normal thicknesses and normal tone. The ureters were not visible which is normal. No uroliths or sediment were visualized and anechoic urine was present. No evidence of inflammatory or neoplastic changes was noted. Ureteral papillae were normal.

The **kidneys** revealed largely normal size and structure, corticomedullary definition and ratio (cortex 1/3 of medulla) were essentially maintained with some age-related loss of curvilinear patterns regarding the capsule and C/M junction. The cortices presented largely uniform texture with some increased echogenicity expected for this age patient. Medullary structure differed distinctly from that of the cortex and no evidence of pelvic dilation was present. Slight pinpoint mineralization was noted in the kidneys. The left kidney measured 5.0 cm. The right kidney measured 3.7 cm.

The iliac trifurcation was unremarkable.

Adrenal Glands

The left **adrenal gland** was visualized and recognized as having normal shape, size, position and echogenicity for this breed. The phrenic vasculature, glandular echogenicity and detail were unremarkable. Capsule, cortex, and medullary definition were normal for this age patient. The left adrenal gland measured 0.5 cm. The region of the right adrenal gland was imaged with no evidence of pathology.

Spleen

The **spleen** presented a smooth homogeneous parenchyma hyperechoic to liver and renal cortical parenchyma. The capsule was smooth without noticeable expansion or deviation from within the spleen or adjacent pathology. The splenic vasculature demonstrated normal volume without signs of congestion or thrombosis. No sonographic evidence of acute or chronic inflammatory, neoplastic, or infarctual changes was noted.

Liver

The **liver** was uniform with vacuolar hepatopathy pattern. The gallbladder and common bile duct were unremarkable. There was no significant amount of remodeling were noted.



PATIENT

Mac Whitemire

SPECIES

Canine

BREED

Chihuahua Mix

SEX

Neutered male

AGE

10 years

WEIGHT

10 kg

INTERPRETED BY

Eric Lindquist, DMV
DABVP, Cert. IVUSS

IMAGING PERFORMED BY

Michael Schacher

HOSPITAL NAME

Emergency Veterinarians of Idaho

REFERRING VET

Dr. Sorenson

INVOICE

72331

DATE

3/7/26

Gastrointestinal

Examination of the **gastrointestinal tract** revealed a stomach and intestine free of stasis, of normal wall thickness, acceptable curvilinear mural detail, and peristaltic activity. Small and large intestine demonstrated normal luminal chyme and stool consistency respectively. No obstructive or overt infiltrative disease was noted. No associated abnormal lymphatic activity was noted.

Pancreas

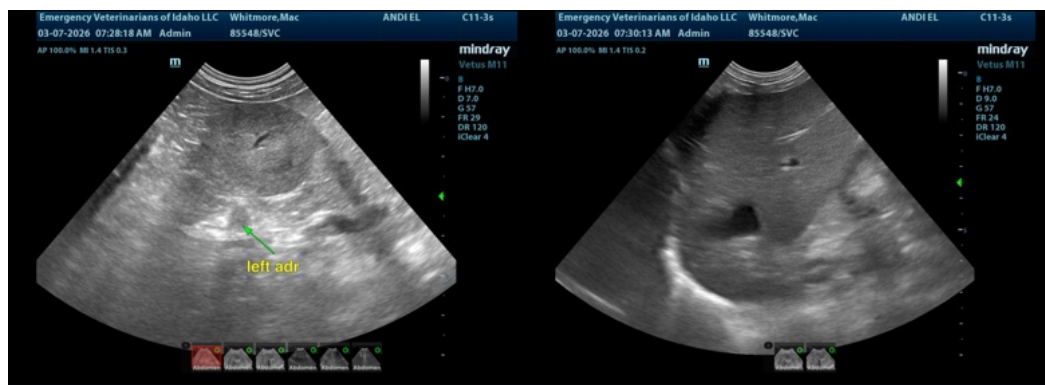
The base and limbs of the **pancreas** were observed to be largely isoechoic to surrounding omental fat. Pancreatic duct and capsular contour were acceptably normal and parenchyma respected normal curvilinear patterns. No overt evidence of active inflammatory or neoplastic disease was noted.

ULTRASONOGRAPHIC FINDINGS

Non-specific, low-grade inflammatory hepatopathy. Subacute to acute insult.

INTERPRETATION OF THE FINDINGS & FURTHER RECOMMENDATIONS

FNA of the liver can be considered for further definition. There was no evidence of visceral disease that would be responsible for the abdominal tension. Referred back pain should be considered as a potential. Leptospirosis titers are indicated given the ALT elevation that is unexplained.





PATIENT

Mac Whitmire

SPECIES

Canine

BREED

Chihuahua Mix

SEX

Neutered male

AGE

10 years

WEIGHT

10 kg

INTERPRETED BY

Eric Lindquist, DMV
DABVP, Cert. IVUSS

IMAGING PERFORMED BY

Michael Schacher

HOSPITAL NAME

Emergency Veterinarians of Idaho

REFERRING VET

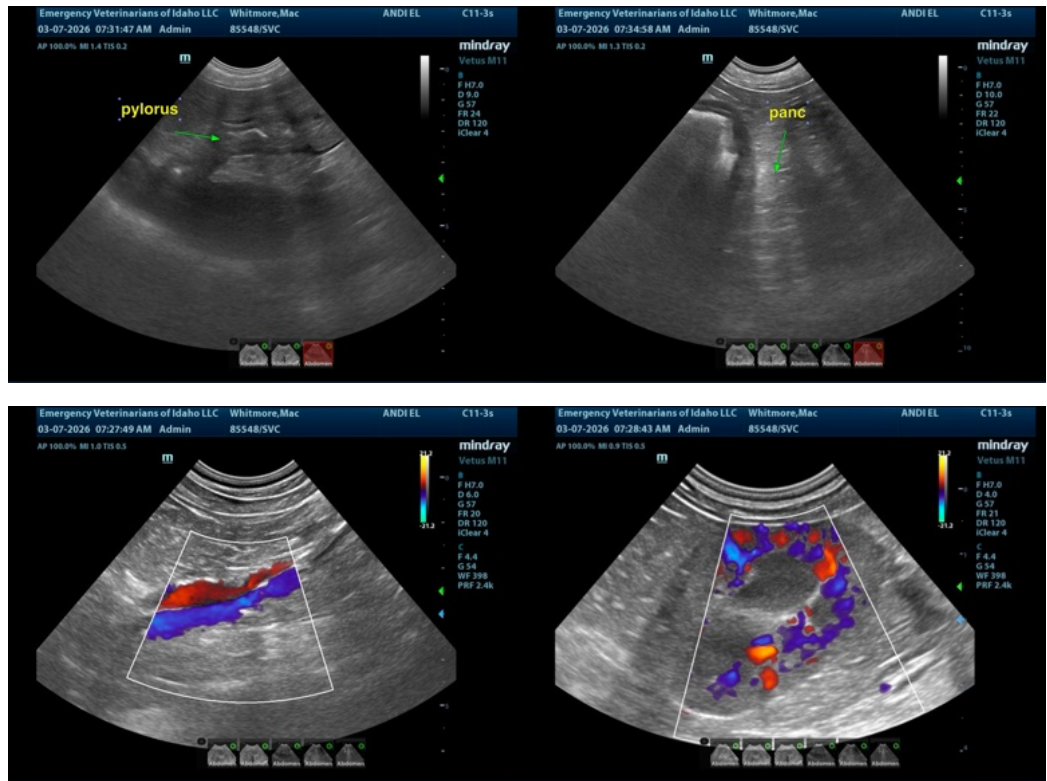
Dr. Sorenson

INVOICE

72331

DATE

3/7/26



The information and recommendations provided are based on the images presented by the referring veterinarian/sonographer. No evaluation can be communicated regarding pathology that was not visible in the image/video clips provided.

Thank you for this referral. If the clinical or image interpretation does not parallel your findings or if I can be of any further assistance please contact me.

Eric Lindquist, DMV, DABVP (CFM), Cert. IVUSS, CEO of SonoPath.com

info@SonoPath.com