

DATE PRESENTING CLINICAL SIGNS

3/7/23

Patient is doing well at home with no concerns. Planned to recheck a scan around this time anyway, but recently we have seen some persistent neutropenia.

PATIENT

Current Medications: None current but on urinary diet

Poppy Coyle

Lab Results: CBC: MCV: 36 (39 - 56), Reticulocyte hemoglobin: 15 (15.3 - 22.9), Neutrophils: 2.08 (2.62 - 15.17) ----> Was 2.446 on 12/05/2022

Chemistry: Calcium: 11.8 (8.2 - 11.2). UA/T4: WNL

Interpretation: Neutropenia, persistent

SPECIES

Date of Previous IntraPet Ultrasound: 11/29/22. See attached.

Feline

Sedation: Not required to complete full diagnostic ultrasound.

Stat Report: Not requested.

Imaging Performed By: Stephanie Warga RDCS, RVT.

BREED

Feline

ULTRASONOGRAPHIC EXAMINATION OF THE ABDOMEN

Urinary System

The **urinary bladder**, trigone, and pelvic urethra presented normal thicknesses and normal tone. The ureters were not visible which is normal. The prior calculus presentation has resolved. No evidence of inflammatory or neoplastic changes was noted. Ureteral papillae were normal.

Domestic Shorthair

AGE

8/15/21

The **left kidney** revealed normal size and structure, corticomedullary definition and ratio for this age. The cortices presented largely uniform texture with normal echogenic relationship to liver and spleen. Medullary structure differed distinctly from the cortex and no evidence of pelvic dilation was present. The capsules were acceptably uniform without significant irregularities. The left kidney revealed a corticomedullary calculus that measured 0.3 cm and was non-obstructive. The left kidney measured 4.41 cm. The right kidney is severely dystrophic at 1.9 cm. Blood flow to the right kidney was minor with cortical infarcts noted. This may be a primary dysplastic change or secondary to movement and progressive obstructive disease from nephrolithiasis passage and periodic obstructive events, yet appears stable at this time.

WEIGHT

10 lbs

INTERPRETED BY

Eric Lindquist, DMV
DABVP, Cert. IVUSS

Adrenal Glands

Both **adrenal glands** were visualized and recognized as having normal shape, size, position and echogenicity for this breed. The phrenic vasculature, glandular echogenicity and detail were unremarkable. Capsule, cortex, and medullary definition were normal for this age patient.

HOSPITAL NAME

Perry Hall AH

Spleen

The **spleen** presented a smooth homogeneous parenchyma hyperechoic to liver and renal cortical parenchyma. The capsule was smooth without noticeable expansion or deviation from within the spleen or adjacent pathology. The splenic vasculature demonstrated normal volume without signs of congestion or thrombosis. No sonographic evidence of acute or chronic inflammatory, neoplastic, or infarctual changes was noted.

REFERRING VET

Dr. Miller

INVOICE

43174

Liver

The **liver** images submitted revealed subjectively normal liver size, contour, and structure. Parenchymal echogenicity was naturally coarse and hypoechoic to the spleen. Vascular and biliary tracts were of normal volume with no evidence of congestion. The gallbladder presented acceptably thin walls with primarily anechoic content. The cystic and common bile ducts were normal. No pathological hepatic lymphadenopathy was evident. No overt structural evidence of inflammatory, infiltrative or regenerative pathology was evident.

Gastrointestinal

Examination of the **gastrointestinal tract** revealed a stomach and intestine free of stasis, of normal wall thickness, acceptable curvilinear mural detail, and peristaltic activity. Small and large intestine demonstrated normal luminal chyme and stool consistency respectively. The mesenteric lymph nodes measured up to 1.0 cm.

Pancreas

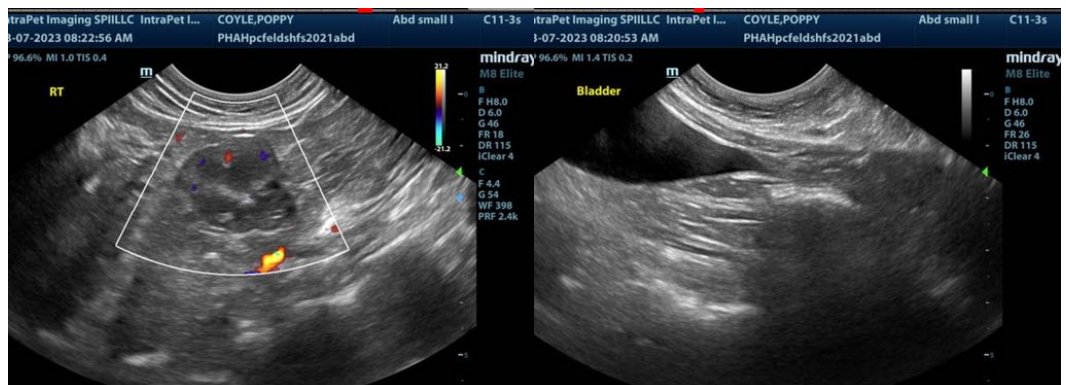The base and limbs of the **pancreas** were observed to be largely isoechoic to surrounding omental fat. Pancreatic duct and capsular contour were acceptably normal and parenchyma respected normal curvilinear patterns. No overt evidence of active inflammatory or neoplastic disease was noted.

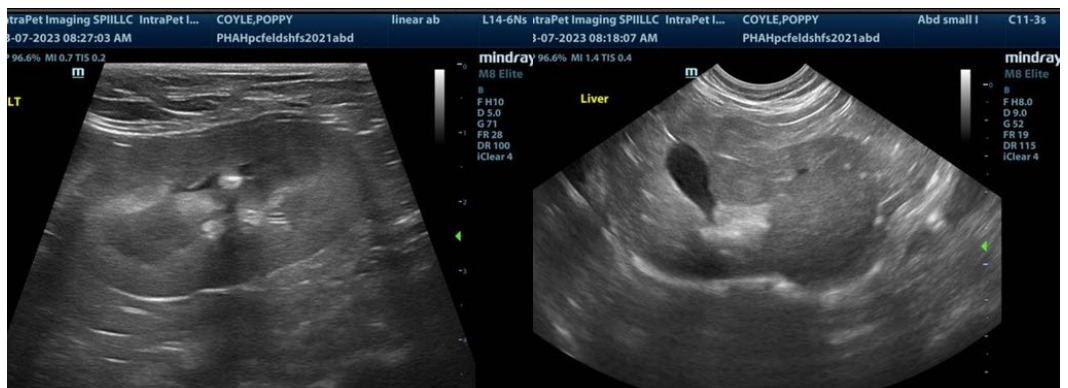
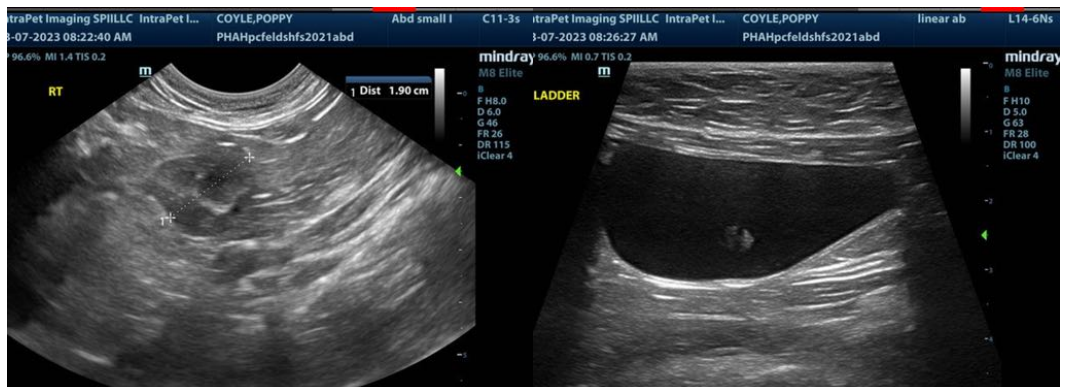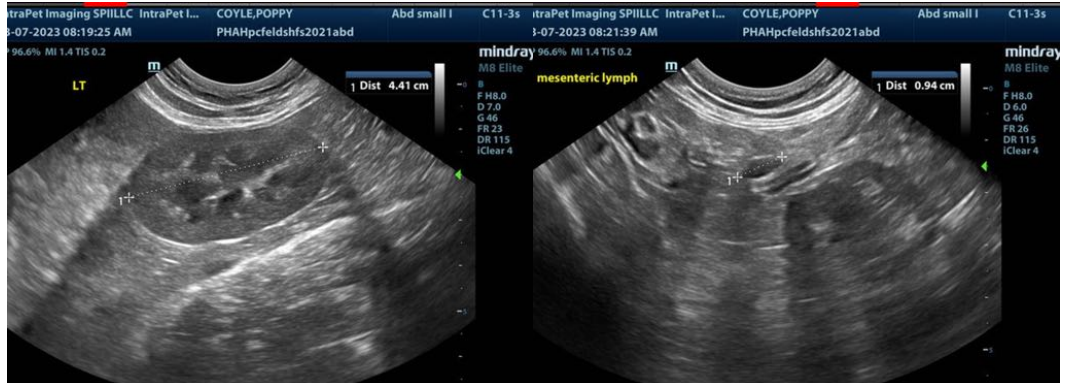
ULTRASONOGRAPHIC FINDINGS

Dystrophic or primary renal dysplasia of the right kidney.
Minor, non-obstructive nephrolithiasis of the left kidney.
Normalized urinary bladder. No further calculi was present.

INTERPRETATION OF THE FINDINGS & FURTHER RECOMMENDATIONS

The patient currently appears stable.





The information and recommendations provided are based on the images presented by the referring veterinarian. No evaluation can be communicated regarding pathology that was not visible in the image/video clips provided.

Thank you for this referral. If the clinical or image interpretation does not parallel your findings or if I can be of any further assistance please contact me.

Eric Lindquist, DMV, DABVP, Cert. IVUSS, CEO of SonoPath.com
 Eric.Lindquist@SonoPath.com