



PATIENT

PRESENTING CLINICAL SIGNS

Collin Herig

History: frequent urination increased hunger and thirst

SPECIES

ULTRASONOGRAPHIC EXAMINATION OF THE ABDOMEN

Canine

Urinary System

BREED

The **urinary bladder** revealed apical ventral and apical dorsal polypoid changes with anechoic urine. Otherwise, the cystourethral junction and urethra were unremarkable. Minor dorsal bladder wall thickening was noted.

Collie Mix

SEX

The **kidneys** revealed largely normal size and structure, corticomedullary definition and ratio (cortex 1/3 of medulla) were essentially maintained with some age-related loss of curvilinear patterns regarding the capsule and C/M junction. The cortices presented largely uniform texture with some increased echogenicity expected for his age patient. Medullary structure differed distinctly from that of the cortex and no evidence of pelvic dilation was present. The left kidney measured 6.05 cm. The right kidney measured 5.0 cm.

Neutered male

AGE

11 years

WEIGHT

Adrenal Glands

30 lbs

The left adrenal gland was moderately enlarged and measured 2.55 x 1.0 cm at the caudal pole and 1.12 cm at the cranial pole. The right adrenal gland was mildly heterogenous, yet fairly uniform. The right adrenal gland was normal in size measuring 1.0 cm at the cranial pole and 0.8 cm at the caudal pole.

INTERPRETED BY

Eric Lindquist, DMV
DABVP, Cert. IVUSS

Spleen

IMAGING PERFORMED BY

Jenn

The **spleen** presented a smooth homogeneous parenchyma hyperechoic to liver and renal cortical parenchyma. The capsule was smooth without noticeable expansion or deviation from within the spleen or adjacent pathology. The splenic vasculature demonstrated normal volume without signs of congestion or thrombosis. No sonographic evidence of acute or chronic inflammatory, neoplastic, or infarctual changes was noted.

HOSPITAL NAME

Rockaway AH

Liver

REFERRING VET

Dr. Maniar

The **liver** was uniformly swollen. The liver presented coarse architecture with mildly increased portal markings and subtle, mixed echogenic changes. This is consistent with vacuolar hepatopathy and some level of remodeling and history of inflammatory component. There was no overt suspicion of neoplasia. The gallbladder was mildly over distended with suspended and dependent debris, yet not to the level of emerging mucocele, yet sludge appears to be mildly excessive. Gallbladder polyps were noted. No adjunctive inflammation was noted.

INVOICE

43154

DATE

3/7/23



PATIENT	<i>Gastrointestinal</i>
Collin Herig	Examination of the gastrointestinal tract revealed a stomach and intestine free of stasis, of normal wall thickness, acceptable curvilinear mural detail, and peristaltic activity. Small and large intestine demonstrated normal luminal chyme and stool consistency respectively. No obstructive or overt infiltrative disease was noted. No associated abnormal lymphatic activity was noted.
SPECIES	
Canine	
BREED	<i>Pancreas</i>
Collie Mix	The base and limbs of the pancreas were observed to be largely isoechoic to surrounding omental fat. Pancreatic duct and capsular contour were acceptably normal and parenchyma respected normal curvilinear patterns. No overt evidence of active inflammatory or neoplastic disease was noted.
SEX	<i>Free Abdomen</i>
Neutered male	A mesenteric cyst was noted caudal to the right kidney and is not pathological. The mesenteric cyst measured 1.5 cm.
AGE	
11 years	
WEIGHT	ULTRASONOGRAPHIC FINDINGS
30 lbs	Polypoid cystitis bladder pattern with the possibility of carcinoma. Enlarged, irregular left adrenal gland. Heterogenous hyperplasia is likely with a minor potential for carcinoma or pheochromocytoma.
INTERPRETED BY	Gallbladder sludge and polyps. Vacuolar hepatopathy pattern. Mesenteric cyst.
Eric Lindquist, DMV DABVP, Cert. IVUSS	Geriatric abdomen.
IMAGING PERFORMED BY	
Jenn	<u>INTERPRETATION OF THE FINDINGS & FURTHER RECOMMENDATIONS</u>
HOSPITAL NAME	Work-up for UTI is warranted in this patient. If the patient appears Cushingoid and the urine specific gravity is less than 1.020 then work-up for PDH is indicated. BRAF testing and cytospin of a free catch urine sample is recommended to assess for exfoliating neoplasia is indicated.
Rockaway AH	
REFERRING VET	Efficient & Accurate Cushing's Work up-Lindquist
Dr. Maniar	Notes regarding Cushing's Clinical Presentations:
INVOICE	<i>Nearly all Cushing's dogs have SAP elevations and true PU/PD (USG < 1.025) and most are polyphagic.</i>
43154	<i>Cushing's dogs are > 6 years and usually > 9 years old, usually have poor skin coats, body scores > 3/5, and are usually sedentary animals.</i>
DATE	<i>Its important to remember that Cushing's dogs usually look and play the part and other diseases cause false + stress related cortisol spikes. On rare occasion a Cushing's dog will not follow the rules but this is truly an exception.</i>
3/7/23	



PATIENT

Collin Herig

SPECIES

Canine

BREED

Collie Mix

SEX

Neutered male

AGE

11 years

WEIGHT

30 lbs

INTERPRETED BY

Eric Lindquist, DMV
DABVP, Cert. IVUSS

IMAGING PERFORMED BY

Jenn

HOSPITAL NAME

Rockaway AH

REFERRING VET

Dr. Maniar

INVOICE

43154

DATE

3/7/23

Potential Cushing's patient workups can be costly and frustrating if not definitive and, in my experience, the non-definitive patient usually has something else going on that may be contributing to some of the clinical signs a Cushing's dog will have, especially SAP elevations or PU/PD. Based on this prelude of information I came up with the following algorithm in the spirit of diagnostic efficiency. The following suggested protocol is based on current available literature on Cushing's disease and extensive clinical-sonographic experience evaluation + Cushing's and False + LDDST & ACTH stim. cases in order to maximize the efficiency of a Cushing's workup in practice.

Screen first, workup second

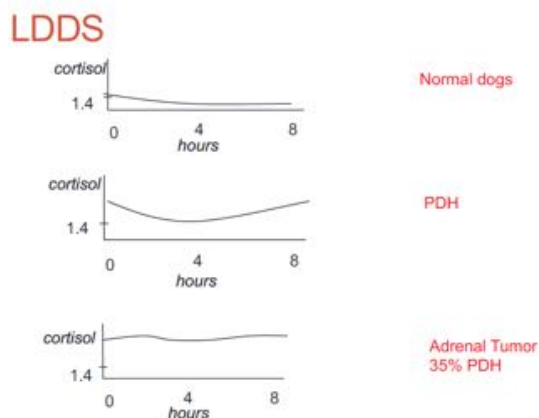
1) **UA:** Repeatable (2-3 urine samples) Urine specific gravity & urine cortisol/creatinine ratio (UCCR): If **repeatable USG < 10.20 and + UCCR** move to next step 2.

Note: UA is inexpensive and easy to obtain and if UA criteria is not met for Cushing's then resources can be spent into other more pertinent diagnostics or left on hold until the UA criteria is met in emerging Cushing's cases.

2) **Sonogram:** Does the patient **have concurrent disease** clinically or sonographically as non-Cushing's illness will influence the potential false + LDDST or even ACTH stim. The sonogram gives a global perspective of the internal health of the patient to be considered in the Cushing's workup as an assessment of concurrent disease. Is there a concurrent neoplastic process, UTI pancreatitis, mucocele....? Are the adrenals enlarged (Cushing's-PDH, stress, age related or breed variant), or atrophied (iatrogenic Cushing's or adrenal burnout), have asymmetric enlargement (Adrenal tumor, hyperplasia, adenoma, age related variant), or is there vascular invasion (Invasive pheo with false + UA criteria or adenocarcinoma or phrenic thrombosis)? The sonogram answers these questions proactively.

Address & treat concurrent disease first before performing Cushing's testing or testing will be artificially altered increasing false negatives and positives.

3) **LDDST** (0.01 D-Sodium phosphate mg/kg IV **with precise dosing******) (Better screening test but plagued with false + but considered more specific than ACTH stim) Use if there is potential early Cushing's or if adrenal asymmetry present on sonogram suspecting tumor. Use LDDST in cats at a higher dose (0.1 mg/kg IV). **Interpretation LDDST:** Look at 8-hour post first: If > 1.4 = Cushing's. Then look at 4-hour: if > 1.4 or > 50% baseline = Cushing's. 4-hour do then 8-hour spike most consistent with PDH. Flat line high constant curve without dip more consistent with tumor but can be PDH. See attached graph.



Courtesy: Rebecca Berg DACVIM, DECVIM



PATIENT

Collin Herig

4) **ACTH stim.** (Better confirming test but can have false +) Use if the patient “looks” Cushingoid or if bilateral adrenal enlargement is present, or high normal width on sonogram, or if iatrogenic Cushing’s suspected (Cortisone Tx in past). ACTH stim is better for diagnosis of Addisons, Iatrogenic Cushing’s, and Cushing’s therapy monitoring but problematic with initial Cushing’s diagnosis. First dx LDDST is suggested.

SPECIES

Canine

5) If **diabetic** then run both LDDST & ACTH stim but stabilize as much as possible first.

BREED

Collie Mix

5) Run a **serial blood pressure** in a BP friendly non “white coat effect” atmosphere. Run at least 3 at different times over a few hours or when eating as the patient tends to be calm when eating or give Torbutrol when entering the facility. Cushing’s hypertension is usually 150-180 systolic range while pheochromocytoma range is more often > 180 systolic.

SEX

Neutered male

6) **Perform CT** of the pituitary to identify macro adenoma expansion if any lethargy or dullness or other central clinical CNS signs are minimally present. CT for adrenal may be more thorough for adrenalectomy surgical planning if ultrasound views of the CVC were problematic.

AGE

11 years

7) **Adrenalectomy** for adrenal mass is prescribed then it is essential to stabilize the patient first regarding secondary disease such as organ dysfunction, hypertension, diabetes mellitus, hypernatremia, thromboembolic risk urinary and other infection in order to minimize potential for operative and postoperative complications as they are common in adrenalectomy. Trilostane stabilization therapy for Cushing’s would be the first approach then address surgery and hypertension should be managed ideally < 160 systolic with ace inhibitors, phenoxybenzamine, or amlodipine.

WEIGHT

30 lbs

Suggested reading:

INTERPRETED BY

Eric Lindquist, DMV
DABVP, Cert. IVUSS

Behrend EN, Kooistra HS, Nelson R, et al. Diagnosis of Spontaneous Canine Hyperadrenocorticism: 2012 ACVIM Consensus Statement (Small Animal). J Vet Intern Med 2013;27:1292–1304.

IMAGING PERFORMED BY

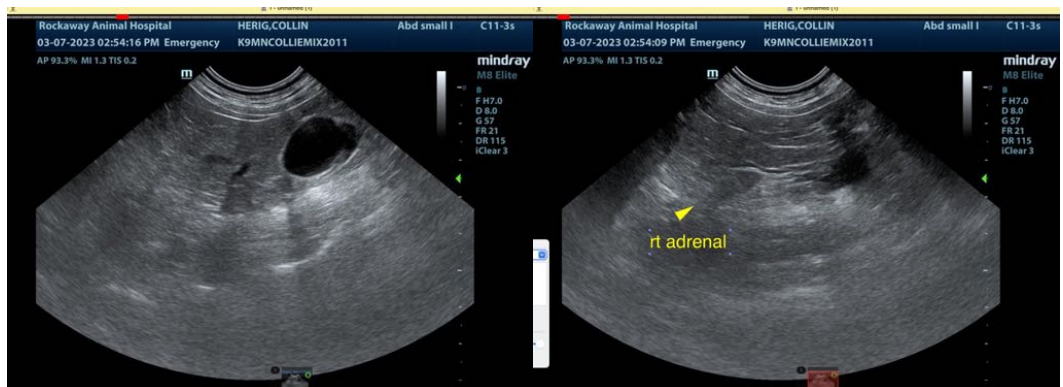
Jenn

HOSPITAL NAME

Rockaway AH

REFERRING VET

Dr. Maniar



INVOICE

43154

DATE

3/7/23



PATIENT

Collin Herig

SPECIES

Canine

BREED

Collie Mix

SEX

Neutered male

AGE

11 years

WEIGHT

30 lbs

INTERPRETED BY

Eric Lindquist, DMV
DABVP, Cert. IVUS

IMAGING PERFORMED BY

Jenn

HOSPITAL NAME

Rockaway AH

REFERRING VET

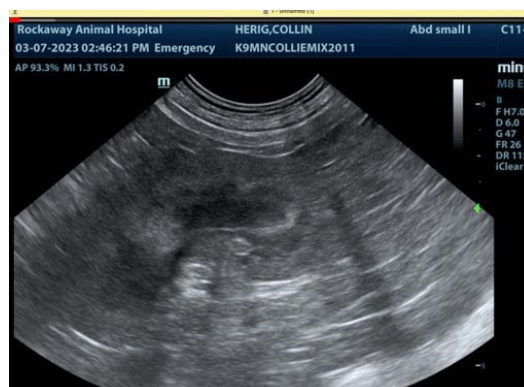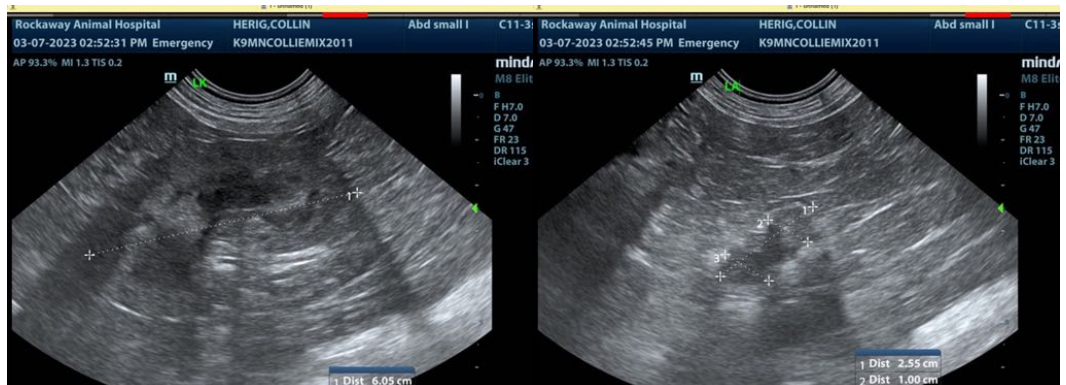
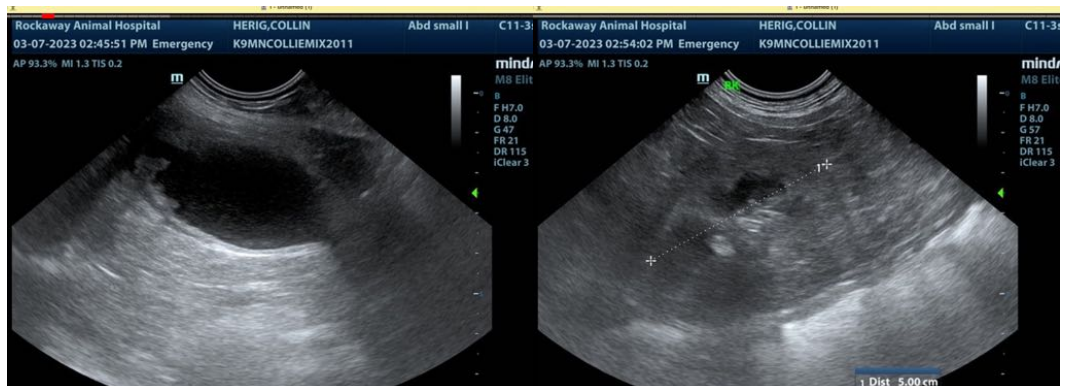
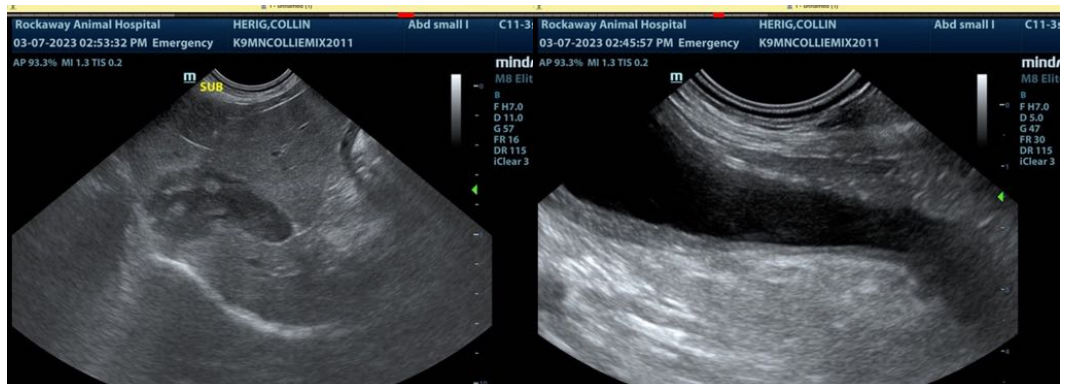
Dr. Maniar

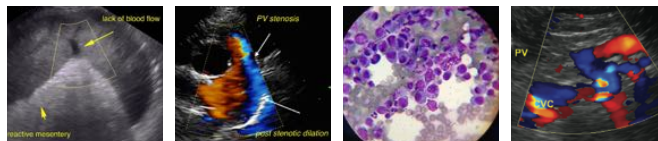
INVOICE

43154

DATE

3/7/23





PATIENT

Collin Herig

The information and recommendations provided are based on the images presented by the referring veterinarian/sonographer. No evaluation can be communicated regarding pathology that was not visible in the image/video clips provided.

SPECIES

Canine

Thank you for this referral. If the clinical or image interpretation does not parallel your findings or if I can be of any further assistance please contact me.

BREED

Collie Mix

Eric Lindquist, DMV, DABVP, Cert. IVUSS, CEO of SonoPath.com
info@SonoPath.com

SEX

Neutered male

AGE

11 years

WEIGHT

30 lbs

INTERPRETED BY

Eric Lindquist, DMV
DABVP, Cert. IVUSS

**IMAGING
PERFORMED BY**

Jenn

HOSPITAL NAME

Rockaway AH

REFERRING VET

Dr. Maniar

INVOICE

43154

DATE

3/7/23