



**PATIENT PRESENTING CLINICAL SIGNS**

Chloe McDougale/Binger

History: Had echo in fall. Since then has been asymptomatic and not on any meds

**SPECIES ULTRASONOGRAPHIC EXAMINATION OF THE HEART**

Canine

The echocardiogram in this patient presented normal volume in the left atrium and left ventricle with a prominent right atrium and right ventricle. There was no significant valvular disease was present. The contractility appeared adequate. The pericardial and pleural spaces were unremarkable. The outflow velocities were unremarkable. There was no evidence of hepatic vein dilation.

**BREED**

Shepherd Mix

**SEX**

Spayed female

**AGE**

11 years

**WEIGHT**

44 lbs

CANINE CARDIAC PARAMETERS	MR VMAX (m/s)	TR VMAX (m/s)	LA/AO (Boon method)	LA/AO (Heart Base;)	FS (%)	EF (%)	EPSS (cm)
NORMAL PARAMETER	4.5-5.5	<2.7	1.3	<1.6	28-40	40-100	<0.6
PATIENT			1.29	1.65	32	61	0.1
CANINE CARDIAC PARAMETERS	HR (BPM)	AV VMAX (m/s)	PV MAX (m/s)	BODY WEIGHT	LA (2D short axis Base view) (cm)	LVIDd (Avg; 2D and m-mode short axis) (cm)	LVIDs (Avg; 2D and m-mode short axis) (cm)
NORMAL PARAMETER	50-100	0.7-1.7	0.7-1.6	BELOW	BELOW	BELOW	BELOW
PATIENT	110		1.1	44 lbs	3.29 max	3.95	

**INTERPRETED BY**

Eric Lindquist, DMV DABVP, Cert. IVUSS

**IMAGING PERFORMED BY**

Dr. Gunther

**HOSPITAL NAME**

New Frontier AMC

**REFERRING VET**

Dr. Gunther

**INVOICE**

43163

**DATE**

3/7/23

**ULTRASONOGRAPHIC FINDINGS**

Prominent right heart, stable, possible confirmational issue or cor pulmonale.

**INTERPRETATION OF THE FINDINGS & FURTHER RECOMMENDATIONS**

There was no evidence of functional disease. No therapy is recommended.



**PATIENT**

Chloe  
McDougle/Binger

**SPECIES**

Canine

**BREED**

Shepherd Mix

**SEX**

Spayed female

**AGE**

11 years

**WEIGHT**

44 lbs

**INTERPRETED BY**

Eric Lindquist, DMV  
DABVP, Cert. IVUSS

**IMAGING PERFORMED BY**

Dr. Gunther

**HOSPITAL NAME**

New Frontier AMC

**REFERRING VET**

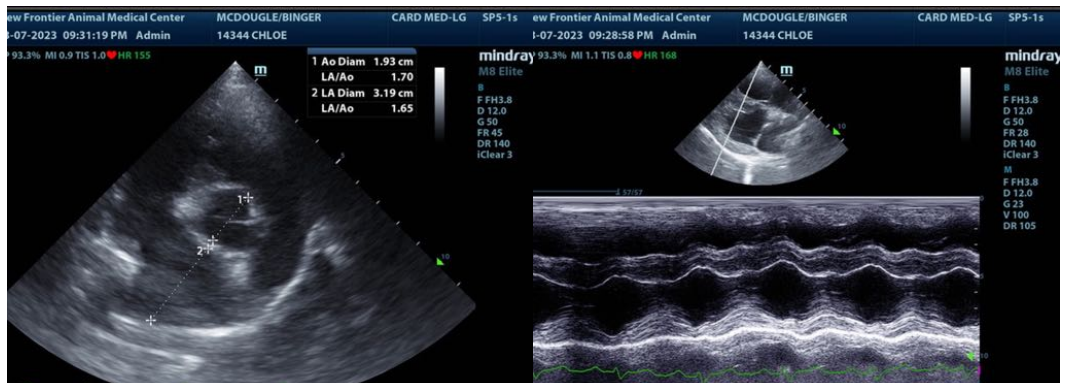
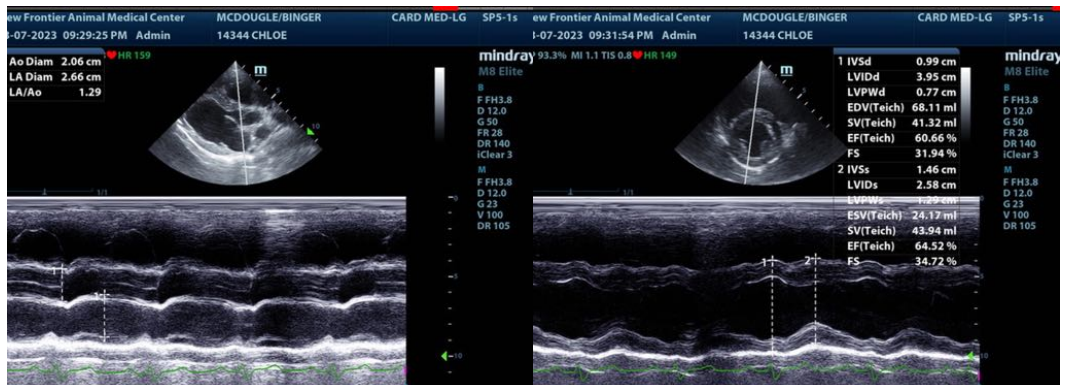
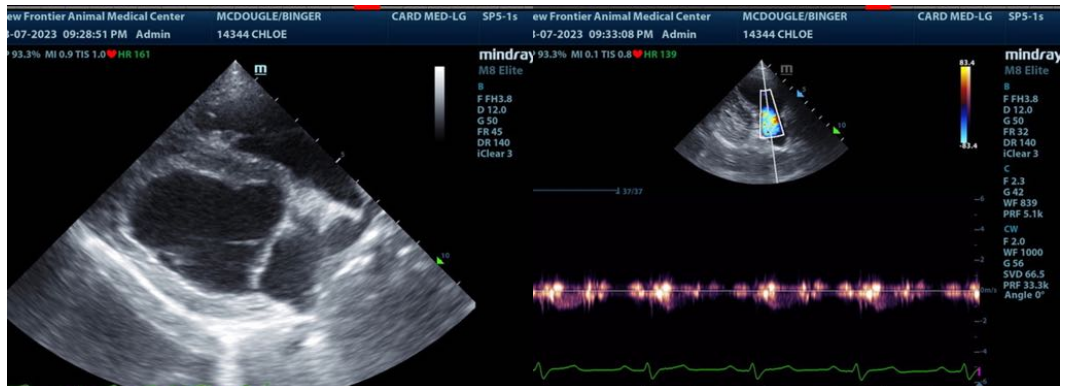
Dr. Gunther

**INVOICE**

43163

**DATE**

3/7/23



The information and recommendations provided are based on the images presented by the referring veterinarian/sonographer. No evaluation can be communicated regarding pathology that was not visible in the image/video clips provided.

Thank you for this referral. If the clinical or image interpretation does not parallel your findings or if I can be of any further assistance please contact me.

**Eric Lindquist, DMV, DABVP, Cert. IVUSS, CEO of SonoPath.com**  
info@SonoPath.com