



PATIENT

Bear Blye

SPECIES

Canine

BREED

Aussie Mix

SEX

MN

AGE

7yr

WEIGHT

71

INTERPRETED BY

Eric Lindquist, DMV
DABVP, Cert. IVUSS

IMAGING PERFORMED BY

Carter

HOSPITAL NAME

Willamette Veterinary
Hospital

REFERRING VET

Carter

INVOICE

13135ag

DATE

03/07/2023

PRESENTING CLINICAL SIGNS

Lethargy, inappetence, intermittent vomiting for last 3-4 weeks. Wt loss , 8% of body wt in 3 weeks

Abnormal PE/Chem/CBC/UA Results: Labs 4 months ago, were within normal limits USG 1.015 creatinine 9.2 BUN 60 phos 7.2 albumin 2.2 urine culture, lepto test pending

LIMITED ULTRASONOGRAPHIC EXAMINATION OF THE URINARY TRACT

Urinary System

The urinary bladder, trigone, and pelvic urethra presented normal thicknesses and normal tone. The ureters were not visible which is normal. No uroliths or sediment were visualized, and anechoic urine was present. No evidence of inflammatory or neoplastic changes were noted. Ureteral papillae were normal.

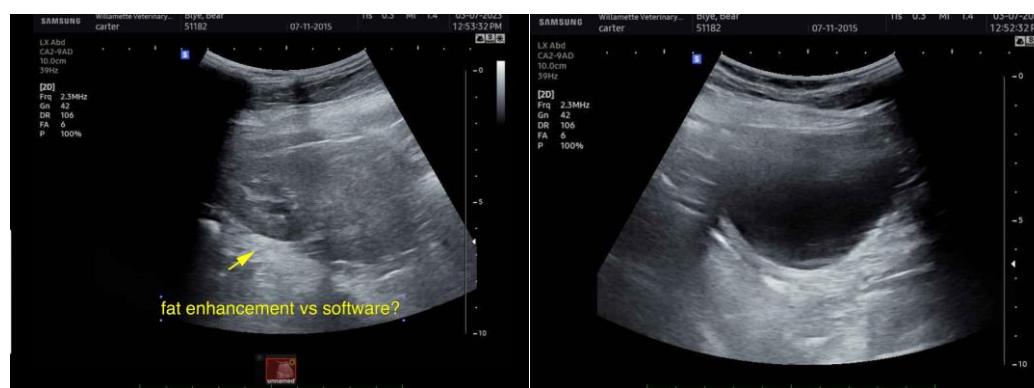
The kidneys revealed normal size and structure, corticomedullary definition and ratio for this age. The cortices presented largely uniform texture with normal echogenic relationship to liver and spleen. Medullary structure differed distinctly from the cortex and no evidence of pelvic dilation was present. The capsules were acceptably uniform without significant irregularities. The left kidney measured 7.26 cm in length. The right kidney measured 6.95 cm in length.

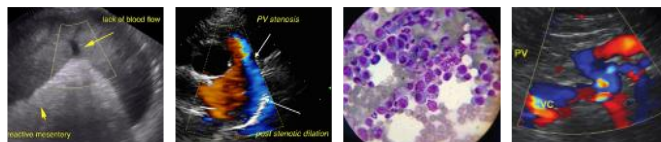
ULTRASONOGRAPHIC FINDINGS

- Structurally unremarkable urinary tract and kidneys

INTERPRETATION OF THE FINDINGS & FURTHER RECOMMENDATIONS

Acute kidney insult suspected. Correlation with pending Lepto recommended. Screening for Addison's disease warranted. Possible hyperechoic inflammatory pattern around the left kidney however this cannot be differentiated from software artifact. Treatment for acute renal failure recommended.





PATIENT

Bear Blye

SPECIES

Canine

BREED

Aussie Mix

SEX

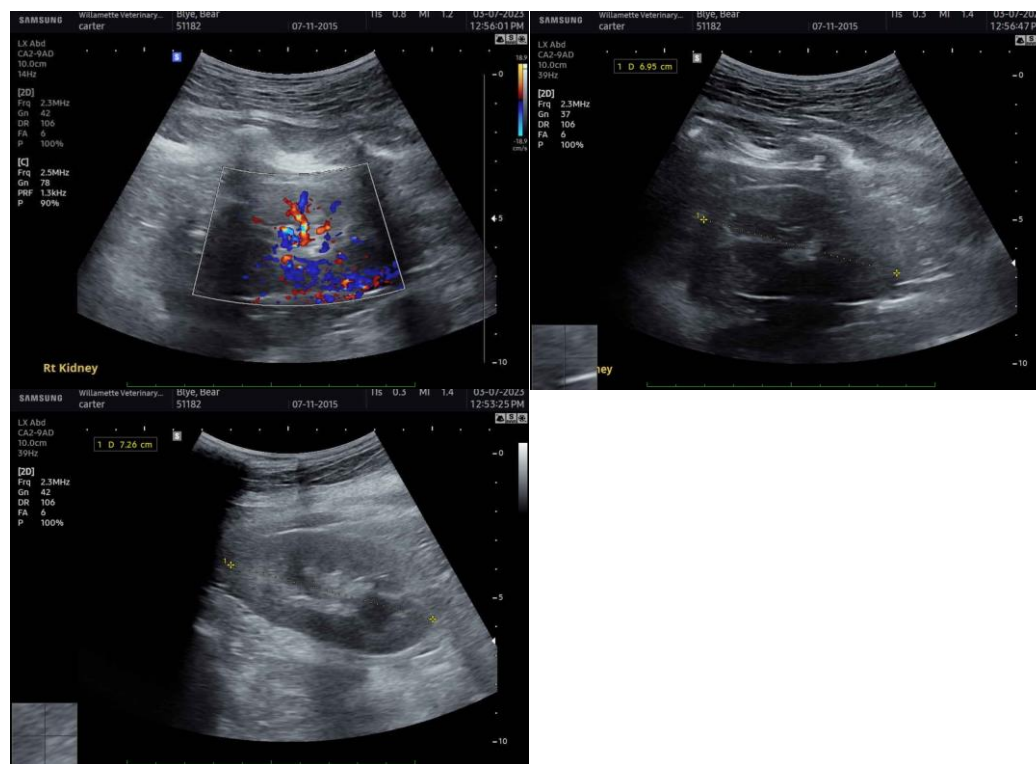
MN

AGE

7yr

WEIGHT

71



INTERPRETED BY

Eric Lindquist, DMV
DABVP, Cert. IVUSS

IMAGING PERFORMED BY

Carter

HOSPITAL NAME

Willamette Veterinary
Hospital

REFERRING VET

Carter

INVOICE

13135ag

DATE

03/07/2023

The information and recommendations provided are based on the images presented by the referring veterinarian/sonographer. No evaluation can be communicated regarding pathology that was not visible in the image/video clips provided.

Thank you for this referral. If the clinical or image interpretation does not parallel your findings or if I can be of any further assistance, please contact me.

Eric Lindquist, DMV, DABVP, Cert. IVUSS, CEO of SonoPath.com
Eric.Lindquist@SonoPath.com