



PATIENT

Voltaire Genung

SPECIES

Feline

BREED

DSH

SEX

Neutered Male

AGE

4 Years

WEIGHT

18 Pounds

PRESENTING CLINICAL SIGNS

History: Heard raspy lung type noises during dental. Pulmonary edema noted on rads intra-op (dental). All other monitoring parameters wnl. Current meds given today: Pre-op: Methadone 0.1mg/kg, induction: Ket/Midaz maintained on Iso. 1pm Dexdomitor 0.01ml IV given (rescue dose for rough recovery). Lasix also given post rads.

ULTRASONOGRAPHIC EXAMINATION OF THE HEART

FELINE CARDIAC PARAMETERS	BODY WEIGHT (kg)	HR (BPM)	IVSd (cm)	LVIDd (cm)	LVWd (cm)	FS (%)	EF (%)
NORMAL PARAMETER	-----	150-240	0.3-0.6	1.0-2.1	0.25-0.6	35-67	80-100
PATIENT	--	NM	0.37	1.92	0.36	32	64
FELINE CARDIAC PARAMETERS	LA/AO (Boon)	LA/AO HEART BASE (Sisson)	LA 2D 4-chamber long axis AS to FW (Sisson) (cm)	LVOT VEL. (m/s)	RVOT VEL. (m/s)	IVRT (m/)	
NORMAL PARAMETER	<1.5	0.88-1.79	0.7-1.7	<1.6	<1.3	40-60	
PATIENT	1.28	1.28	1.8	--	.70	NM	
Adapted from June Boon, Veterinary Echocardiography, 1998 Sisson D et al. JVIM 1991; 5: 232, Jacobs et al. Am J Vet Res 1985; 46:1705							

INTERPRETED BY

Eric Lindquist, DMV
DABVP, Cert. IVUSS

IMAGING PERFORMED BY

Shari Reffi, CVT

HOSPITAL NAME

ACC Flanders

REFERRING VET

Dr. Casulli

INVOICE

14215

DATE

3/7/22

Cardiac Presentation

The LA max is the upper limits of normal yet likely normal for this patient. The cranial and caudal **mitral** valve leaflets presented normal linear structure and kinetics. The **left ventricle** presented normal thicknesses with linear contour and was not dilated nor restricted. The **myocardium** presented normal echogenicity without subjective evidence of significant fibrotic or ischemic disease. **Contractility** of the ventricular walls was adequate and in normal range for this patient evidenced by the fractional shortening measurement and subjective evaluation of the different regions and angles of the myocardium. The **left ventricular outflow** tract demonstrated normal laminar flow and subjective structural integrity. The **right atrium** and auricle revealed normal size, structure and content. No evidence of masses was noted or chamber overload. **Tricuspid** valvular assessment demonstrated adequate linear morphology and kinetics. The **right ventricle** was of normal size (1/3 diameter of LV), chordae structure, myocardial echogenicity and thickness. **Pulmonic** tract assessment revealed normal valve structure, laminar flow, and diameter (approx.1:1 pa/ao ratio). No visible **pericardial** or free pleura fluid was noted or extra cardiac pathology in the visible planes. The cranial **mediastinum and pericardial regions** were free of masses in the visible window.

ULTRASONOGRAPHIC FINDINGS

- Normal echocardiogram
- The LA max is upper limits of normal yet likely normal for this patient.

INTERPRETATION OF THE FINDINGS & FURTHER RECOMMENDATIONS



PATIENT

No evidence of primary cardiac disease. Temporary cardiac episode could have occurred during anesthetic procedure, however, no residual disease noted. No specific therapy warranted.

Voltaire Genung

SPECIES

Feline

BREED

DSH

SEX

Neutered Male

AGE

4 Years

WEIGHT

18 Pounds

INTERPRETED BY

Eric Lindquist, DMV
DABVP, Cert. IVUSS

IMAGING PERFORMED BY

Shari Reffi, CVT

HOSPITAL NAME

ACC Flanders

REFERRING VET

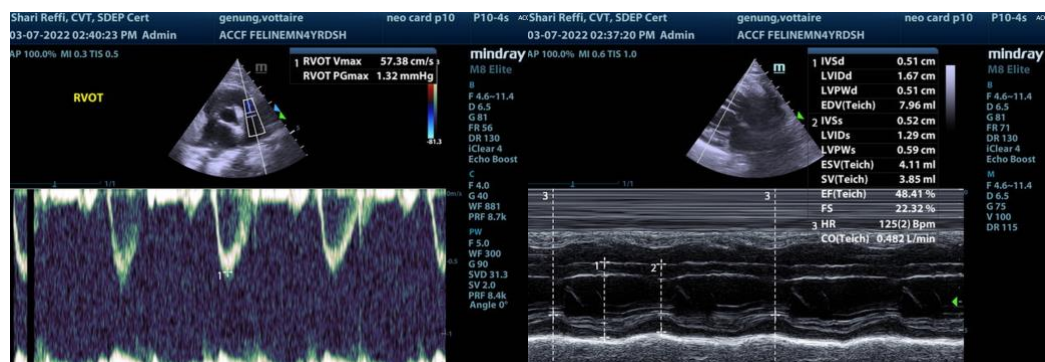
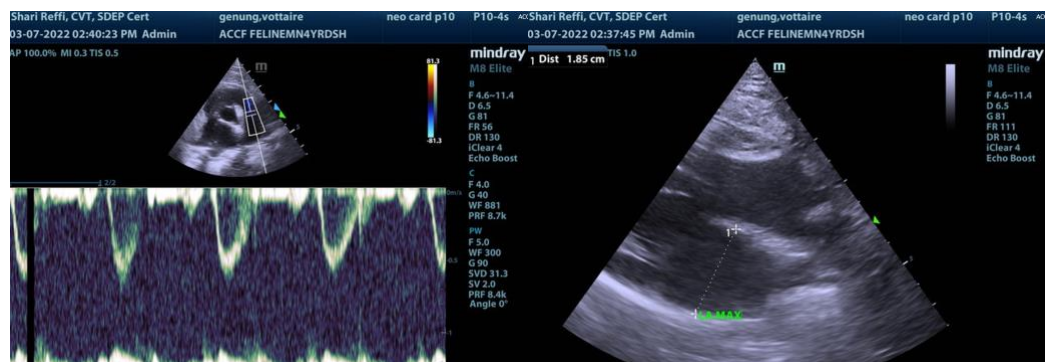
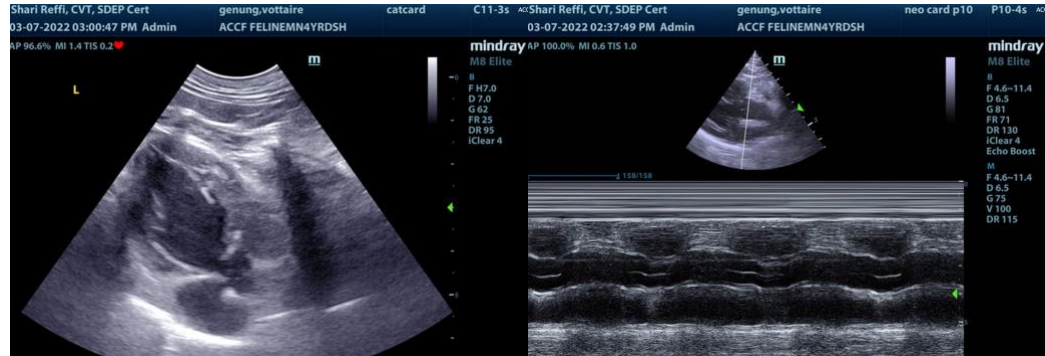
Dr. Casulli

INVOICE

14215

DATE

3/7/22





PATIENT

Voltaire Genung

SPECIES

Feline

BREED

DSH

SEX

Neutered Male

AGE

4 Years

WEIGHT

18 Pounds

INTERPRETED BY

Eric Lindquist, DMV
DABVP, Cert. IVUSS

IMAGING PERFORMED BY

Shari Reffi, CVT

HOSPITAL NAME

ACC Flanders

REFERRING VET

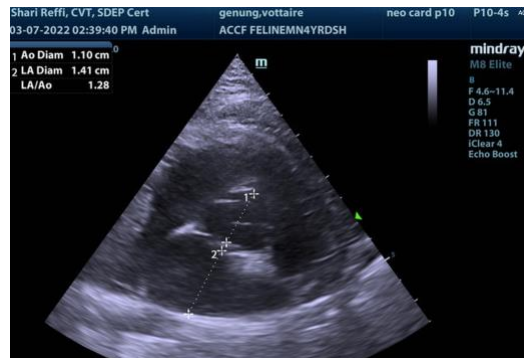
Dr. Casulli

INVOICE

14215

DATE

3/7/22



The information and recommendations provided are based on the images presented by the referring veterinarian. No evaluation can be communicated regarding pathology that was not visible in the image/video clips provided.

Thank you for this referral. If the clinical or image interpretation does not parallel your findings or if I can be of any further assistance please contact me.

Eric Lindquist, DMV, DABVP, Cert. IVUSS, CEO of SonoPath.com
info@SonoPath.com