



PATIENT

Pumpkin Nusspickel

PRESENTING CLINICAL SIGNS

History: Patient presents for GI issues, history of chronic, intermittent vomiting.

SPECIES

Feline

ULTRASONOGRAPHIC EXAMINATION OF THE ABDOMEN

Urinary System

BREED

Domestic Shorthair

The **urinary bladder**, trigone, and pelvic urethra presented normal thicknesses and normal tone. The ureters were not visible which is normal. No uroliths or sediment were visualized and anechoic urine was present. No evidence of inflammatory or neoplastic changes was noted. Ureteral papillae were normal.

SEX

Neutered male

The **kidneys** presented a relatively uniform cortical hyperechogenicity when compared to the renal medulla, spleen and liver. No overt masses were noted. Corticomedullary definition was nebulous and the ratio favored the cortex slightly. The ureters were not visible and assumed to be normal. These changes are most consistent with chronic interstitial nephritis yet infiltrative disease could not be entirely ruled out without biopsy though neoplasia is not suspected. The right kidney measured 3.8 cm. The left kidney measured 4.02 cm.

AGE

12 years

WEIGHT

16.05 lbs

Adrenal Glands

Both **adrenal glands** were visualized and recognized as having normal shape, size, position and echogenicity for this breed. The phrenic vasculature, glandular echogenicity and detail were unremarkable. Capsule, cortex, and medullary definition were normal for this age patient. The left adrenal gland measured 0.29 cm. The right adrenal gland measured 0.33 cm.

INTERPRETED BY

Eric Lindquist, DMV,
DABVP, Cert. IVUSS,
CEO of SonoPath.com

Spleen

The **spleen** presented a smooth homogeneous parenchyma hyperechoic to liver and renal cortical parenchyma. The capsule was smooth without noticeable expansion or deviation from within the spleen or adjacent pathology. The splenic vasculature demonstrated normal volume without signs of congestion or thrombosis. No sonographic evidence of acute or chronic inflammatory, neoplastic, or infarctual changes was noted. The spleen measured 0.69 cm.

IMAGING PERFORMED BY

Kelly Vazquez, CVT

HOSPITAL NAME

Animal Paradise
Hospital

Liver

The **liver** images submitted revealed subjectively normal liver size, contour, and structure. Parenchymal echogenicity was naturally coarse and hypoechoic to the spleen. Vascular and biliary tracts were of normal volume with no evidence of congestion. The gallbladder presented acceptably thin walls with primarily anechoic content. The cystic and common bile ducts were normal. No pathological hepatic lymphadenopathy was evident. No overt structural evidence of inflammatory, infiltrative or regenerative pathology was evident.

REFERRING VET

Dr. ElShafie

INVOICE

96581

DATE

3/7/22



PATIENT

Pumpkin Nusspickel

Gastrointestinal

The **pylorus** and pyloric outflow was mildly thickened with muscularis hypertrophy. The small intestine and colon were unremarkable with normal curvilinear patterns.

SPECIES

Feline

Pancreas

The base and limbs of the **pancreas** were observed to be largely isoechoic to surrounding omental fat. Some parenchymal remodeling, however, with mild deviation from curvilinear normalcy was observed. Pancreatic duct and capsular irregularities were present consistent with age related changes. If pain upon imaging (+ Murphy sign) was present or if the patient is focally painful in subxiphoid palpation then low-grade smoldering chronic pancreatitis should be suspected.

BREED

Domestic Shorthair

SEX

Neutered male

ULTRASONOGRAPHIC FINDINGS

Pancreatic remodeling.

AGE

12 years

Chronic interstitial nephrosis renal pattern.

Mild gastritis pattern.

WEIGHT

16.05 lbs

INTERPRETATION OF THE FINDINGS & FURTHER RECOMMENDATIONS

The gastric lumen was empty with no evidence of hairballs. A clinical trial of the following may prove effective. Zithromax and Metronidazole is recommended over a 7 day period with a hydrolyzed diet. I recommend reassessment of the clinical signs. Anti-parasitic protocol is indicated if not already performed.

INTERPRETED BY

Eric Lindquist, DMV,
DABVP, Cert. IVUSS,
CEO of SonoPath.com

IMAGING PERFORMED BY

Kelly Vazquez, CVT

HOSPITAL NAME

Animal Paradise
Hospital

REFERRING VET

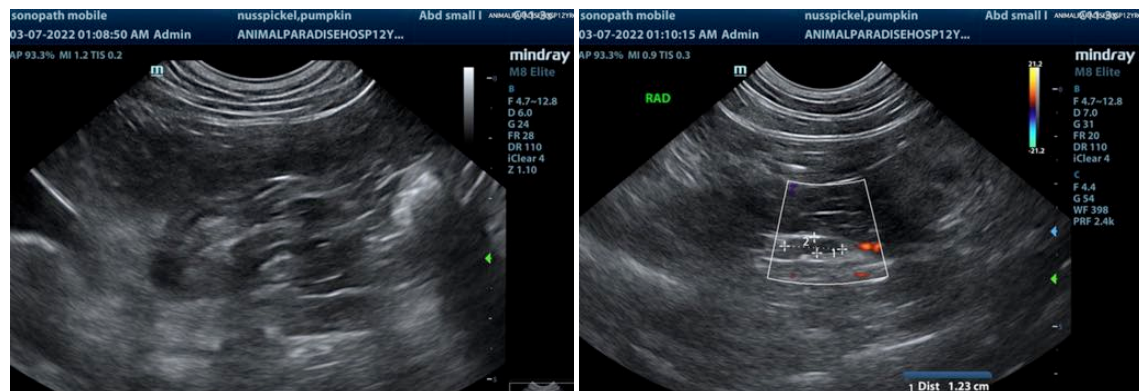
Dr. ElShafie

INVOICE

96581

DATE

3/7/22





PATIENT

Pumpkin Nusspickel

SPECIES

Feline

BREED

Domestic Shorthair

SEX

Neutered male

AGE

12 years

WEIGHT

16.05 lbs

INTERPRETED BY

Eric Lindquist, DMV,
DABVP, Cert. IVUSS,
CEO of SonoPath.com

IMAGING PERFORMED BY

Kelly Vazquez, CVT

HOSPITAL NAME

Animal Paradise
Hospital

REFERRING VET

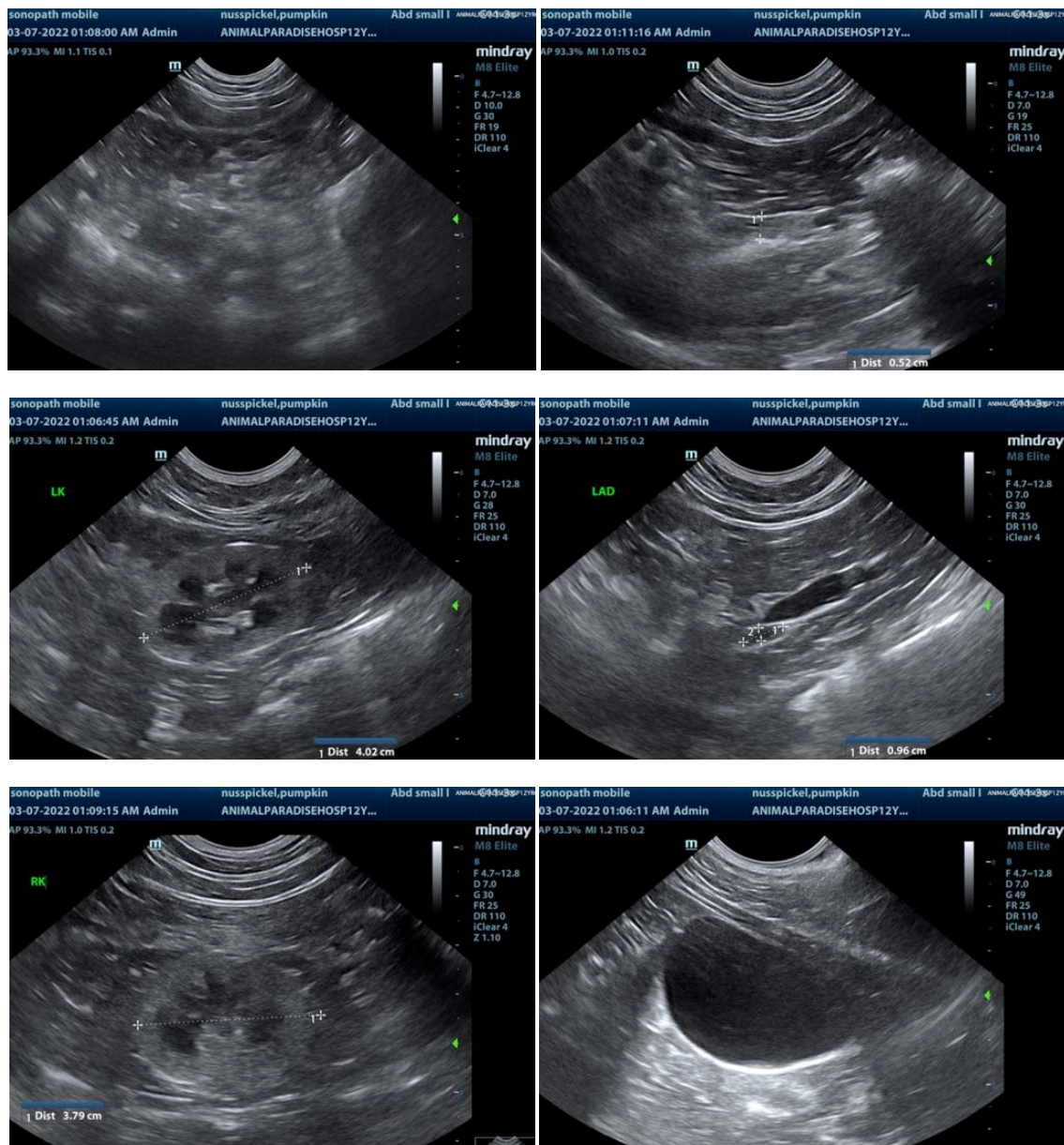
Dr. ElShafie

INVOICE

96581

DATE

3/7/22



The information and recommendations provided are based on the images presented by the referring veterinarian/sonographer. No evaluation can be communicated regarding pathology that was not visible in the image/video clips provided.

Thank you for this referral. If the clinical or image interpretation does not parallel your findings or if I can be of any further assistance please contact me.

Eric Lindquist, DMV, DABVP, Cert. IVUSS, CEO of SonoPath.com

Info@SonoPath.com