

**DATE**

3/7/22

PRESENTING CLINICAL SIGNS

History of acute vomiting and anorexia January 2022. Lab work showed liver value elevations, pet Lepto snapped positive, although previously vaccinated in March of 2021. No titers submitted. Hospitalized for approximately 3 days improved and sent home with antibiotics for leptospirosis. Approximately 1 week after finished antibiotics, flare up of GI upset. Presented 3/4/22: repeat lab work showed worsening liver disease. Hospitalized through weekend for ultrasound.

PATIENT

Prince Howachyn

SPECIES

Canine

BREED

Mix

SEX

Neutered Male

AGE

8/12/17

WEIGHT

56.4 Pounds

INTERPRETED BYEric Lindquist, DMV
DABVP, Cert. IVUSS**HOSPITAL NAME**

Everhart VH

REFERRING VET

Dr. Notarangelo

INVOICE

14199

Current Medications: 1/19/22- 3 weeks of Doxycycline 100mg BID, 2 weeks of Clavamox 375mg BID, recent hospitalization starting 3/4/22: Metronidazole 380mg IV bid, Ampicillin 500mg IV BID, Cerenia 25mg SID.

Lab Results: Significant liver disease. 3/4/22: ALT not registering, ALKP 375, Tbili 1.6. 2/24/22 ALT 278. 1/28/22: ALT 393. 1/18/22: ALT 705, Tbili 0.5.

Date of Previous IntraPet Ultrasound: No previous.

Sedation: Not required to complete full diagnostic ultrasound.

Stat Report: STAT report request.

Imaging Performed By: Andi Parkinson, RDMS

ULTRASONOGRAPHIC EXAMINATION OF THE ABDOMEN**Urinary System**

The **urinary bladder**, trigone, and pelvic urethra presented normal thicknesses and normal tone. The ureters were not visible which is normal. No uroliths or sediment were visualized, and anechoic urine was present. No evidence of inflammatory or neoplastic changes were noted. Ureteral papillae were normal.

The **kidneys** revealed normal size and structure, corticomedullary definition and ratio for this age. The cortices presented largely uniform texture with normal echogenic relationship to liver and spleen. Medullary structure differed distinctly from the cortex and no evidence of pelvic dilation was present. The capsules were acceptably uniform without significant irregularities. The right kidney measured 6.07 cm. The left kidney measured 6.23 cm.

Adrenal Glands

Both **adrenal glands** were visualized and recognized as having normal shape, size, position and echogenicity for this breed. The phrenic vasculature, glandular echogenicity and detail were unremarkable. Capsule, cortex, and medullary definition were normal for this age patient. The right adrenal gland measured 2.46 cm x 0.84 cm at the caudal pole and 0.78 cm at the cranial pole. The left adrenal gland measured 2.44 cm x 0.65 cm at the caudal pole and 0.63 cm at the cranial pole.

Spleen

The **spleen** revealed slightly heterogeneous parenchyma, uniform. The spleen was relatively normal in size.

Liver

The **liver** revealed mild coarse architecture and increased portal markings, consistent with cholangitis. The liver presented undulating contour. The gallbladder was slightly thickened without overdistention. A minor amount of excessive debris noted.

Gastrointestinal

Examination of the **gastrointestinal tract** revealed a stomach and intestine free of stasis, of normal wall thickness, acceptable curvilinear mural detail, and peristaltic activity. Small and large intestine demonstrated normal luminal chyme and stool consistency respectively. No obstructive or overt infiltrative disease was noted. No associated abnormal lymphatic activity was noted.

Pancreas

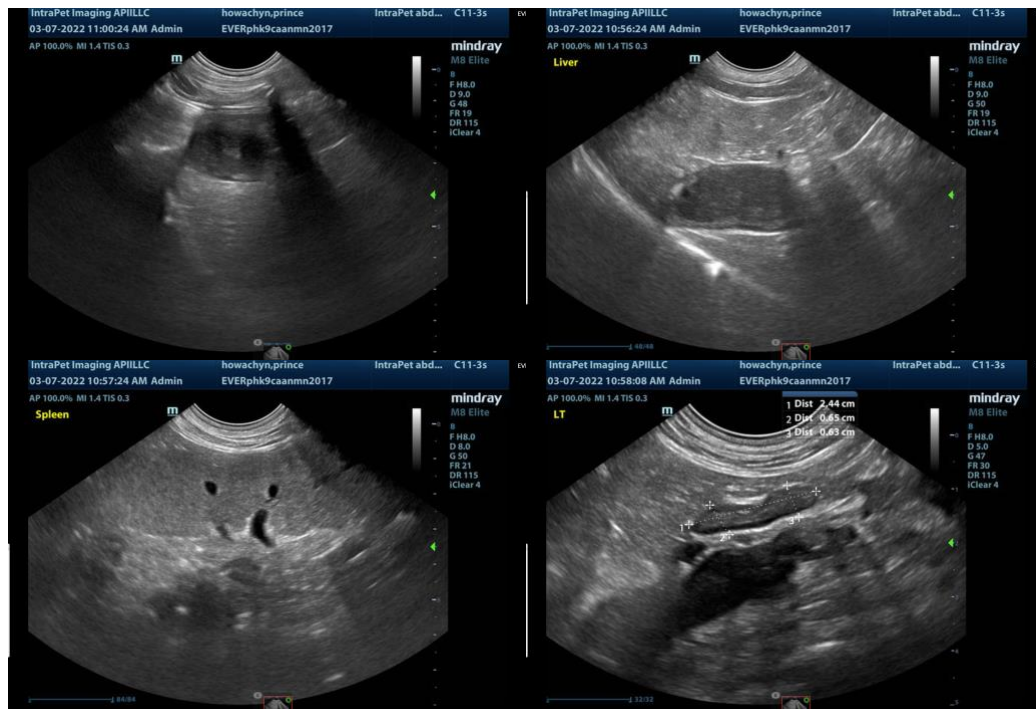
The base and limbs of the **pancreas** were observed to be largely isoechoic to surrounding omental fat. Pancreatic duct and capsular contour were acceptably normal and parenchyma respected normal curvilinear patterns. No overt evidence of active inflammatory or neoplastic disease was noted.

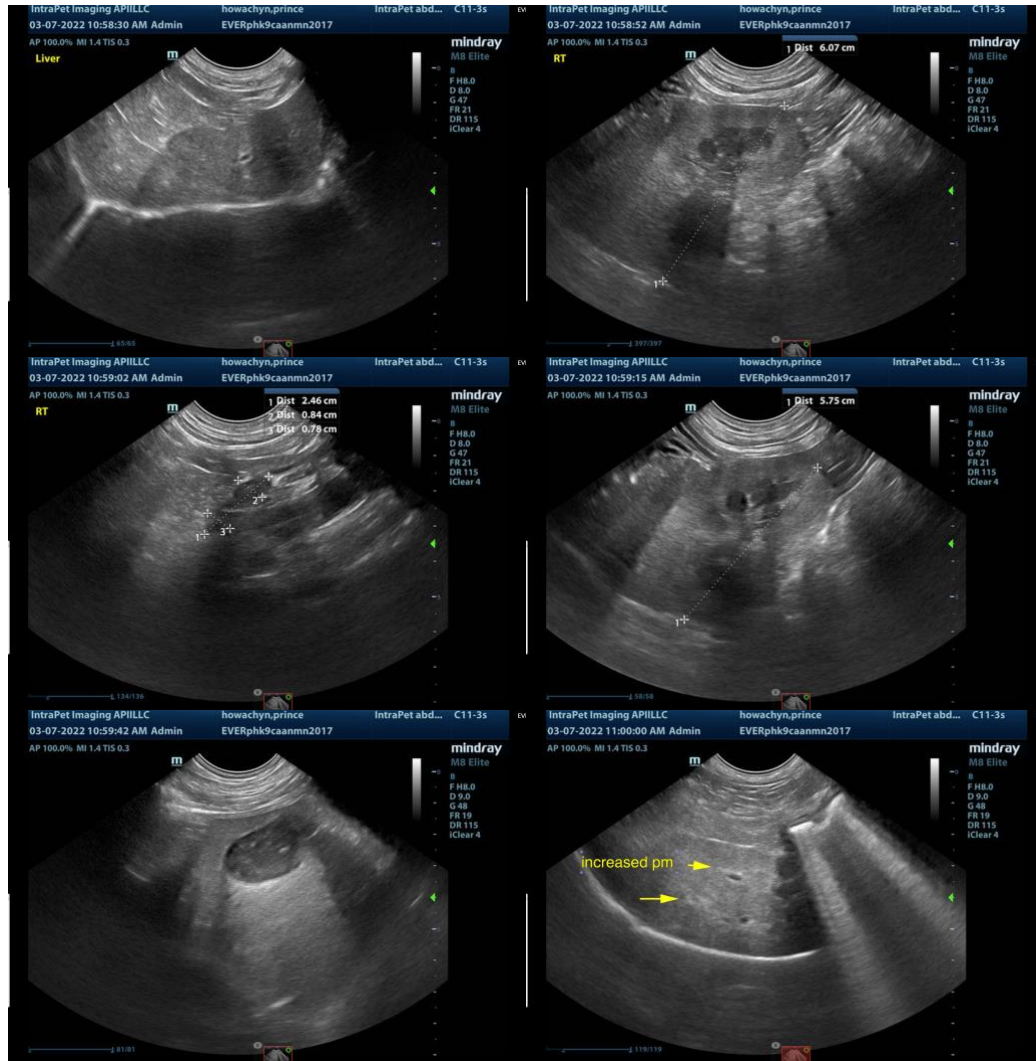
ULTRASONOGRAPHIC FINDINGS

- Nonspecific acute on chronic cholangiohepatitis pattern
- Slightly heterogeneous spleen

INTERPRETATION OF THE FINDINGS & FURTHER RECOMMENDATIONS

Remodeling of the liver is considered mild at this point. However, it is important to definitively diagnosis the parenchymal disease in this patient for long-term management. Core liver biopsy warranted. Leptospirosis titers indicated, if not already performed. Liver parenchymal culture would be ideal as well. Other forms of toxin should also be considered. Coagulation panel warranted prior to sampling of the liver. FNA of the liver could be considered, however, it would not be able to differentiate potential copper storage issue.





The information and recommendations provided are based on the images presented by the referring veterinarian. No evaluation can be communicated regarding pathology that was not visible in the image/video clips provided.

Thank you for this referral. If the clinical or image interpretation does not parallel your findings or if I can be of any further assistance please contact me.

Eric Lindquist, DMV, DABVP, Cert. IVUSS, CEO of SonoPath.com
 Eric.Lindquist@SonoPath.com