



PATIENT

Louie Romero

PRESENTING CLINICAL SIGNS

History: vomiting, lethargic, ATH for IVF and Ursodiol, Metronidazole, Cerenia, Ampicillin
Positive Murphy's sign in the cranial abdomen during ultrasound exam.
Abnormal PE/Chem/CBC/UA Results: elevate ALT, ALP, GGT, TBil, Neutrophilia, USG 1.052

SPECIES

Canine

ULTRASONOGRAPHIC EXAMINATION OF THE ABDOMEN

Urinary System

The **urinary bladder**, trigone, and pelvic urethra presented normal thicknesses and normal tone. The pelvic urethra was imaged 2.0 cm beyond the cystourethral junction. The ureters were not visible which is normal. No uroliths or sediment were visualized and anechoic urine was present. No evidence of inflammatory or neoplastic changes was noted. Ureteral papillae were normal.

BREED

Terrier Mix

SEX

Neutered male

The **kidneys** revealed largely normal size and structure, corticomedullary definition and ratio (cortex 1/3 of medulla) were essentially maintained with some age-related loss of curvilinear patterns regarding the capsule and C/M junction. The cortices presented largely uniform texture with some increased echogenicity expected for this age patient. Medullary structure differed distinctly from that of the cortex and no evidence of pelvic dilation was present. The right kidney measured 6.2 cm. The left kidney measured 5.34 cm.

AGE

13 years

WEIGHT

19.6 lbs

Adrenal Glands

Both **adrenal glands** were visualized and recognized as having normal shape, size, position and echogenicity for this breed. The phrenic vasculature, glandular echogenicity and detail were unremarkable. Capsule, cortex, and medullary definition were normal for this age patient. The left adrenal gland measured 0.65 cm in width. The right adrenal gland measured 0.6 cm.

INTERPRETED BY

Eric Lindquist, DMV
DABVP, Cert. IVUSS

IMAGING PERFORMED BY

Adrienne Ligenza

Spleen

The **spleen** presented a smooth homogeneous parenchyma hyperechoic to liver and renal cortical parenchyma. The capsule was smooth without noticeable expansion or deviation from within the spleen or adjacent pathology. The splenic vasculature demonstrated normal volume without signs of congestion or thrombosis. No sonographic evidence of acute or chronic inflammatory, neoplastic, or infarctual changes was noted.

HOSPITAL NAME

Rush Veterinary
Urgent Care

REFERRING VET

Dr. Milot

Liver

The **liver** was mildly swollen with hypoechoic parenchyma with increased portal markings. The gallbladder presented striating bile. Hyperechoic inflammatory pattern was noted in the neck of the gallbladder. The gallbladder was over distended with an ill defined wall that measured approximately 5.0 cm in long axis. Inflammation was noted at the apex of the gallbladder wall as well with trace amounts of free fluid. The common bile duct was not visualized and should be lavaged at the time of surgery.

INVOICE

96625

DATE

3/8/22



PATIENT

Gastrointestinal

Louie Romero

The **stomach** was filled with ingesta, some of which was shadowing and measured 1.0 cm. This is likely oral medications; however, foreign matter cannot be ruled out. The small intestines and colon were unremarkable.

SPECIES

Canine

Pancreas

BREED

Terrier Mix

The base and limbs of the **pancreas** were observed to be largely isoechoic to surrounding omental fat. Pancreatic duct and capsular contour were acceptably normal and parenchyma respected normal curvilinear patterns. No overt evidence of active inflammatory or neoplastic disease was noted.

SEX

Neutered male

ULTRASONOGRAPHIC FINDINGS

Inflamed gallbladder mucocele.

AGE

13 years

Otherwise, unremarkable abdomen.

Some shadowing oral medication in the stomach.

WEIGHT

19.6 lbs

INTERPRETATION OF THE FINDINGS & FURTHER RECOMMENDATIONS

This is a surgical emergency. Cholecystectomy and common bile duct lavage along with a liver biopsy is all indicated.

INTERPRETED BY

Eric Lindquist, DMV
DABVP, Cert. IVUSS

IMAGING PERFORMED BY

Adrienne Ligenza

HOSPITAL NAME

Rush Veterinary
Urgent Care

REFERRING VET

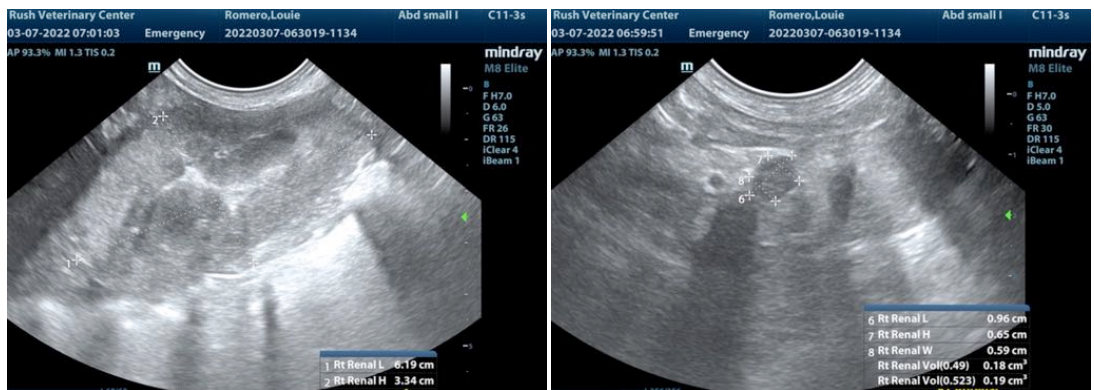
Dr. Milot

INVOICE

96625

DATE

3/8/22





PATIENT

Louie Romero

SPECIES

Canine

BREED

Terrier Mix

SEX

Neutered male

AGE

13 years

WEIGHT

19.6 lbs

INTERPRETED BY

Eric Lindquist, DMV
DABVP, Cert. IVUSS

IMAGING PERFORMED BY

Adrienne Ligenza

HOSPITAL NAME

Rush Veterinary
Urgent Care

REFERRING VET

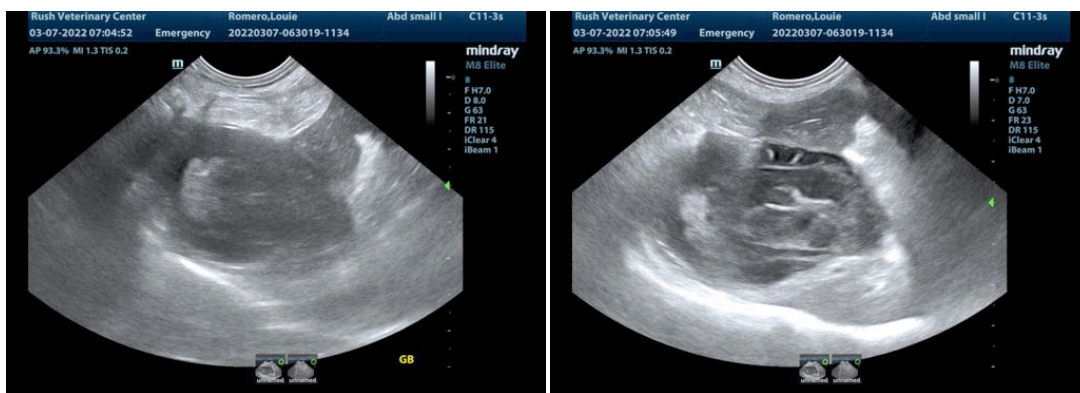
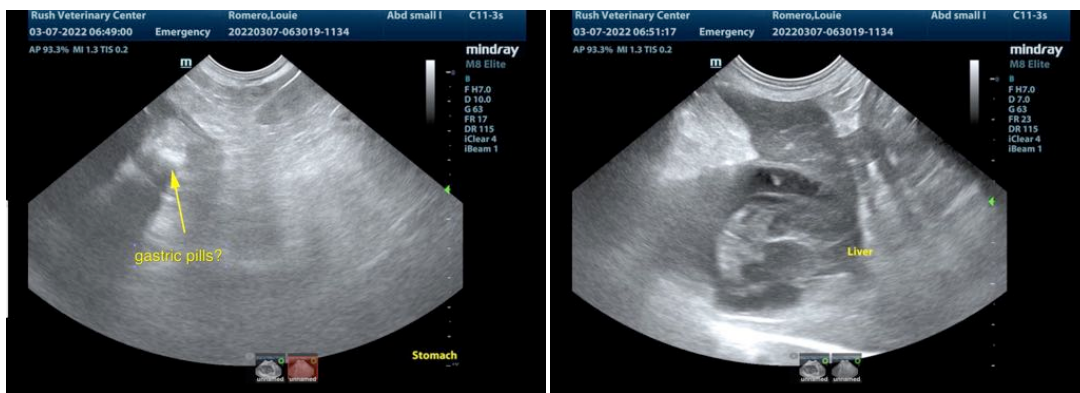
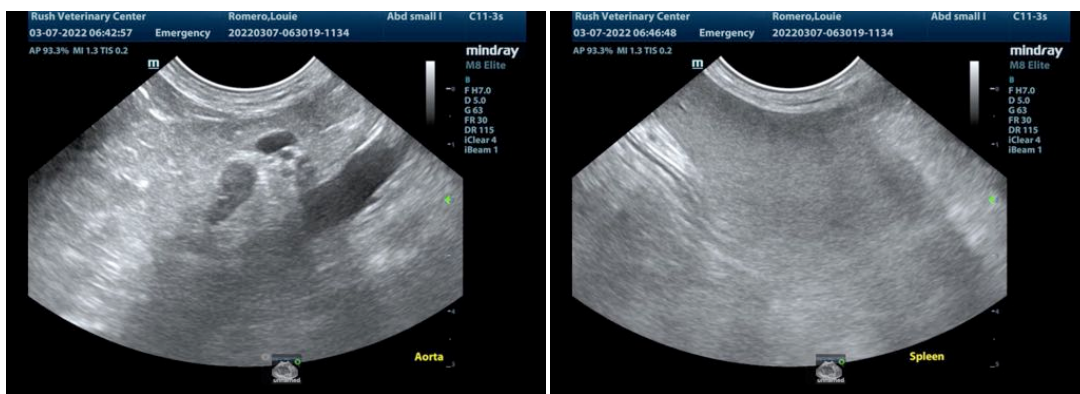
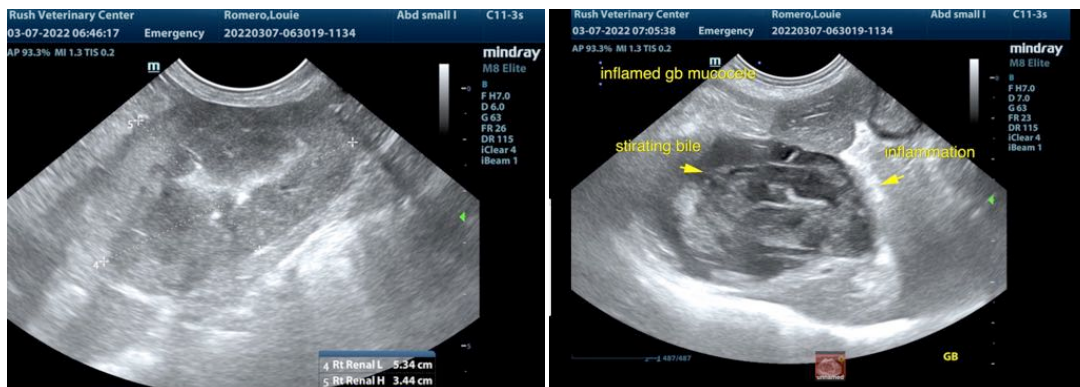
Dr. Milot

INVOICE

96625

DATE

3/8/22





PATIENT

Louie Romero

The information and recommendations provided are based on the images presented by the referring veterinarian/sonographer. No evaluation can be communicated regarding pathology that was not visible in the image/video clips provided.

SPECIES

Canine

Thank you for this referral. If the clinical or image interpretation does not parallel your findings or if I can be of any further assistance please contact me.

BREED


Terrier Mix

Eric Lindquist, DMV, DABVP, Cert. IVUSS, CEO of SonoPath.com

info@SonoPath.com

SEX

Neutered male



The following is an applicable excerpt from the *Curbside Guide to Diagnosis & Treatment of Sonographic Disease* offered by SonoPath.com Lindquist, Frank, Lobetti, and Modler.

An essential quick guide for every general practitioner and sonographer.

<https://sonopath.com/products/curbside-guide-editing-due-release-12012015>

AGE

13 years

Gallbladder Mucoceles

WEIGHT

19.6 lbs

<http://www.sonopath.com/GBMucocele>

<http://www.sonopath.com/GBMucoceleSurvey>

<http://www.sonopath.com/SxBiliaryDisease>

INTERPRETED BY

Eric Lindquist, DMV
DABVP, Cert. IVUSS

IMAGING PERFORMED BY

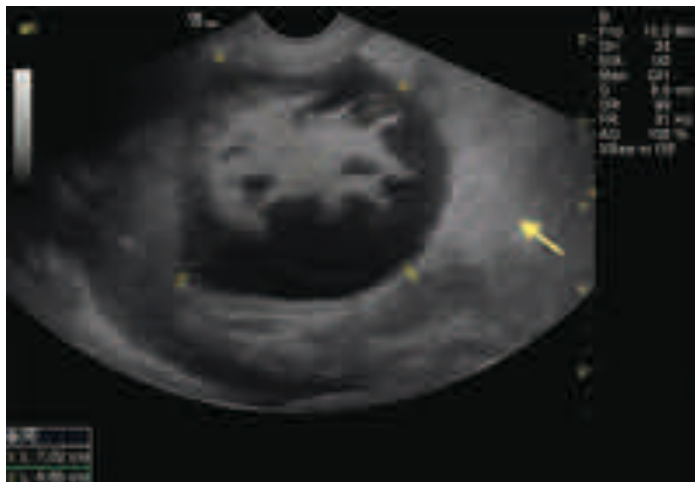
Adrienne Ligenza

HOSPITAL NAME

Rush Veterinary
Urgent Care

REFERRING VET

Dr. Milot



Subxiphoidal short axis of the liver in a dog with a gallbladder mucocele. The gallbladder is severely distended. Note the irregular hyperplasia of the hypoechoic mucosa and the stellate pattern of the echogenic inspissated bile within the center of the gallbladder. Also note the hyperechoic mesentery at the gallbladder neck compatible with bile peritonitis (arrow). This is an example of a typical "kiwi fruit" type mucocele.

INVOICE

96625

DATE

3/8/22

Description: A gallbladder mucocele occurs when the gallbladder becomes overly distended with an excessive accumulation of mucus secondary to cystic mucosal hyperplasia. Previously, pathologists noted this finding at necropsy and considered it an incidental or age-related lesion. In the last decade, however, it has become evident that not all gallbladder mucoceles remain clinically silent and that they can in fact be associated with extrahepatic bile duct obstruction (EHBDO), cholecystitis, and gallbladder wall rupture. Approximately 50% of mucoceles may result in necrosis and rupture, typically at the neck



PATIENT

Louie Romero

SPECIES

Canine

BREED

Terrier Mix

SEX

Neutered male

AGE

13 years

WEIGHT

19.6 lbs

INTERPRETED BY

Eric Lindquist, DMV
DABVP, Cert. IVUS

IMAGING PERFORMED BY

Adrienne Ligenza

HOSPITAL NAME

Rush Veterinary
Urgent Care

REFERRING VET

Dr. Milot

INVOICE

96625

DATE

3/8/22

or fundic region of the gallbladder. The etiology of these mucocèles remains unknown, but researchers suspect that it is related to disordered cholestasis and/or lipid metabolism. Suggested causes include: primary or secondary gallbladder motility disorder; dyslipidemia/hypercholesterolemia; extrahepatic bile duct obstruction; and primary or secondary disorders of mucus-producing cells, such as cystic mucosal hyperplasia of the gallbladder wall. Clinical correlation is also seen with cholangitis, cholecystitis, cholelithiasis, biliary obstruction from cholelithiasis or neoplasia, and pancreatitis. Abnormal adrenal hormones may also play a causal role in altering gallbladder mucus secretion. Hypothyroid dogs are three times more likely to develop a mucocèle, and Cushingoid dogs are twenty-nine times more likely to do so. Vacuolar hepatopathy frequently co-occurs with mucocèles; practitioners are therefore advised to investigate underlying disorders associated with vacuolar hepatopathy. Bacterial infection of the gallbladder has been associated with increased mucin production in dogs; this condition may also become pathological and lead to excessive mucus accumulation. In humans, hypercortisolism is related to chronic cholecystitis and changes the biochemical composition of bile. The latter, however, was not substantiated by two studies evaluating bile composition, bacterial infection, and sludge formation during a three-month period of exogenous administration of hydrocortisone administration in dogs. There is a marked increase in the prevalence of mucocèle formation in dogs with naturally occurring hyperadrenocorticism, but a definitive correlational mechanism has yet not been ascertained.

Mucocèles are most commonly seen in middle-aged to older dogs (median age of 10 years); however, researchers have reported mucocèle development in dogs as young as 3 years old. Certain breeds—Miniature Schnauzers, Shetland Sheepdogs, Cocker Spaniels, Shih-tzus, Pugs, Bichon Frisés, Schipperkes, West Highland White Terriers, and Scottish Terriers—appear to be overrepresented among canine patients. Significant predisposition to mucocèle formation in Shelties prompted an investigation that uncovered a specific genetic mutation in the ABCB4 gene, which functions in the translocation of phosphatidylcholine across hepatocyte cell membranes. In the future, we may be able to screen young Shelties for this mutation, which would allow us to monitor gallbladder mucocèle development with ultrasound over time and thereby offer early dietary and medical management, or even surgical intervention as needed. Felines are less commonly affected.

Clinical Signs: According to several retrospective studies, the most common clinical signs include vomiting (87%), abdominal pain (87%), anorexia (78%), lethargy, icterus (57%), and fever (26%). The average duration of illness is 5 days. Focal pain upon examining the gallbladder is common and referred to as a positive Murphy sign. Patients may also be asymptomatic, despite biochemical abnormalities, even in the face of ultrasonographic evidence of a mucocèle. Patients with fully formed mucocèles are at risk of further complications, such as gallbladder rupture, peritonitis, sepsis, and related coagulopathies, and should be considered for surgical intervention.

Diagnostics: Biochemical analyses may indicate leukocytosis, with or without a left shift, and most commonly reveal elevated hepatic enzymes (SAP 100%, GGT 86%, ALT 77%, AST 60%) and bilirubin (63%). Ultrasonographic findings may include: a distended gallbladder with centrally suspended luminal content and a hypoechoic intraluminal rim; a thickened gallbladder wall; intraluminal stellate; echogenic striations (the “kiwi fruit sign”); and/or the presence of non-dependent intraluminal contents or sludge. (Note: The presence of the “kiwi fruit sign” is not essential for the diagnosis of a gall bladder mucocèle, as many mucocèle variations do not demonstrate a complete stellate pattern.) A hypoechoic ring seen around the gallbladder may indicate wall edema or early rupture. Presence of free fluid, as well as localized, echogenic hepatic parenchyma and intra-abdominal fat, are also consistent with bile leakage and peritonitis. Pain is often noted upon interrogation of the area. Dilation of the common bile duct may also be present.

Since there exists an association between hypercholesterolemia/hyperlipidemia and gallbladder mucocèles, patients that exhibit both should be screened for hypothyroidism, adrenal hyperplasia syndromes (Cushing’s disease and sex hormone dysregulation), diabetes mellitus, pancreatitis, exogenous exposure to glucocorticoids, and necroinflammatory liver disease.



PATIENT

Louie Romero

SPECIES

Canine

BREED

Terrier Mix

SEX

Neutered male

AGE

13 years

WEIGHT

19.6 lbs

INTERPRETED BY

Eric Lindquist, DMV
DABVP, Cert. IVUSS

IMAGING PERFORMED BY

Adrienne Ligenza

HOSPITAL NAME

Rush Veterinary
Urgent Care

REFERRING VET

Dr. Milot

INVOICE

96625

DATE

3/8/22

Treatment: Surgical intervention is recommended due to the significant risk of peritonitis and sepsis associated with rupture, and since medical management on its own may not be effective. Candidates for surgery must be adequately stabilized prior to surgery, and a coagulation panel should be assessed beforehand. Use of ursodeoxycholic acid (Actigall) is not recommended if any sonographic aspects of wall inflammation or emergent perforation are present. Percutaneous centesis of the gallbladder is also not advised in the presence of a mucocele. Some studies that have investigated a relatively small number of dogs have found medical therapy with Actigall and SAME to be somewhat effective at a very early subclinical stage. Yet, there are no definitive guidelines for ascertaining whether certain sonographic or laboratory findings permit the differentiation of a clinically significant mucocele versus a non-clinical, stable mucocele that may become clinically significant in the future. For this reason, each patient must be assessed individually. It may be the case that very dramatic mucoceles do not cause any overt clinical signs, whereas other patients may have minor mucoceles that lead to significant clinical signs and necessitate urgent cholecystectomy to avoid the onset of bile peritonitis due to rupture. It is generally advised that dogs with clinical signs, elevated liver enzymes, elevated WBC counts, and sonographic evidence of a mucocele be treated surgically. However, if a clinically silent mucocele is found incidentally on ultrasound, careful observation and monitoring is reasonable, provided there are no underlying diseases that may promote degradation (e.g., hyperadrenocorticism). Owners should be instructed to carefully monitor their pets for the development of clinical signs that may signal progression of the disease.

Antibiotic therapy directed towards gram-negative, enteric bacteria (i.e., *E. coli*, *Klebsiella*, *Enterobacter*, etc.) and anaerobic bacteria is indicated, and will likely be necessary for several weeks following surgery. Culture and sensitivity results should guide long-term treatment. Cholecystectomy with a possible bile duct transposition is the procedure of choice. The bile duct is often flushed to remove sludge and debris to help avoid post-surgical obstruction. Cholecystotomy for removing gallbladder contents is not advised as studies have shown that mucocele concretions have reformed in several dogs treated in this manner. At the time of surgery, one should obtain liver biopsies as well as submit cultures and sensitivity of the gallbladder contents. Liver biopsies may show normal tissue, cholangiohepatitis, biliary hyperplasia, vacuolar hepatopathy, or mild to moderate portal hepatitis/fibrosis with bile duct proliferation. Ultrasound-guided cholecystocentesis is not recommended in dogs with mature mucoceles due to the risk of gallbladder rupture and seeding the abdomen with bacteria. Rupture of the gallbladder constitutes a surgical emergency and carries a worse prognosis for survival. Several investigators have noted that, upon surgical exploration of asymptomatic mucocele patients, there is evidence of prior localized peritonitis and fibrosis, likely resulting from tears in the gallbladder's neck, which lead to minute amounts of bile leakage.

Conclusion: Possible etiological explanations for gallbladder mucoceles are quite varied, and underlying diseases must be treated. The treatment of choice is cholecystectomy, with surgical intervention especially recommended for patients with clinical signs or significantly elevated liver enzymes so as to avoid gallbladder rupture and subsequent peritonitis.



PATIENT

Louie Romero

SPECIES

Canine

BREED

Terrier Mix

SEX

Neutered male

AGE

13 years

WEIGHT

19.6 lbs

INTERPRETED BY

Eric Lindquist, DMV
DABVP, Cert. IVUSS

IMAGING PERFORMED BY

Adrienne Ligenza

HOSPITAL NAME

Rush Veterinary
Urgent Care

REFERRING VET

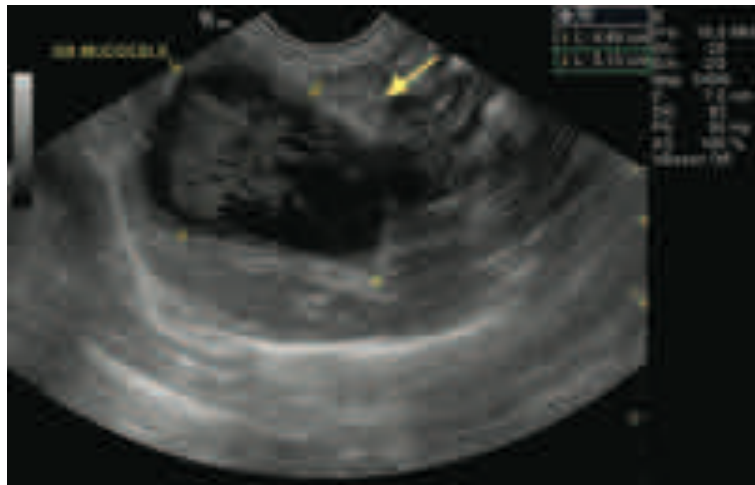Dr. Milot

INVOICE

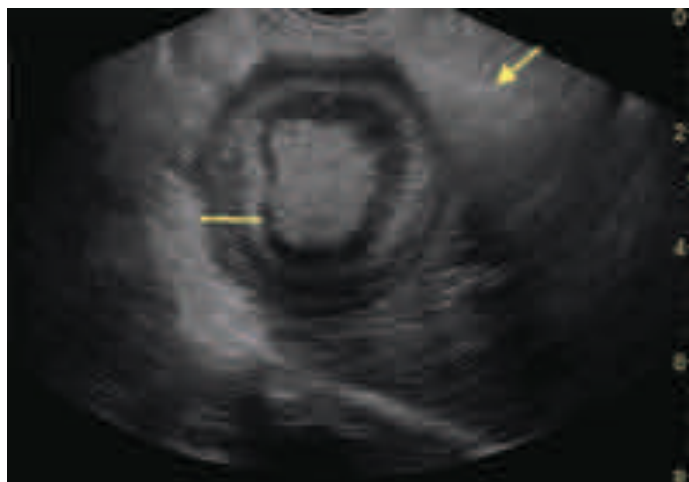96625

DATE

3/8/22



Subxiphoidal long axis of the liver in a dog with a gallbladder mucocele. The gallbladder is severely distended with abnormal high tone and dilated cystic duct. Irregular mucosal hyperplasia is seen. The echogenic inspissated bile accumulates in the center. The adjacent mesentery is hyperechoic indicating perivesical inflammation (arrow). It is very important to note that the absence of a stellate or “kiwi fruit” pattern does not rule out a mucocele and inflammatory pattern associated with the Gb wall indicates a surgical emergency.



Subxiphoidal short axis of the liver in a dog with an inflamed gallbladder mucocele. Note the layered and echogenic appearance of the hyperplastic mucosa and excessive wall thickness (line). Echogenic bile is concentrated in the center. Regional increase in mesenteric echogenicity indicates loss of wall integrity and peritonitis (arrow). The patient had a + Murphy sign (pain upon imaging) typical of inflamed mucocele.



PATIENT

Louie Romero

SPECIES

Canine

BREED

Terrier Mix

SEX

Neutered male

AGE

13 years

WEIGHT

19.6 lbs

INTERPRETED BY

Eric Lindquist, DMV
DABVP, Cert. IVUSS

IMAGING PERFORMED BY

Adrienne Ligenza

HOSPITAL NAME

Rush Veterinary
Urgent Care

REFERRING VET

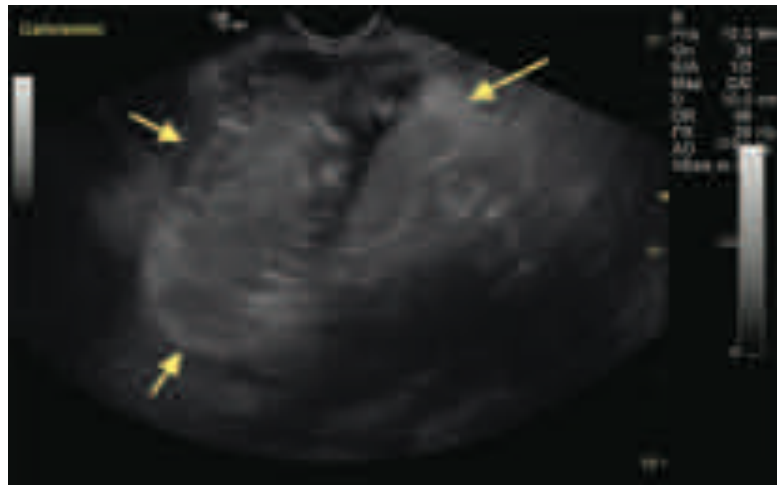Dr. Milot

INVOICE

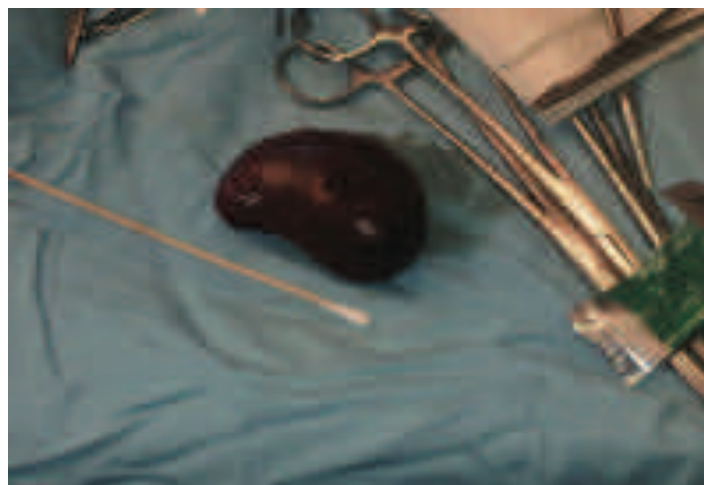
96625

DATE

3/8/22



Long axis of the liver in a diabetic dog with a gallbladder mucocele. Note the sac-like expansion of the enlarged gallbladder (small arrows). Also note the presence of echogenic gas within the severely inflamed and hyperplastic mucosa and gallbladder lumen. Focal peritonitis is seen in the region of the dilated cystic duct (long arrow).



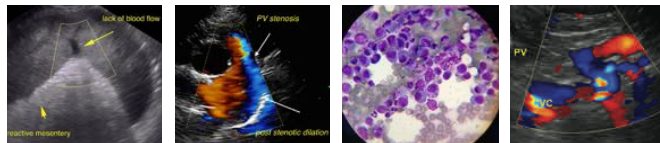
Post cholecystectomy view of a Gb mucocele. Surgery is always the best option for mature mucocele that is firm on palpation surgically and non expressible. A gall bladder motility study can be performed to assess functionality and further support surgical removal. Pericystic inflammatory pattern or + Murphy sign on sonogram indicates a surgical emergency.

References:

Aguirre AL, Center SA, Randolph JF, et al. Gallbladder disease in Shetland Sheepdogs: 38 cases (1995-2005). *J Am Vet Med Assoc* 2007;231(1):79-88.

Besso JG, Wrigley RH, Gliatto JM, Webster CR. Ultrasonographic appearance and clinical findings in 14 dogs with gallbladder mucocele. *Vet Radiol Ultrasound* 2000;41(3):261-71.

Cornejo L, Webster CRL. Canine gallbladder mucoceles. *Compend Contin Educ Vet* 2005;27:912-30.



PATIENT	Crews LJ, Feeney DA, Jessen CR, et al. Clinical, ultrasonographic, and laboratory findings associated with gallbladder disease and rupture in dogs: 45 cases (1997-2007). <i>J Am Vet Med Assoc</i> 2009;234(3):359-66.
Louie Romero	
SPECIES	Kook PH, Schellenberg S, Grest P, et al. Microbiologic evaluation of gallbladder bile of healthy dogs and dogs with iatrogenic hypercortisolism: a pilot study. <i>J Vet Intern Med</i> 2010;24(1):224-28.
Canine	
BREED	Kook PH, Schellenberg S, Rentsch KM, et al. Effects of iatrogenic hypercortisolism on gallbladder sludge formation and biochemical bile constituents in dogs. <i>Vet J</i> 2012;191(2):225-30.
Terrier Mix	
SEX	Malek S, Sinclair E, Hosgood G, et al. Clinical findings and prognostic factors for dogs undergoing cholecystectomy for gallbladder mucocele. <i>Vet Surg</i> 2013;42(4):418-26.
Neutered male	
AGE	Mealey KL, Minch JD, White SN, et al. An insertion mutation in ABCB4 is associated with gallbladder mucocele formation in dogs. <i>Comp Hepatol</i> 2010;9:6.
13 years	
WEIGHT	Mehler SJ, Bennett RA. Canine Extrahepatic Biliary Tract Disease and Surgery. <i>Compend Contin Educ Vet</i> 2006;28(4):302-15.
19.6 lbs	
INTERPRETED BY	Pike FS, Berg J, King NW, et al. Gallbladder mucocele in dogs: 30 cases (2000-2002). <i>J Am Vet Med Assoc</i> 2004;224(10):1615-22.
Eric Lindquist, DMV DABVP, Cert. IVUSS	
IMAGING PERFORMED BY	Walter R, Dunn ME, d'Anjou MA, L'Écuyer M. Nonsurgical resolution of gallbladder mucocele in two dogs. <i>J Am Vet Med Assoc</i> 2008;232(11):1688-93.
Adrienne Ligenza	
HOSPITAL NAME	Worley DR, Hottinger HA, Lawrence HJ. Surgical management of gallbladder mucoceles in dogs: 22 cases (1999-2003). <i>J Am Vet Med Assoc</i> 2004;225(9):1418-22.
Rush Veterinary Urgent Care	
REFERRING VET	
Dr. Milot	
INVOICE	
96625	
DATE	
3/8/22	