



PATIENT

Poochy Farbman

SPECIES

Canine

BREED

Yorkshire Terrier

SEX

Male

AGE

10 years

WEIGHT

5.3 kg

INTERPRETED BY

Eric Lindquist, DMV
DABVP, Cert. IVUSS

IMAGING PERFORMED BY

Dr. De Cordon

HOSPITAL NAME

Lakeview AH

REFERRING VET

Dr. De Cordon

INVOICE

72260

DATE

3/6/26

PRESENTING CLINICAL SIGNS

- Presented for intermittent vomiting and anorexia
- BW showed Lyme+ (first time) Elevation in liver values Poor urine concentration

ULTRASONOGRAPHIC EXAMINATION OF THE ABDOMEN

Urinary System

The **urinary bladder**, trigone, and pelvic urethra presented normal thicknesses and normal tone. The ureters were not visible which is normal. No uroliths or sediment were visualized and anechoic urine was present. No evidence of inflammatory or neoplastic changes was noted. Ureteral papillae were normal.

The **kidneys** revealed largely normal size and structure, corticomedullary definition and ratio (cortex 1/3 of medulla) were essentially maintained with some age-related loss of curvilinear patterns regarding the capsule and C/M junction. The cortices presented largely uniform texture with some increased echogenicity expected for this age patient. Medullary structure differed distinctly from that of the cortex and no evidence of pelvic dilation was present. The left kidney measured 4.0 cm. The right kidney measured 5.03 cm.

The residual prostate measured 0.5 cm.

Adrenal Glands

Both **adrenal glands** were visualized and recognized as having normal shape, size, position and echogenicity for this breed. The phrenic vasculature, glandular echogenicity and detail were unremarkable. Capsule, cortex, and medullary definition were normal for this age patient. The left adrenal gland measured 0.66 cm. The right adrenal gland measured 0.92 cm at the cranial pole and 0.62 cm at the caudal pole.

Spleen

The **spleen** presented a smooth homogeneous parenchyma hyperechoic to liver and renal cortical parenchyma. The capsule was smooth without noticeable expansion or deviation from within the spleen or adjacent pathology. The splenic vasculature demonstrated normal volume without signs of congestion or thrombosis. No sonographic evidence of acute or chronic inflammatory, neoplastic, or infarctual changes was noted.

Liver

The **liver** was uniformly swollen with minor, excessive gallbladder debris and over distension with dependent and suspended bile without evidence of overt mucocele formation. However, excessive sludge was present. The liver presented coarse architecture with mildly increased portal markings and subtle, mixed echogenic changes. Non-disruptive, hypoechoic nodular changes were noted. This is



PATIENT

Poochy Farbman

consistent with vacuolar hepatopathy and some level of remodeling and history of inflammatory component. There was no overt suspicion of neoplasia.

SPECIES

Canine

Gastrointestinal

BREED

Yorkshire Terrier

Examination of the **gastrointestinal tract** revealed a stomach and intestine free of stasis, of normal wall thickness, acceptable curvilinear mural detail, and peristaltic activity. Small and large intestine demonstrated normal luminal chyme and stool consistency respectively. No obstructive or overt infiltrative disease was noted. No associated abnormal lymphatic activity was noted.

SEX

Male

Pancreas

AGE

10 years

The base and limbs of the **pancreas** were observed to be largely isoechoic to surrounding omental fat. Pancreatic duct and capsular contour were acceptably normal and parenchyma respected normal curvilinear patterns. No overt evidence of active inflammatory or neoplastic disease was noted.

WEIGHT

5.3 kg

ULTRASONOGRAPHIC FINDINGS

Structurally unremarkable geriatric abdomen, no specific disease.

INTERPRETED BY

Eric Lindquist, DMV
DABVP, Cert. IVUSS

INTERPRETATION OF THE FINDINGS & FURTHER RECOMMENDATIONS

Supportive care should prove effective. GI protectant protocol is indicated. Full urinary work up warranted if not already performed given the chronic renal changes. FNA of the liver can be considered for further definition of the liver enzyme elevations; however, subjectively it appears benign.

IMAGING PERFORMED BY

Dr. De Cordon

HOSPITAL NAME

Lakeview AH

REFERRING VET

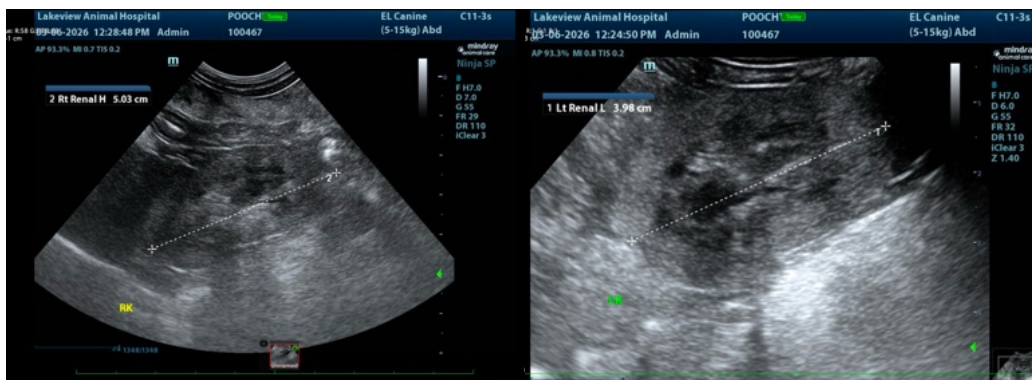
Dr. De Cordon

INVOICE

72260

DATE

3/6/26





PATIENT

Poochy Farbman

SPECIES

Canine

BREED

Yorkshire Terrier

SEX

Male

AGE

10 years

WEIGHT

5.3 kg

INTERPRETED BY

Eric Lindquist, DMV
DABVP, Cert. IVUSS

IMAGING PERFORMED BY

Dr. De Cordon

HOSPITAL NAME

Lakeview AH

REFERRING VET

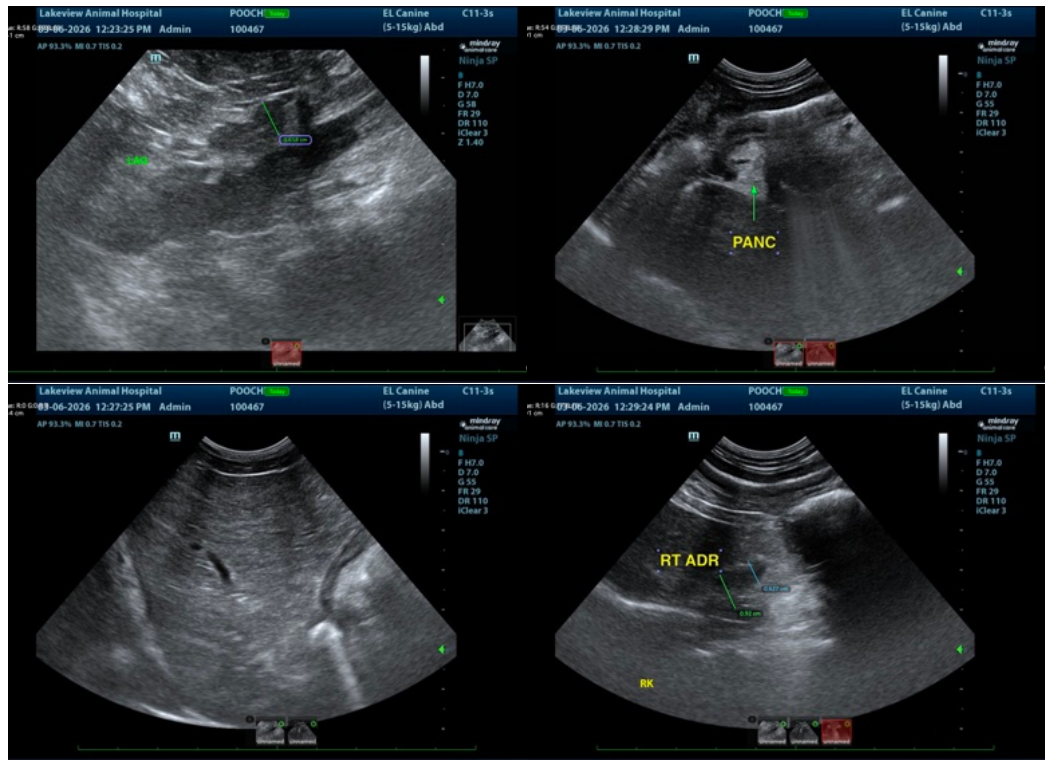
Dr. De Cordon

INVOICE

72260

DATE

3/6/26



The information and recommendations provided are based on the images presented by the referring veterinarian/sonographer. No evaluation can be communicated regarding pathology that was not visible in the image/video clips provided.

Thank you for this referral. If the clinical or image interpretation does not parallel your findings or if I can be of any further assistance please contact me.

Eric Lindquist, DMV, DABVP (CFM), Cert. IVUSS, CEO of SonoPath.com

info@SonoPath.com