



PATIENT

Kahula Reed

SPECIES

Canine

BREED

Mix

SEX

Spayed female

AGE

9 years

WEIGHT

50 lbs

INTERPRETED BY

Eric Lindquist, DMV
DABVP, Cert. IVUSS

IMAGING PERFORMED BY

Nikki Kollman, RVT

HOSPITAL NAME

Airpark AH

REFERRING VET

Dr. Marciszewski

INVOICE

72289

DATE

3/6/26

PRESENTING CLINICAL SIGNS

- Seen January 23, 2026, for increased frequency of urination; small volumes of urine produced. Family noticing ~1 week. Normal water and appetite intake per family
- Significant weight loss noticed: 67 lbs. in 2024 and weighed at 50.2 lbs. at January 2026 visit.
- Presented to PennVet's Emergency Service on 8/31/22 via referral for suspect septic peritonitis post exploratory laparotomy with resection and anastomosis. She was then referred to
- an emergency hospital in the area for emergency surgery and hospitalization. On Sunday morning
- (8/28/22), Kahula underwent an exploratory laparotomy revealing many pieces of carpet in her proximal duodenum causing multiple perforations. A resection and anastomosis of the proximal duodenum was performed.
- 3/9 BCS Stable/unchanged multiple SQ masses U/A: >1.050 Leu 100 Leu/ul Proteinuria Hematuria WBC 10/HPF CBC: NSF CHEM: WNL TT4, FT4: WNL 4DX: NEG

ULTRASONOGRAPHIC EXAMINATION OF THE ABDOMEN

Urinary System

The **urinary bladder**, trigone, and pelvic urethra presented normal thicknesses and normal tone. The pelvic urethra was imaged 1.0 cm beyond the cystourethral junction and appeared normal. The ureters were not visible which is normal. No uroliths or sediment were visualized and anechoic urine was present. No evidence of inflammatory or neoplastic changes was noted. Ureteral papillae were normal.

The **kidneys** revealed largely normal size and structure, corticomedullary definition and ratio (cortex 1/3 of medulla) were essentially maintained with some age-related loss of curvilinear patterns regarding the capsule and C/M junction. The cortices presented largely uniform texture with some increased echogenicity expected for this age patient. Medullary structure differed distinctly from that of the cortex and no evidence of pelvic dilation was present. Slight mineralization was noted in the kidneys. The right kidney measured 5.2 cm and the left kidney measured 5.62 cm.

Adrenal Glands

Both **adrenal glands** were visualized and recognized as having normal shape, size, position and echogenicity for this breed. The phrenic vasculature, glandular echogenicity and detail were unremarkable. Capsule, cortex, and medullary definition were normal for this age patient. The left adrenal gland measured 0.64 cm at the cranial pole and 0.5 cm at the caudal pole. The right adrenal gland measured 2.61 x 1.22 cm at the cranial pole and 0.8 cm at the caudal pole.

Spleen

The **spleen** in this patient was mildly enlarged with uniform parenchyma and was folded upon itself cranially. This is a positional variant and is not pathological. There was no evidence of significant disease.



PATIENT

Kahula Reed

SPECIES

Canine

BREED

Mix

SEX

Spayed female

AGE

9 years

WEIGHT

50 lbs

INTERPRETED BY

Eric Lindquist, DMV
DABVP, Cert. IVUSS

IMAGING PERFORMED BY

Nikki Kollman, RVT

HOSPITAL NAME

Airpark AH

REFERRING VET

Dr. Marciszewski

INVOICE

72289

DATE

3/6/26

Liver

The **liver** images submitted revealed subjectively normal liver size, contour, and structure. Parenchymal echogenicity was naturally coarse and hypoechoic to the spleen. Vascular and biliary tracts were of normal volume with no evidence of congestion. The gallbladder presented acceptably thin walls with primarily anechoic content. The cystic and common bile ducts were normal. No pathological hepatic lymphadenopathy was evident. No overt structural evidence of inflammatory, infiltrative or regenerative pathology was evident.

Gastrointestinal

Examination of the **gastrointestinal tract** revealed a stomach and intestine free of stasis, of normal wall thickness, acceptable curvilinear mural detail, and peristaltic activity. Small and large intestine demonstrated normal luminal chyme and stool consistency respectively. No obstructive or overt infiltrative disease was noted. No associated abnormal lymphatic activity was noted.

Pancreas

The base and limbs of the **pancreas** were observed to be largely isoechoic to surrounding omental fat. Pancreatic duct and capsular contour were acceptably normal and parenchyma respected normal curvilinear patterns. No overt evidence of active inflammatory or neoplastic disease was noted.

ULTRASONOGRAPHIC FINDINGS

Structurally unremarkable abdomen.

Minor renal mineralization.

INTERPRETATION OF THE FINDINGS & FURTHER RECOMMENDATIONS

There was no evidence of significant disease. The patient may be passing small calculi periodically, yet there was no evidence of significant urinary tract disease noted. I cannot rule out deep pelvic urethral pathology as the urethra was only visualized 1.0 cm beyond the cystourethral junction. If clinical signs persistent then an endoscopy is warranted or further imaging of the deep pelvic urethra possibly under sedation. Examination of the vaginal vestibule would be warranted to ensure underlying disease is not present.



PATIENT

Kahula Reed

SPECIES

Canine

BREED

Mix

SEX

Spayed female

AGE

9 years

WEIGHT

50 lbs

INTERPRETED BY

Eric Lindquist, DMV
DABVP, Cert. IVUSS

IMAGING PERFORMED BY

Nikki Kollman, RVT

HOSPITAL NAME

Airpark AH

REFERRING VET

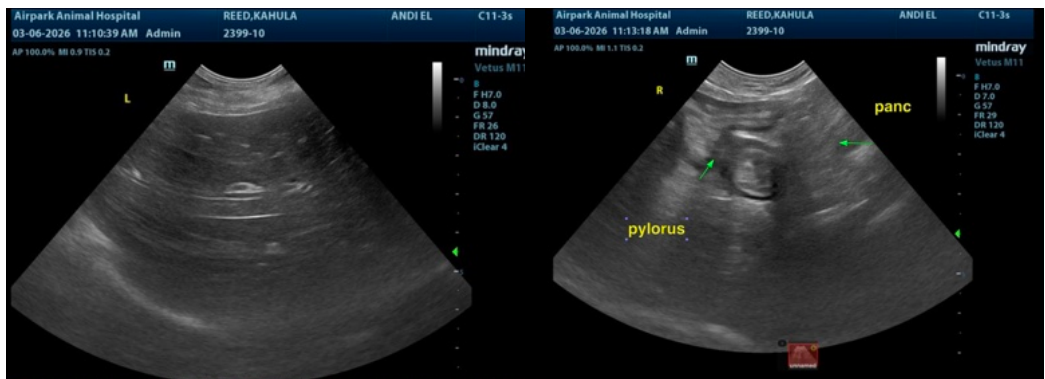
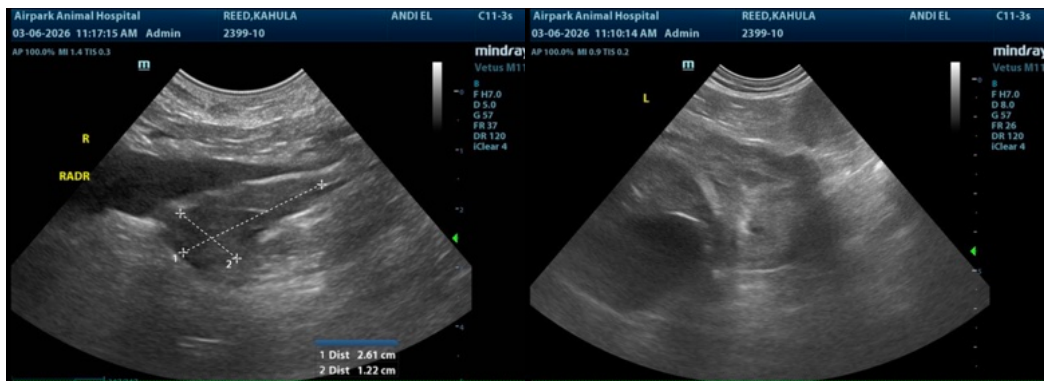
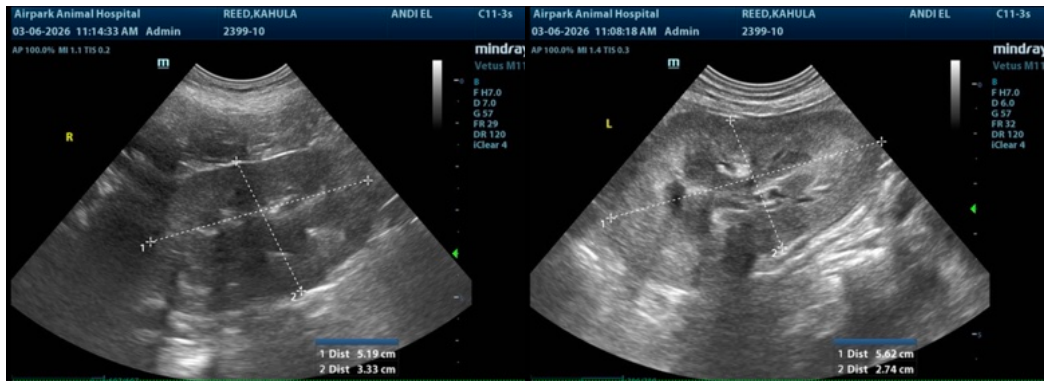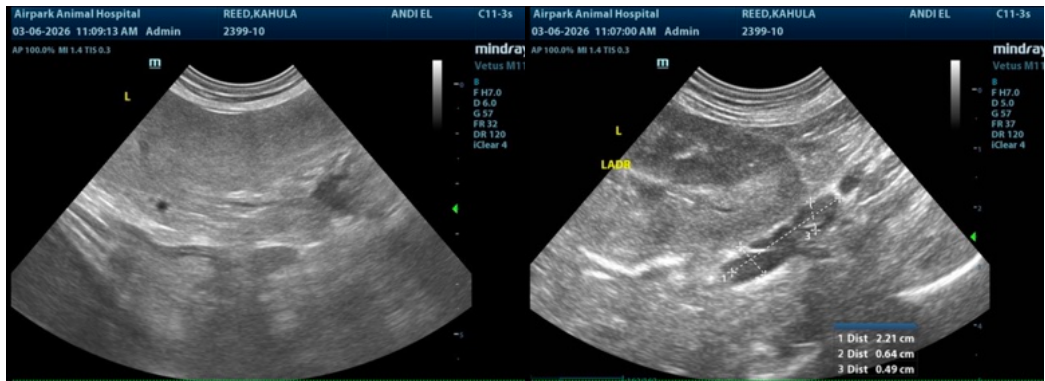
Dr. Marciszewski

INVOICE

72289

DATE

3/6/26





PATIENT

Kahula Reed

SPECIES

Canine

BREED

Mix

SEX

Spayed female

AGE

9 years

WEIGHT

50 lbs

INTERPRETED BY

Eric Lindquist, DMV
DABVP, Cert. IVUSS

IMAGING PERFORMED BY

Nikki Kollman, RVT

HOSPITAL NAME

Airpark AH

REFERRING VET

Dr. Marciszewski

INVOICE

72289

DATE

3/6/26

The information and recommendations provided are based on the images presented by the referring veterinarian/sonographer. No evaluation can be communicated regarding pathology that was not visible in the image/video clips provided.

Thank you for this referral. If the clinical or image interpretation does not parallel your findings or if I can be of any further assistance please contact me.

Eric Lindquist, DMV, DABVP (CFM), Cert. IVUSS, CEO of SonoPath.com

info@SonoPath.com