



PATIENT

Gabby Natoli

SPECIES

Canine

BREED

Labradoodle

SEX

Spayed female

AGE

12 years

WEIGHT

70.8 lbs

INTERPRETED BY

Eric Lindquist, DMV
DABVP, Cert. IVUSS

IMAGING PERFORMED BY

Susan Lincoski

HOSPITAL NAME

University Drive VH

REFERRING VET

Dr. Lincoski

INVOICE

72309

DATE

3/6/26

PRESENTING CLINICAL SIGNS

- T = 100.7
- Patient presents for recheck from CP vets from ataxia, pyrexia, and mildly elevated liver values. Dog is currently on metronidazole 250mg 1 tablet BID x 5 days, doxycycline 100mg 3 tablets SID x 28 days, and denamarin. Patient gets 2.5mg prednisone EOD for Masticatory myositis (since 1 year old)
- Rechecking cbc/chem/t4 in house, bile acids (fasted), and abdominal u/s due to CP vets noting a liver lobe nodule and enlarged gallbladder.
- CBC- stable mild anemia (HCT 33.7%), RBCs (5.19), NORMAL PLT Chem - slightly improved ALT (248), APT (1555), GGT (46) Tick panel pending at CP vets.

ULTRASONOGRAPHIC EXAMINATION OF THE ABDOMEN

Urinary System

The **urinary bladder**, trigone, and pelvic urethra presented normal thicknesses and normal tone. The ureters were not visible which is normal. No uroliths or sediment were visualized and anechoic urine was present. No evidence of inflammatory or neoplastic changes was noted. Ureteral papillae were normal.

The **kidneys** revealed largely normal size and structure, corticomedullary definition and ratio (cortex 1/3 of medulla) were essentially maintained with some age-related loss of curvilinear patterns regarding the capsule and C/M junction. The cortices presented largely uniform texture with some increased echogenicity expected for this age patient. Medullary structure differed distinctly from that of the cortex and no evidence of pelvic dilation was present. Slight mineralization was noted in the kidneys. The left kidney measured 6.02 cm. The right kidney measured 6.0 cm.

Adrenal Glands

Both **adrenal glands** were visualized and recognized as having normal shape, size, position and echogenicity for this breed. The phrenic vasculature, glandular echogenicity and detail were unremarkable. Capsule, cortex, and medullary definition were normal for this age patient. The left adrenal gland measured 0.5 cm. The right adrenal gland measured 0.46 cm.

Spleen

The **spleen** was largely smooth with subtle heterogeneous parenchymal changes while maintaining normal echogenic relationship to the liver and kidney. These changes are consistent with normal age-related alteration. Occasional, hyperechoic The capsule was smooth without noticeable impingement from within the spleen or from pathology in the adjacent abdomen. The splenic vasculature demonstrated normal volume without signs of congestion or significant contraction. No evidence of active acute or chronic inflammatory, neoplastic, or infarctual changes was noted.



PATIENT

Gabby Natoli

SPECIES

Canine

BREED

Labradoodle

SEX

Spayed female

AGE

12 years

WEIGHT

70.8 lbs

INTERPRETED BY

Eric Lindquist, DMV
DABVP, Cert. IVUSS

IMAGING PERFORMED BY

Susan Lincoski

HOSPITAL NAME

University Drive VH

REFERRING VET

Dr. Lincoski

INVOICE

72309

DATE

3/6/26

Liver

The **liver** images from right and left intercostal as well as subcostal views revealed subjectively normal liver size, contour, and structure. A hyperechoic macronodular change that measured 5.3 cm in the right medial liver. Some age-related parenchymal remodeling was noted but likely not clinically significant at this time. Vascular and biliary tracts were of normal volume and no evidence of congestion was noted. The gallbladder presented some dependent debris with essentially normal contour. The cystic and common bile ducts were normal. No overt evidence of active inflammatory, infiltrative or regenerative pathology was noted but should be paired with current or past LE elevations regarding any clinical significance to this presentation. The hepatic lymph nodes were unremarkable.

Gastrointestinal

Examination of the **gastrointestinal tract** revealed a stomach and intestine free of stasis, of normal wall thickness, acceptable curvilinear mural detail, and peristaltic activity. Small and large intestine demonstrated normal luminal chyme and stool consistency respectively. No obstructive or overt infiltrative disease was noted. No associated abnormal lymphatic activity was noted.

Pancreas

The base and limbs of the **pancreas** were observed to be largely isoechoic to surrounding omental fat. Pancreatic duct and capsular contour were acceptably normal and parenchyma respected normal curvilinear patterns. No overt evidence of active inflammatory or neoplastic disease was noted.

ULTRASONOGRAPHIC FINDINGS

Medial macronodular change. Differentials include low-grade carcinoma, granuloma nodular hyperplasia. Age related abdominal changes.

INTERPRETATION OF THE FINDINGS & FURTHER RECOMMENDATIONS

The cause of ataxia is unclear. Ultrasound-guided FNA of the hepatic change would be ideal of the nodule (if accessible) and general hepatic parenchyma. Serial blood pressure measurements, full CNS examination +/- spinal CT is indicated depending upon the clinical exam and signs.



PATIENT

Gabby Natoli

SPECIES

Canine

BREED

Labradoodle

SEX

Spayed female

AGE

12 years

WEIGHT

70.8 lbs

INTERPRETED BY

Eric Lindquist, DMV
DABVP, Cert. IVUSS

**IMAGING
PERFORMED BY**

Susan Lincoski

HOSPITAL NAME

University Drive VH

REFERRING VET

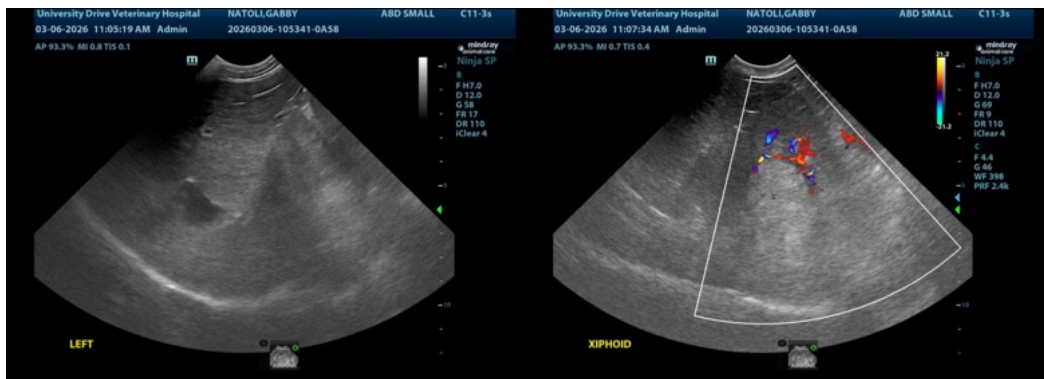
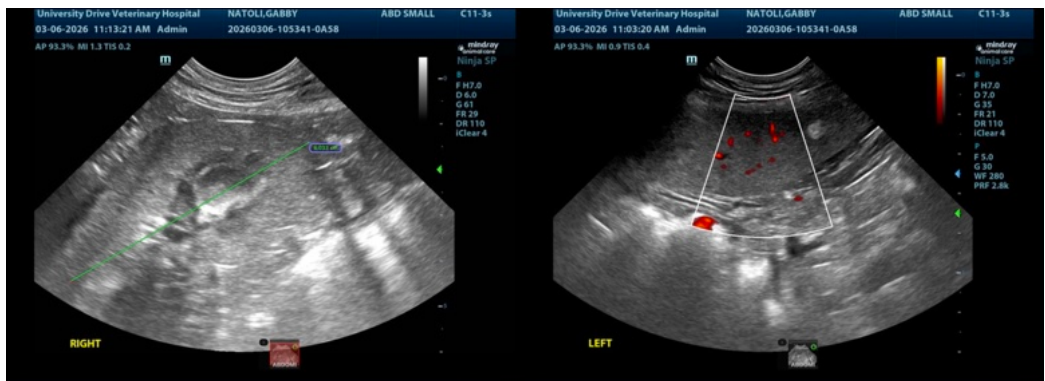
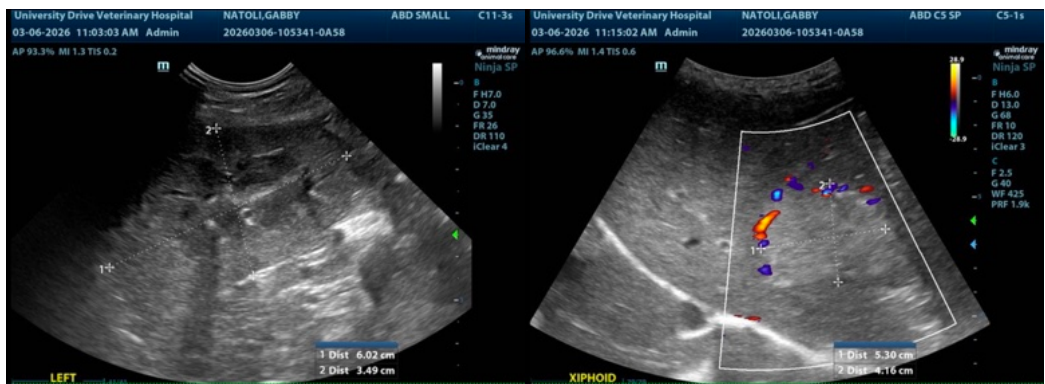
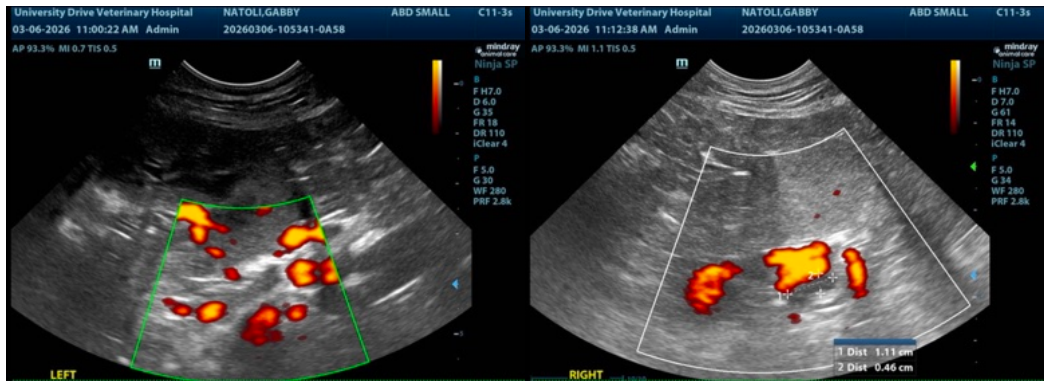
Dr. Lincoski

INVOICE

72309

DATE

3/6/26





PATIENT

Gabby Natoli

SPECIES

Canine

BREED

Labradoodle

SEX

Spayed female

AGE

12 years

WEIGHT

70.8 lbs

INTERPRETED BY

Eric Lindquist, DMV
DABVP, Cert. IVUSS

IMAGING PERFORMED BY

Susan Lincoski

HOSPITAL NAME

University Drive VH

REFERRING VET

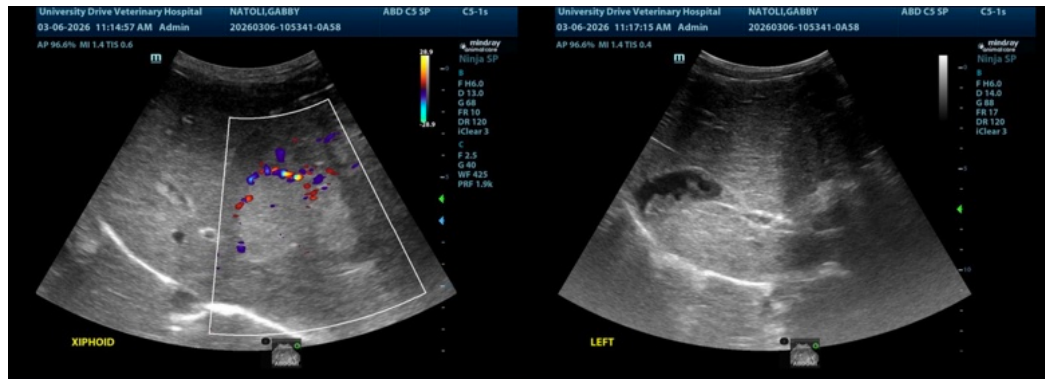
Dr. Lincoski

INVOICE

72309

DATE

3/6/26



The information and recommendations provided are based on the images presented by the referring veterinarian/sonographer. No evaluation can be communicated regarding pathology that was not visible in the image/video clips provided.

Thank you for this referral. If the clinical or image interpretation does not parallel your findings or if I can be of any further assistance please contact me.

Eric Lindquist, DMV, DABVP (CFM), Cert. IVUSS, CEO of SonoPath.com

info@SonoPath.com