



PATIENT

Ed Schrandt

SPECIES

Canine

BREED

Rat Terrier

SEX

Neutered male

AGE

14 ½ years

WEIGHT

18 lbs

INTERPRETED BY

Eric Lindquist, DMV
DABVP, Cert. IVUSS

IMAGING PERFORMED BY

A Murphy CVT

HOSPITAL NAME

Wauwatosa VC

REFERRING VET

Dr. Binor

INVOICE

72331

DATE

3/6/26

PRESENTING CLINICAL SIGNS

- pre-surgery blood work indicated an elevation in ALT, has a heart murmur, not on any medication for heart disease - BNP was normal. started Denamarin & amoxicillin due to elevation of leukocytes as well. abdominal imaging to check hepatic system status - check for structural disease such as neoplasia & any contraindications to sedation or anesthesia
- ALT - 199 (10-125) BUN - 28 (7-27) Neutrophilia 12.11 (2.95-11.64) Monocytosis 1.3 (0.16-1.12) BNP - 398 (0-900)

ULTRASONOGRAPHIC EXAMINATION OF THE ABDOMEN

Urinary System

The **urinary bladder**, trigone, and pelvic urethra presented normal thicknesses and normal tone. The pelvic urethra was imaged 2.0 cm beyond the cystourethral junction and appeared normal. The ureters were not visible which is normal. No uroliths or sediment were visualized and anechoic urine was present. No evidence of inflammatory or neoplastic changes was noted. Ureteral papillae were normal.

The **kidneys** revealed largely normal size and structure, corticomedullary definition and ratio (cortex 1/3 of medulla) were essentially maintained with some age-related loss of curvilinear patterns regarding the capsule and C/M junction. The cortices presented largely uniform texture with some increased echogenicity expected for this age patient. Medullary structure differed distinctly from that of the cortex and no evidence of pelvic dilation was present. The left kidney measured 4.87 cm. The right kidney measured 4.5 cm.

The residual prostate measured 0.93 cm.

Adrenal Glands

Both **adrenal glands** were visualized and recognized as having normal shape, size, position and echogenicity for this breed. The phrenic vasculature, glandular echogenicity and detail were unremarkable. Capsule, cortex, and medullary definition were normal for this age patient. The left adrenal gland measured 0.4 cm. The right adrenal gland measured 0.8 cm at the cranial pole and 0.5 cm at the caudal pole.

Spleen

The **spleen** was slightly enlarged with subtle micronodular changes. This is likely hyperplasia. 25-gauge FNA is warranted if any weight loss is an issue.

Liver

The **liver** images from right and left intercostal as well as subcostal views revealed subjectively normal liver size, contour, and structure. Some age-related parenchymal remodeling was noted but likely not clinically significant at this time. Vascular and biliary tracts were of normal volume and no evidence of congestion was noted. The gallbladder presented some dependent debris with essentially normal contour. The cystic and common bile ducts were normal. No overt evidence of active inflammatory,



PATIENT

Ed Schrandt

SPECIES

Canine

BREED

Rat Terrier

SEX

Neutered male

AGE

14 ½ years

WEIGHT

18 lbs

INTERPRETED BY

Eric Lindquist, DMV
DABVP, Cert. IVUSS

IMAGING PERFORMED BY

A Murphy CVT

HOSPITAL NAME

Wauwatosa VC

REFERRING VET

Dr. Binor

INVOICE

72331

DATE

3/6/26

infiltrative or regenerative pathology was noted but should be paired with current or past LE elevations regarding any clinical significance to this presentation. The hepatic lymph nodes were unremarkable.

Gastrointestinal

Examination of the **gastrointestinal tract** revealed a stomach and intestine free of stasis, of normal wall thickness, acceptable curvilinear mural detail, and peristaltic activity. Small and large intestine demonstrated normal luminal chyme and stool consistency respectively. No obstructive or overt infiltrative disease was noted. No associated abnormal lymphatic activity was noted.

Pancreas

The base and limbs of the **pancreas** were observed to be largely isoechoic to surrounding omental fat. Pancreatic duct and capsular contour were acceptably normal and parenchyma respected normal curvilinear patterns. No overt evidence of active inflammatory or neoplastic disease was noted.

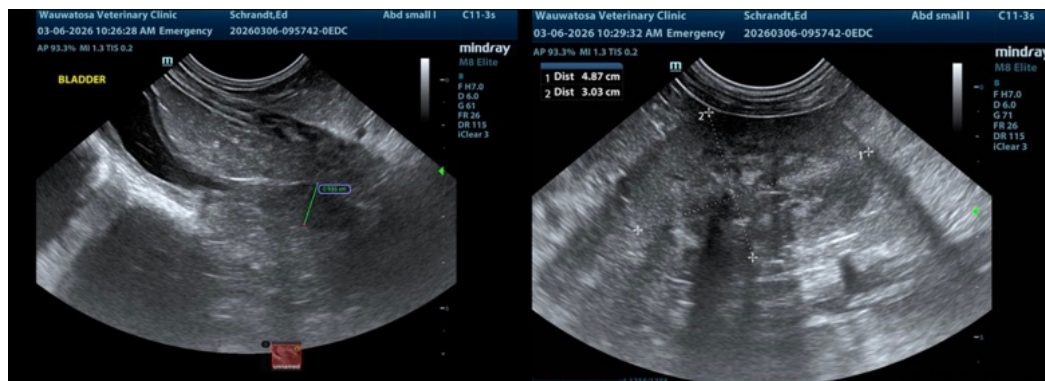
ULTRASONOGRAPHIC FINDINGS

Hyperplastic spleen.

Age related hepatic changes.

INTERPRETATION OF THE FINDINGS & FURTHER RECOMMENDATIONS

There was no overt contraindication to anesthetic procedure. FNA of the spleen and liver can be considered for completeness at the time of anesthesia. The changes are mild and acceptable for this age and breed.





PATIENT

Ed Schrandt

SPECIES

Canine

BREED

Rat Terrier

SEX

Neutered male

AGE

14 ½ years

WEIGHT

18 lbs

INTERPRETED BY

Eric Lindquist, DMV
DABVP, Cert. IVUSS

**IMAGING
PERFORMED BY**

A Murphy CVT

HOSPITAL NAME

Wauwatosa VC

REFERRING VET

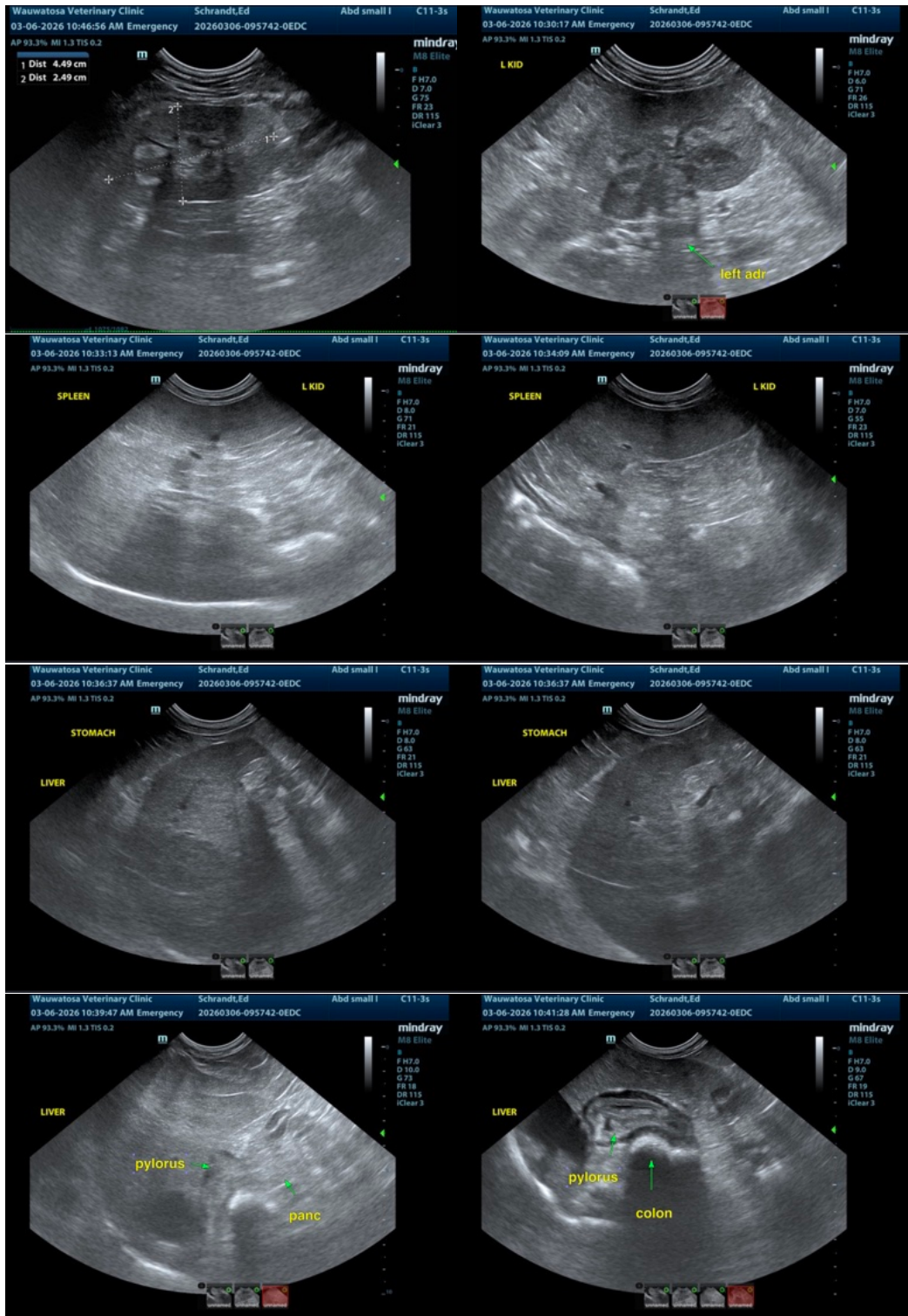
Dr. Binor

INVOICE

72331

DATE

3/6/26





PATIENT

Ed Schrandt

SPECIES

Canine

BREED

Rat Terrier

SEX

Neutered male

AGE

14 ½ years

WEIGHT

18 lbs

INTERPRETED BY

Eric Lindquist, DMV
DABVP, Cert. IVUSS

IMAGING PERFORMED BY

A Murphy CVT

HOSPITAL NAME

Wauwatosa VC

REFERRING VET

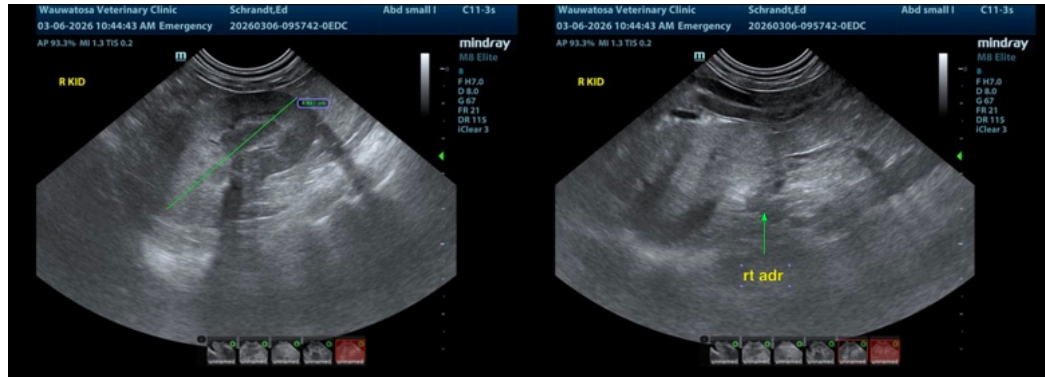
Dr. Binor

INVOICE

72331

DATE

3/6/26



The information and recommendations provided are based on the images presented by the referring veterinarian/sonographer. No evaluation can be communicated regarding pathology that was not visible in the image/video clips provided.

Thank you for this referral. If the clinical or image interpretation does not parallel your findings or if I can be of any further assistance please contact me.

Eric Lindquist, DMV, DABVP (CFM), Cert. IVUSS, CEO of SonoPath.com

info@SonoPath.com