

PATIENT

Duke Shander

SPECIES

Feline

BREED

Domestic Shorthair

SEX

Neuered male

AGE

4 years

WEIGHT

6.13 kg

INTERPRETED BY

Eric Lindquist, DMV
DABVP, Cert. IVUSS

IMAGING PERFORMED BY

Erin Wicks

HOSPITAL NAME

Shores Veterinary
Emergency Cneter

REFERRING VET

Dr. Kerr

INVOICE

72261

DATE

3/6/26

PRESENTING CLINICAL SIGNS

- Patient was seen at rDVM last month for suspected asthma. Rads taken and showed Bates body as well as round, enlarged, angled kidneys. BW showed kidney values WNL. P's flanks a little sunken but acting normal.
- Current meds: Pred 5mg EOD - last given ¾
- Exam WNL

ULTRASONOGRAPHIC EXAMINATION OF THE ABDOMEN

Urinary System

The **urinary bladder**, trigone, and pelvic urethra presented normal thicknesses and normal tone. The ureters were not visible which is normal. No uroliths or sediment were visualized and anechoic urine was present. No evidence of inflammatory or neoplastic changes was noted. Ureteral papillae were normal.

The **kidneys** revealed normal size and structure, corticomedullary definition and ratio for this age. The cortices presented largely uniform texture with normal echogenic relationship to liver and spleen. Medullary structure differed distinctly from the cortex and no evidence of pelvic dilation was present. The capsules were acceptably uniform without significant irregularities. The left kidney measured 5.0 cm. The right kidney measured 5.0 cm.

Adrenal Glands

Both **adrenal glands** were visualized and recognized as having normal shape, size, position and echogenicity for this breed. The phrenic vasculature, glandular echogenicity and detail were unremarkable. Capsule, cortex, and medullary definition were normal for this age patient.

Spleen

The **spleen** presented a smooth homogeneous parenchyma hyperechoic to liver and renal cortical parenchyma. The capsule was smooth without noticeable expansion or deviation from within the spleen or adjacent pathology. The splenic vasculature demonstrated normal volume without signs of congestion or thrombosis. No sonographic evidence of acute or chronic inflammatory, neoplastic, or infarctual changes was noted.

Liver

The **liver** images submitted revealed subjectively normal liver size, contour, and structure. Parenchymal echogenicity was naturally coarse and hypoechoic to the spleen. Vascular and biliary tracts were of normal volume with no evidence of congestion. The gallbladder presented acceptably thin walls with primarily anechoic content. The cystic and common bile ducts were normal. No pathological hepatic lymphadenopathy was evident. No overt structural evidence of inflammatory, infiltrative or regenerative pathology was evident.



PATIENT

Duke Shander

SPECIES

Feline

BREED

Domestic Shorthair

SEX

Neuered male

AGE

4 years

WEIGHT

6.13 kg

INTERPRETED BY

Eric Lindquist, DMV
DABVP, Cert. IVUSS

IMAGING PERFORMED BY

Erin Wicks

HOSPITAL NAME

Shores Veterinary
Emergency Cneter

REFERRING VET

Dr. Kerr

INVOICE

72261

DATE

3/6/26

Gastrointestinal

The **stomach** revealed progressively shadowing hairball type density. Some transit of chyme was noted in the small intestine; however, partial outflow delay is likely an issue. The small intestines and colon were unremarkable with normal curvilinear mural patterns and content.

Pancreas

The base and limbs of the **pancreas** were observed to be largely isoechoic to surrounding omental fat. Pancreatic duct and capsular contour were acceptably normal and parenchyma respected normal curvilinear patterns. No overt evidence of active inflammatory or neoplastic disease was noted.

Free Abdomen

A Bates body was visualized and measured 1.2 cm. This is not pathological.

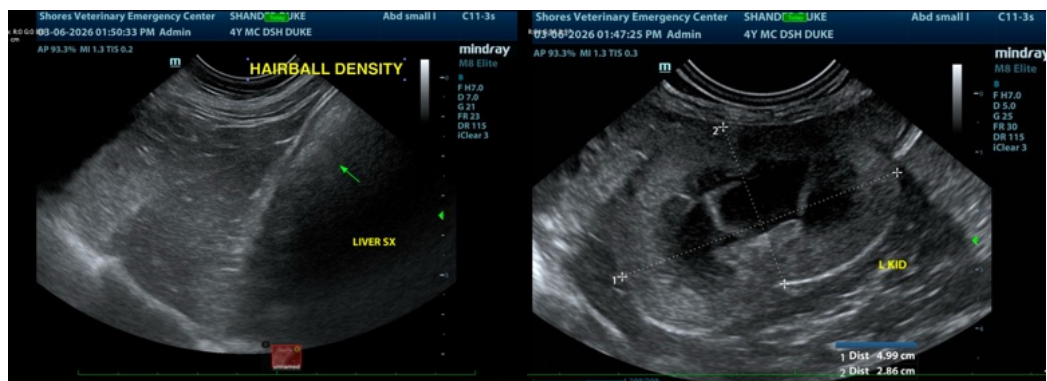
ULTRASONOGRAPHIC FINDINGS

Full stomach, hairball type density.

Bates body.

INTERPRETATION OF THE FINDINGS & FURTHER RECOMMENDATIONS

Medical management should prove effective. I cannot rule out soft foreign matter.





PATIENT

Duke Shander

SPECIES

Feline

BREED

Domestic Shorthair

SEX

Neuered male

AGE

4 years

WEIGHT

6.13 kg

INTERPRETED BY

Eric Lindquist, DMV
DABVP, Cert. IVUSS

IMAGING PERFORMED BY

Erin Wicks

HOSPITAL NAME

Shores Veterinary
Emergency Cneter

REFERRING VET

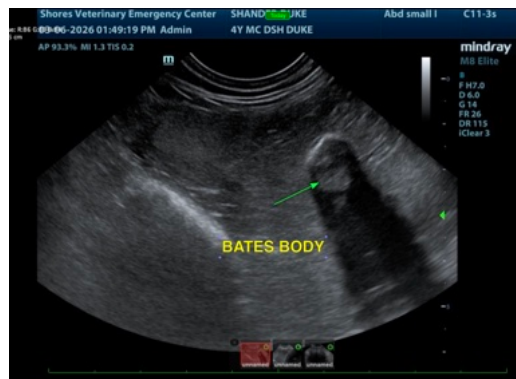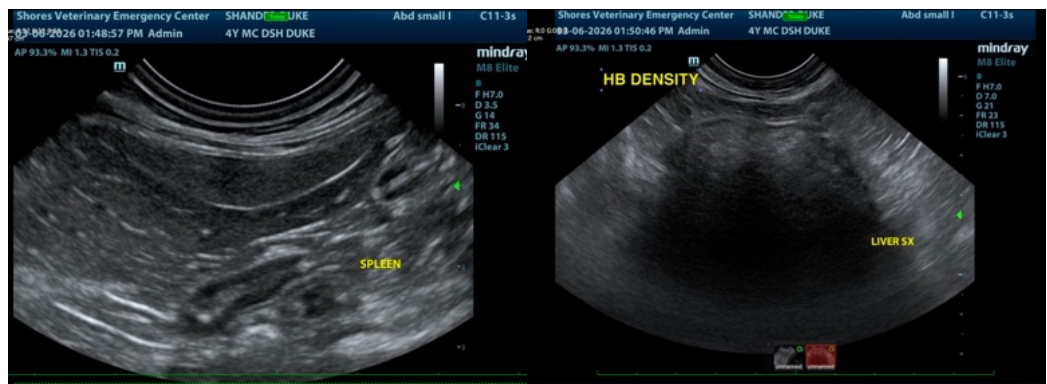
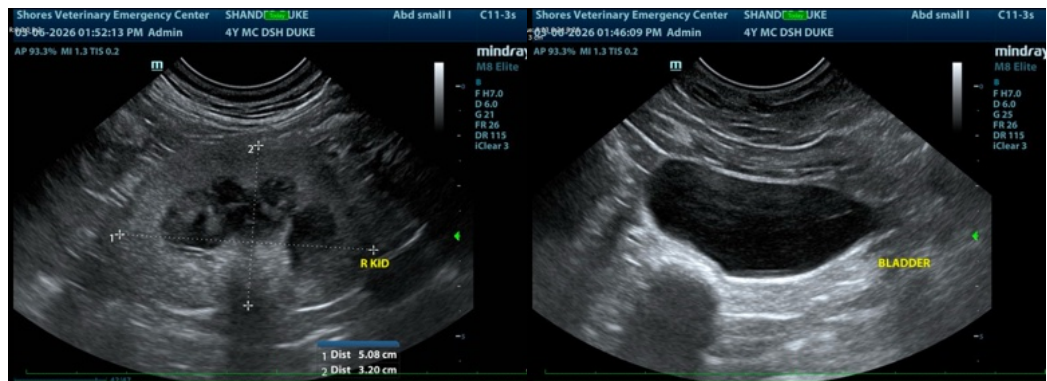
Dr. Kerr

INVOICE

72261

DATE

3/6/26



The information and recommendations provided are based on the images presented by the referring veterinarian/sonographer. No evaluation can be communicated regarding pathology that was not visible in the image/video clips provided.

Thank you for this referral. If the clinical or image interpretation does not parallel your findings or if I can be of any further assistance please contact me.

Eric Lindquist, DMV, DABVP (CFM), Cert. IVUSS, CEO of SonoPath.com

info@SonoPath.com