

**PATIENT PRESENTING CLINICAL SIGNS**

**PATIENT** Winston Daniels  
**PRESENTING CLINICAL SIGNS** History: Pet has a grade 4/6 murmur since first appointment. Growing well, no other concerns otherwise.

**SPECIES**

Feline

**BREED**

Domestic Shorthair

**SEX**

Male

**AGE**

5 months

**WEIGHT**

6 lbs

**ULTRASONOGRAPHIC EXAMINATION OF THE HEART**

A limited echocardiogram was performed in this patient. The left ventricular wall thicknesses were slightly irregular, yet measurably within normal limits. The contractility and chamber sizes appear normal. There was pleural or pericardial effusion was present. However, a ventricular septal defect was visible in multiple views measuring up to 0.5 cm. There was no pericardial or pleural effusion present. However, a ventricular septal defect was visible in multiple views measuring up to 0.5 cm and appears compensated.

**ULTRASONOGRAPHIC FINDINGS**

Limited echocardiogram with ventricular septal defect.

**INTERPRETATION OF THE FINDINGS & FURTHER RECOMMENDATIONS**

SDEP protocol or equivalent is recommended. No treatment is recommended at this time. The prognosis long term is guarded as the septal defect is fairly large.

**INTERPRETED BY**

Eric Lindquist, DMV  
DABVP, Cert. IVUSS

**IMAGING PERFORMED BY**

Dr. Reyes

**HOSPITAL NAME**

Mobile Vet Ultrasound

**REFERRING VET**

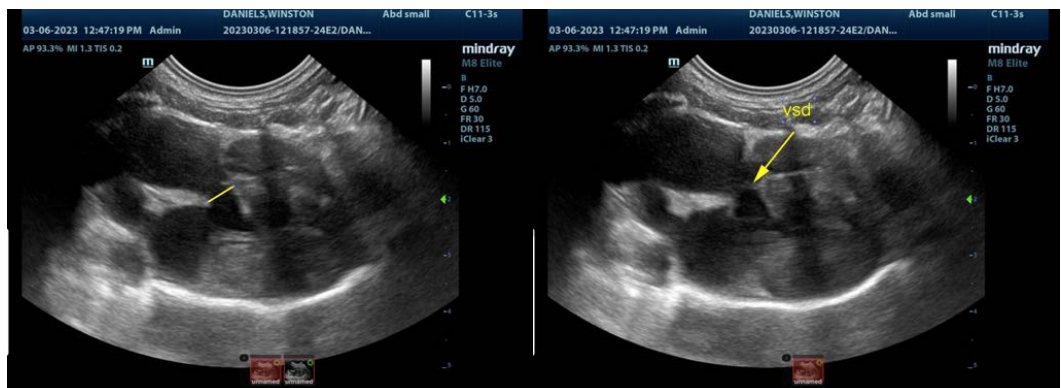Dr. Reyes

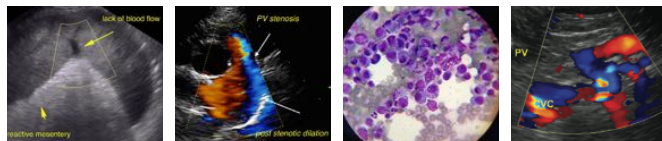
**INVOICE**

43120

**DATE**

3/6/23





**PATIENT**

Winston Daniels

**SPECIES**

Feline

**BREED**

Domestic Shorthair

**SEX**

Male

**AGE**

5 months

**WEIGHT**

6 lbs

**INTERPRETED BY**

Eric Lindquist, DMV  
DABVP, Cert. IVUSS

**IMAGING  
PERFORMED BY**

Dr. Reyes

**HOSPITAL NAME**

Mobile Vet Ultrasound

**REFERRING VET**

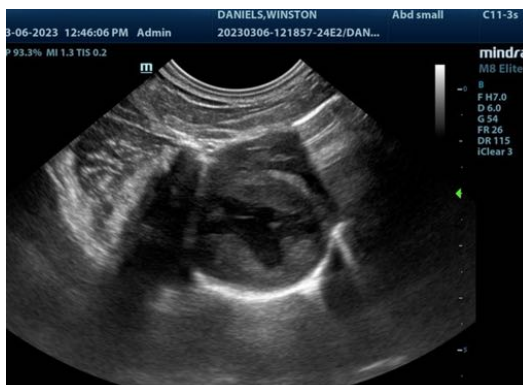Dr. Reyes

**INVOICE**

43120

**DATE**

3/6/23



The information and recommendations provided are based on the images presented by the referring veterinarian/sonographer. No evaluation can be communicated regarding pathology that was not visible in the image/video clips provided.

Thank you for this referral. If the clinical or image interpretation does not parallel your findings or if I can be of any further assistance please contact me.

**Eric Lindquist**, DMV, DABVP, Cert. IVUSS, CEO of SonoPath.com  
info@SonoPath.com