


**PATIENT**

Sushi Carter's Rescue

**PRESENTING CLINICAL SIGNS**

Pre-anesthetic check before dental. Grade 4 systolic murmur (was a grade 2 in 2020). Sedated with IV butorphanol for echo. Coughs only occasionally.

**SPECIES**

Canine

Abnormal PE/Chem/CBC/UA Results: BP: 163/117 (126), 130/110 (113), 124/110 (119)

**BREED**

Jack Russell Terrier

**ULTRASONOGRAPHIC EXAMINATION OF THE HEART**
**SEX**

MN

**AGE**

10yr

**WEIGHT**

9.7kg

CANINE CARDIAC PARAMETERS	MR VMAX (m/s)	TR VMAX (m/s)	LA/AO (Boon method)	LA/AO (Heart Base; Swe)	FS (%)	EF (%)	EPSS (cm)
NORMAL PARAMETER	4.5-5.5	<2.7	1.3	<1.3	28-40	40-100	<0.6
PATIENT			1.4	1.4	41	73	0.1
CANINE CARDIAC PARAMETERS	HR (BPM)	AV VMAX (m/s)	PV MAX (m/s)	BODY WEIGHT (kg)	LA 2D short axis Base view (cm)	LVIDd Avg; 2D and m-mode short axis (cm)	LVIDs Avg; 2D and m-mode short axis (cm)
NORMAL PARAMETER	50-100	0.7-1.7	0.7-1.6				
PATIENT		1.46	0.52		3.05	3.66	

**INTERPRETED BY**

Eric Lindquist, DMV DABVP, Cert. IVUS

**Cardiac Presentation**

The echocardiogram in this patient demonstrated normal left atrial size based on 3 different LA measurement methods. Chamber volumes and echogenicity were normal. The cranial and caudal mitral valve leaflets presented vegetative thickening consistent with endocardiosis. Prolapsed anterior mitral valve leaflet noted. Doppler indicated measurable insufficiency. The left ventricle presented thicknesses with linear contour and was not dilated nor restricted. The myocardium presented normal echogenicity without subjective evidence of significant fibrotic or ischemic disease. Contractility of the ventricular walls was adequate and in normal range for this patient evidenced by the fractional shortening measurement and subjective evaluation of the different regions of the myocardium. The left ventricular outflow tract demonstrated normal laminar flow and subjective structural integrity. The right atrium and auricle revealed normal size, structure and content. No evidence of masses was noted or chamber overload. Tricuspid valvular assessment demonstrated adequate linear morphology. The right ventricle was of normal size (1/3 diameter of LV), chordae structure, myocardial echogenicity and thickness. Pulmonic tract assessment revealed normal valve structure, laminar flow, and diameter (approx. 1:1 pa/ao ratio). No visible pericardial or free pleura fluid was noted. No echographically detectable evidence of infiltrative disease was visible. The cranial mediastinum and pericardial regions were free of masses in the visible window.

**IMAGING PERFORMED BY**

Elyse Hauer

**HOSPITAL NAME**

Mariposa Veterinary Hospital

**REFERRING VET**

Alan Poon

**ULTRASONOGRAPHIC FINDINGS**

- Stage B1 valvular disease with mitral valve prolapse

**INVOICE**

13131ag

**DATE**

03/06/2023



**PATIENT**

Sushi Carter's Rescue

**INTERPRETATION OF THE FINDINGS & FURTHER RECOMMENDATIONS**

The heart is stable without clinical disease. No overt contraindication for anesthesia of brief to moderate duration. I suggest Torbutrol premed, Propofol induction, Isoflurane maintenance or similar protocol if anesthesia is desired. Blood pressure recommended if not already performed and target white coat negative systolic pressure of < 160 mmHg. If higher than this ACE-inhibitor is suggested to reach this level. Recheck echocardiogram is recommended in 6 months, earlier if murmur grade increases or clinical signs initiate.

**SPECIES**

Canine

**BREED**

Jack Russell Terrier

**SEX**

MN

**AGE**

10yr

**WEIGHT**

9.7kg

**INTERPRETED BY**

Eric Lindquist, DMV  
DABVP, Cert. IVUSS

**IMAGING PERFORMED BY**

Elyse Hauer

**HOSPITAL NAME**

Mariposa Veterinary  
Hospital

**REFERRING VET**

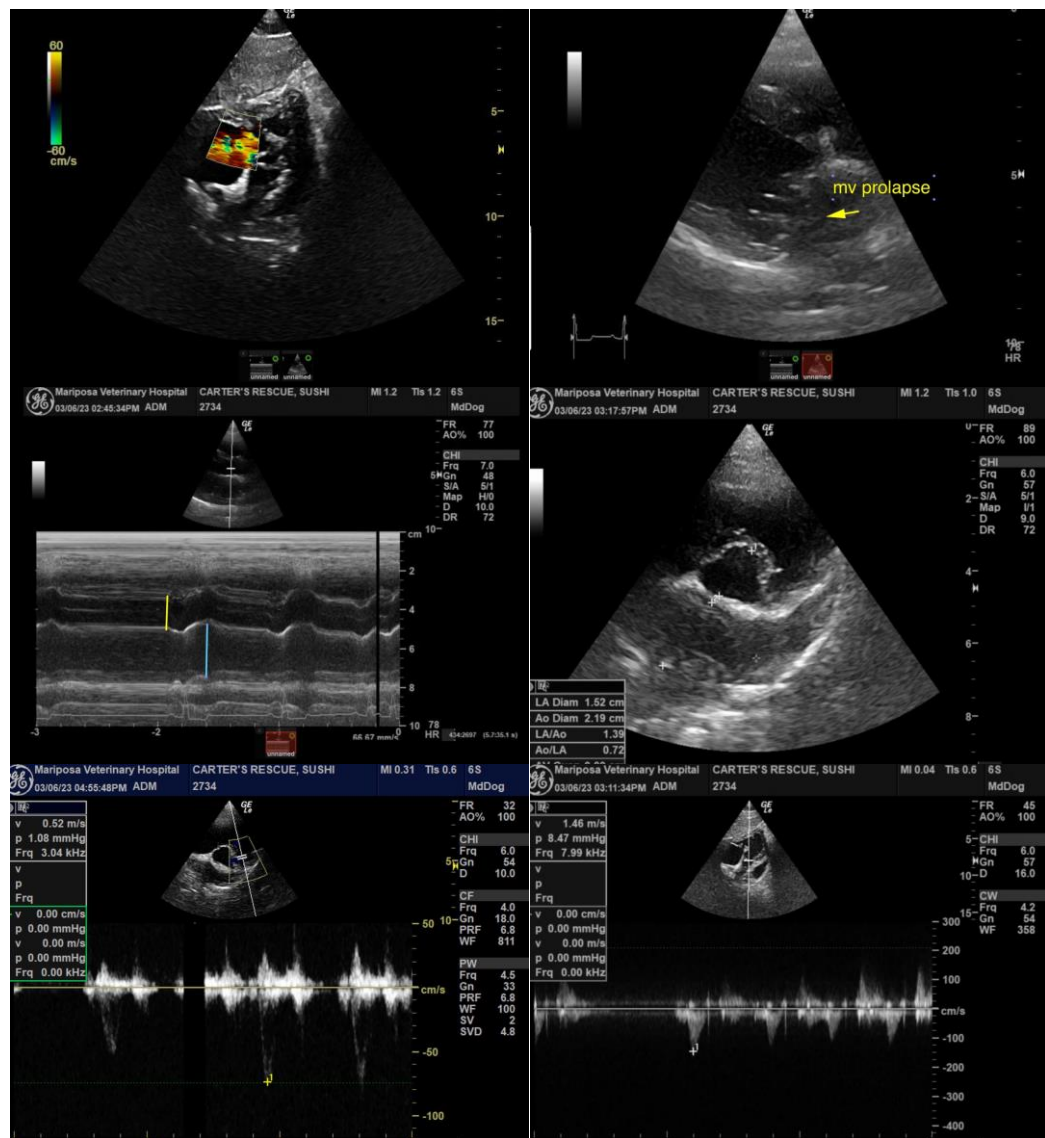
Alan Poon

**INVOICE**

13131ag

**DATE**

03/06/2023





## PATIENT

Sushi Carter's Rescue

## SPECIES

Canine

## BREED

Jack Russell Terrier

## SEX

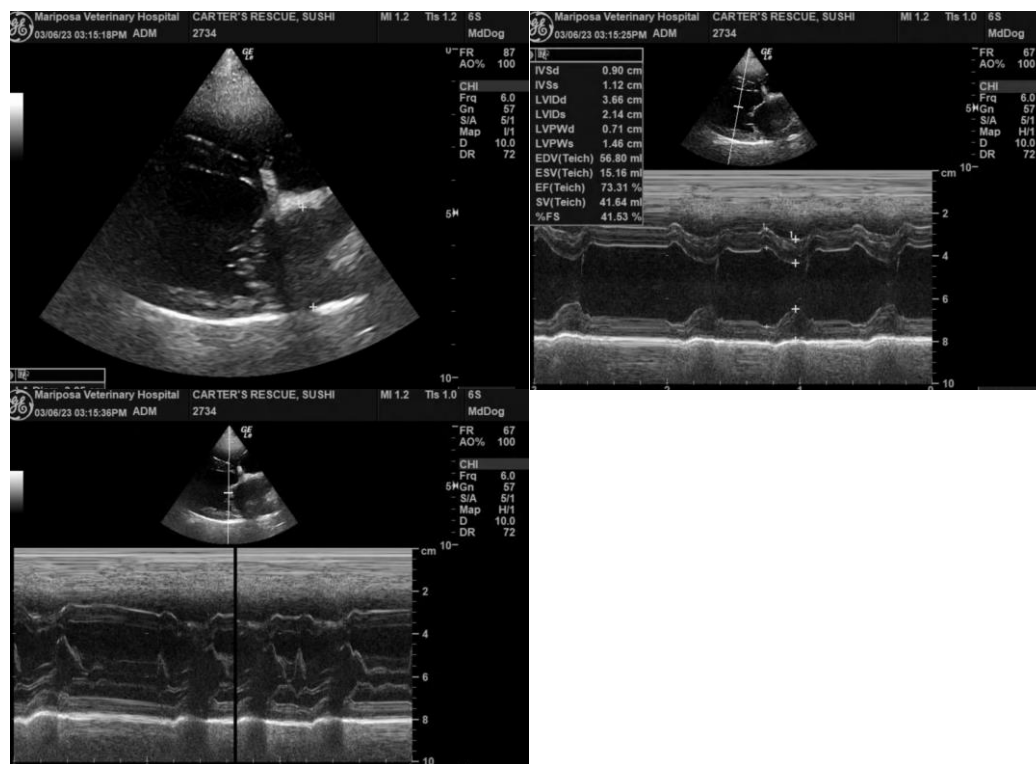
MN

## AGE

10yr

## WEIGHT

9.7kg



## INTERPRETED BY

Eric Lindquist, DMV  
DABVP, Cert. IVUSS

## IMAGING PERFORMED BY

Elyse Hauer

## HOSPITAL NAME

Mariposa Veterinary  
Hospital

## REFERRING VET

Alan Poon

## INVOICE

13131ag

## DATE

03/06/2023

The information and recommendations provided are based on the images presented by the referring veterinarian/sonographer. No evaluation can be communicated regarding pathology that was not visible in the image/video clips provided.

Thank you for this referral. If the clinical or image interpretation does not parallel your findings or if I can be of any further assistance, please contact me.

Eric Lindquist, DMV, DABVP, Cert. IVUSS, CEO of SonoPath.com  
Eric.Lindquist@SonoPath.com