


PATIENT

Isabella Lattig

PRESENTING CLINICAL SIGNS

History: 6 month re check No issues at home dog is doing well

SPECIES

Canine

BREED

Shih Tzu

SEX

Spayed Female

AGE

11

WEIGHT

10.3

ULTRASONOGRAPHIC EXAMINATION OF THE HEART

CANINE CARDIAC PARAMETERS	MR VMAX (m/s)	TR VMAX (m/s)	LA/AO (Boon method)	LA/AO (Heart Base; Swe)	FS (%)	EF (%)	EPSS (cm)
NORMAL PARAMETER	4.5-5.5	<2.7	1.3	<1.3	28-40	40-100	<0.6
PATIENT	--	--	1.15	1.6	45	--	NM
CANINE CARDIAC PARAMETERS	HR (BPM)	AV VMAX (m/s)	PV MAX (m/s)	BODY WEIGHT (kg)	LA 2D short axis Base view (cm)	LVIDd Avg; 2D and m-mode short axis (cm)	LVIDs Avg; 2D and m-mode short axis (cm)
NORMAL PARAMETER	50-100	0.7-1.7	0.7-1.6				
PATIENT	--	1.00	.74	--	--	2.2	--

Cardiac Presentation

Prolapse of the anterior mitral valve leaflet was noted. The left atrium, in the LA max position, was slightly enlarged. LA/AO heart base and June Boon were unremarkable. The left ventricular internal diameter was unremarkable. Mitral insufficiency was present and persistent. Trivial tricuspid insufficiency was noted. The right ventricular outflow tract and pulmonary artery were unremarkable. The pericardium was unremarkable.

INTERPRETED BY

 Eric Lindquist, DMV
 DABVP, Cert. IVUSS

IMAGING PERFORMED BY

Jenn

HOSPITAL NAME

Rockaway AH

REFERRING VET

Dr. Kahn

INVOICE

21473

DATE

3/6/23

ULTRASONOGRAPHIC FINDINGS

- Stable valvular disease

INTERPRETATION OF THE FINDINGS & FURTHER RECOMMENDATIONS

I recommend continuation of the current protocol. Blood pressure measurements are warranted. Recheck echo in 6 months.



PATIENT

Isabella Lattig

SPECIES

Canine

BREED

Shih Tzu

SEX

Spayed Female

AGE

11

WEIGHT

10.3

INTERPRETED BY

Eric Lindquist, DMV
DABVP, Cert. IVUSS

IMAGING PERFORMED BY

Jenn

HOSPITAL NAME

Rockaway AH

REFERRING VET

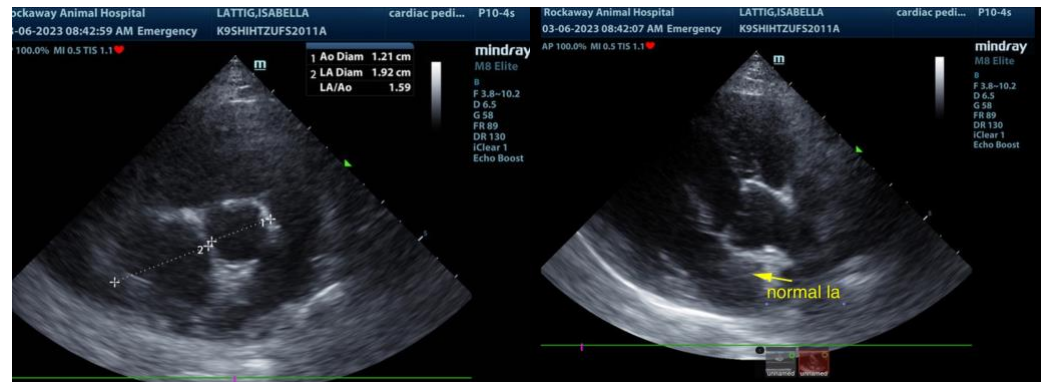
Dr. Kahn

INVOICE

21473

DATE

3/6/23



The information and recommendations provided are based on the images presented by the referring veterinarian. No evaluation can be communicated regarding pathology that was not visible in the image/video clips provided.

Thank you for this referral. If the clinical or image interpretation does not parallel your findings or if I can be of any further assistance please contact me.

Eric Lindquist, DMV, DABVP, Cert. IVUSS, CEO of SonoPath.com
info@SonoPath.com