



**PATIENT**

Dana Martorelli

**SPECIES**

Canine

**BREED**

Maltese Mix

**SEX**

Spayed Female

**AGE**

13

**WEIGHT**

8.6

**INTERPRETED BY**

Eric Lindquist, DMV  
DABVP, Cert. IVUSS

**IMAGING PERFORMED BY**

Jenn

**HOSPITAL NAME**

Rockaway AH

**REFERRING VET**

Dr. Gannon

**INVOICE**

21475

**DATE**

3/6/23

**PRESENTING CLINICAL SIGNS**

Hx of liver masses, owner feels pet is gaining weight Treating for PLN Current meds Telmisartan 7.5mg qD Clopidogrel 18.75mg

Abnormal PE/Chem/CBC/UA Results: Proteinuria

**ULTRASONOGRAPHIC EXAMINATION OF THE ABDOMEN**

**Urinary System**

The **urinary bladder**, trigone, and pelvic urethra presented normal thicknesses and normal tone. The ureters were not visible which is normal. No uroliths or sediment were visualized and anechoic urine was present. No evidence of inflammatory or neoplastic changes were noted. Ureteral papillae were normal. The pelvic urethra was imaged 3.0 cm beyond the cystourethral junction.

The **kidneys** revealed largely normal size and structure, corticomedullary definition and ratio (cortex 1/3 of medulla) were essentially maintained with some moderate age-related loss of curvilinear patterns regarding the capsule and C/M junction. The cortices presented largely uniform texture with some increased echogenicity expected for his age patient. Medullary structure differed distinctly from that of the cortex and no evidence of pelvic dilation was present. Mineralization was present in the kidneys. The right kidney measured 3.83 cm The left kidney measured 4.14 cm.

**Adrenal Glands**

Both **adrenal glands** were visualized and recognized as having normal shape, size, position and echogenicity for this breed. The phrenic vasculature, glandular echogenicity and detail were unremarkable. Capsule, cortex, and medullary definition were normal for this age patient. The left adrenal gland measured 2.01 cm x 0.61 cm at the caudal pole and 0.76 cm at the cranial pole. The right adrenal gland measured 1.97 cm x 1.06 cm at the cranial pole and 0.49 cm at the caudal pole.

**Spleen**

The **spleen** presented a smooth homogeneous parenchyma hyperechoic to liver and renal cortical parenchyma. The capsule was smooth without noticeable expansion or deviation from within the spleen or adjacent pathology. The splenic vasculature demonstrated normal volume without signs of congestion or thrombosis. No sonographic evidence of acute or chronic inflammatory, neoplastic, or infarctual changes were noted.

**Liver**

The **liver** revealed multifocal isoechoic masses most consistent with benign hepatomas, however, carcinoma cannot be completely ruled out- FNA is indicated. Other heterogenous parenchyma changes were noted. Gallbladder polyps were present.

**Gastrointestinal**

Examination of the **gastrointestinal tract** revealed a stomach and intestine free of stasis, of normal wall thickness, acceptable curvilinear mural detail, and peristaltic activity. Small intestine demonstrated normal luminal chyme. No obstructive or overt infiltrative disease was noted. No associated abnormal lymphatic activity was noted. Soft stool was noted in the colon.

**Pancreas**



**PATIENT**

Dana Martorelli

The base and limbs of the **pancreas** were observed to be largely isoechoic to surrounding omental fat. Pancreatic duct and capsular contour were acceptably normal and parenchyma respected normal curvilinear patterns. No overt evidence of active inflammatory or neoplastic disease was noted.

**SPECIES**

Canine

**ULTRASONOGRAPHIC FINDINGS**

- Hepatoma type hepatic masses, subjectively benign or low grade- FNA is warranted
- Soft stool in the colon
- Age-related renal changes with mineralization
- Unremarkable abdomen otherwise

**BREED**

Maltese Mix

**INTERPRETATION OF THE FINDINGS & FURTHER RECOMMENDATIONS**

**SEX**

Bile acid profile would be ideal.

Spayed Female

**AGE**

13

**WEIGHT**

8.6

**INTERPRETED BY**

Eric Lindquist, DMV  
DABVP, Cert. IVUSS

**IMAGING PERFORMED BY**

Jenn

**HOSPITAL NAME**

Rockaway AH

**REFERRING VET**

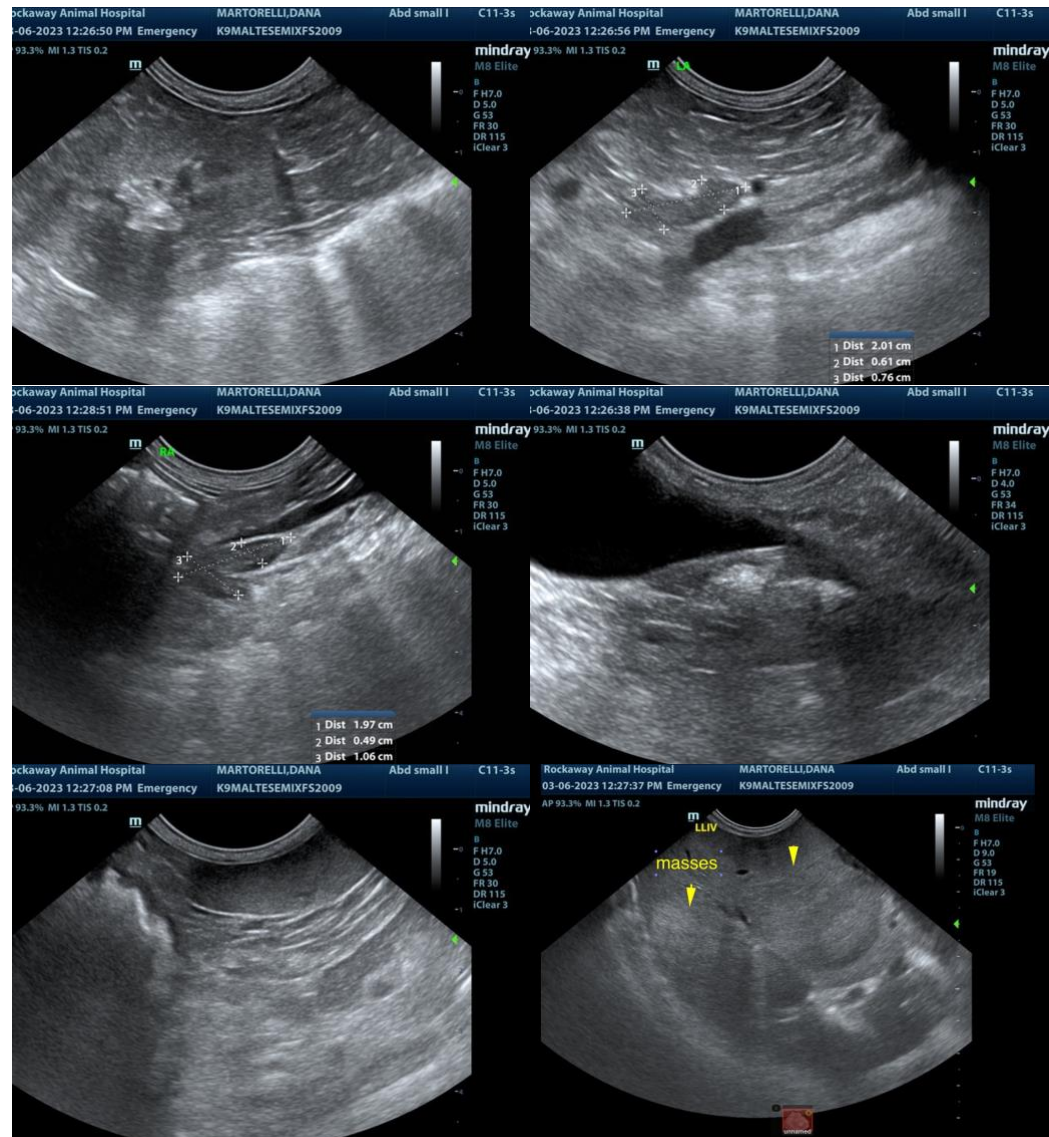
Dr. Gannon

**INVOICE**

21475

**DATE**

3/6/23





**PATIENT**

Dana Martorelli

**SPECIES**

Canine

**BREED**

Maltese Mix

**SEX**

Spayed Female

**AGE**

13

**WEIGHT**

8.6

**INTERPRETED BY**

Eric Lindquist, DMV  
DABVP, Cert. IVUSS

**IMAGING PERFORMED BY**

Jenn

**HOSPITAL NAME**

Rockaway AH

**REFERRING VET**

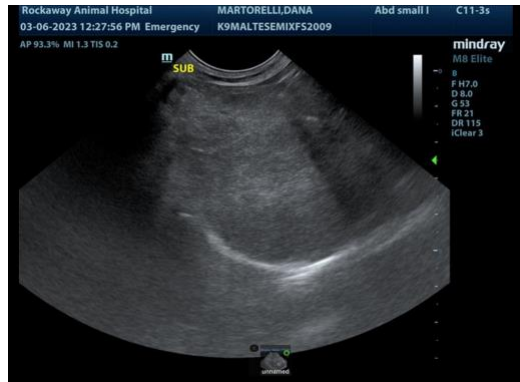
Dr. Gannon

**INVOICE**

21475

**DATE**

3/6/23



The information and recommendations provided are based on the images presented by the referring veterinarian. No evaluation can be communicated regarding pathology that was not visible in the image/video clips provided.

Thank you for this referral. If the clinical or image interpretation does not parallel your findings or if I can be of any further assistance please contact me.

**Eric Lindquist**, DMV, DABVP, Cert. IVUSS, CEO of SonoPath.com  
info@SonoPath.com