



**PATIENT PRESENTING CLINICAL SIGNS**

**PATIENT**  
Buster Fagnan  
History: Grade 1-2/6 murmur. Asymptomatic  
BP 157/111(128),158/109(132),161/112(126)

**SPECIES**

Canine

**BREED**

Jack Russell

**SEX**

Neutered male

**AGE**

12 years

**WEIGHT**

15 lbs

**INTERPRETED BY**

Eric Lindquist, DMV  
DABVP, Cert. IVUSS

**IMAGING PERFORMED BY**

JK

**HOSPITAL NAME**

Hamburg VC

**REFERRING VET**

Dr. Martens

**ULTRASONOGRAPHIC EXAMINATION OF THE HEART**

The echocardiogram in this patient demonstrated normal **left atrial** size based on 3 separate methods of LA evaluation. The **mitral** valve was slightly thickened with trivial insufficiency. The **left ventricle** presented thicknesses with linear contour and was not dilated nor restricted. The **myocardium** presented normal echogenicity without subjective evidence of significant fibrotic or ischemic disease. **Contractility** of the ventricular walls was adequate and in normal range for this patient evidenced by the fractional shortening measurement and subjective evaluation of the different regions of the myocardium. The **left ventricular outflow** tract demonstrated normal laminar flow and subjective structural integrity. The **right atrium** and auricle revealed normal size, structure and content. No evidence of masses was noted. **Tricuspid** valvular assessment demonstrated adequate linear morphology and kinesis. The **right ventricle** was of normal size (1/3 diameter of LV), chordae structure, myocardial echogenicity and thickness. **Pulmonary outflow** tract assessment revealed normal valve structure, laminar flow, and diameter (approx.1:1 pa/ao ratio). No visible **pericardial** or free pleura fluid was noted. The cranial **mediastinum and pericardial and extra-cardiac regions** were free of masses in the visible window.

| CANINE CARDIAC PARAMETERS | MR VMAX (m/s) | TR VMAX (m/s) | LA/AO (Boon method) | LA/AO (Heart Base) | FS (%)                            | EF (%)                                     | EPSS (cm)                                  |
|---------------------------|---------------|---------------|---------------------|--------------------|-----------------------------------|--|--|
| NORMAL PARAMETER          | 4.5-5.5       | <2.7          | 1.3                 | <1.6               | 28-40                             | 40-100                                     | <0.6                                       |
| PATIENT                   |               |               | NM                  | 1.54               | 48                                | 81   | 0.2  |
| CANINE CARDIAC PARAMETERS | HR (BPM)      | AV VMAX (m/s) | PV MAX (m/s)        | BODY WEIGHT        | LA (2D short axis Base view) (cm) | LVIDd (Avg; 2D and m-mode short axis) (cm) | LVIDs (Avg; 2D and m-mode short axis) (cm) |
| NORMAL PARAMETER          | 50-100        | 0.7-1.7       | 0.7-1.6             | BELOW              | BELOW                             | BELOW                                      | BELOW                                      |
| PATIENT                   | 144           | 1.11          | 0.8                 | 15 lbs             | 2.9 max                           | 2.7  |  |

**ULTRASONOGRAPHIC FINDINGS**

**INVOICE**  
43116  
Trivial mitral insufficiency, not clinically significant.  
Otherwise essentially normal echocardiogram.

**DATE**

3/6/23



**PATIENT**

Buster Fagnan

**SPECIES**

Canine

**BREED**

Jack Russell

**SEX**

Neutered male

**AGE**

12 years

**WEIGHT**

15 lbs

**INTERPRETED BY**

Eric Lindquist, DMV  
DABVP, Cert. IVUSS

**IMAGING PERFORMED BY**

JK

**HOSPITAL NAME**

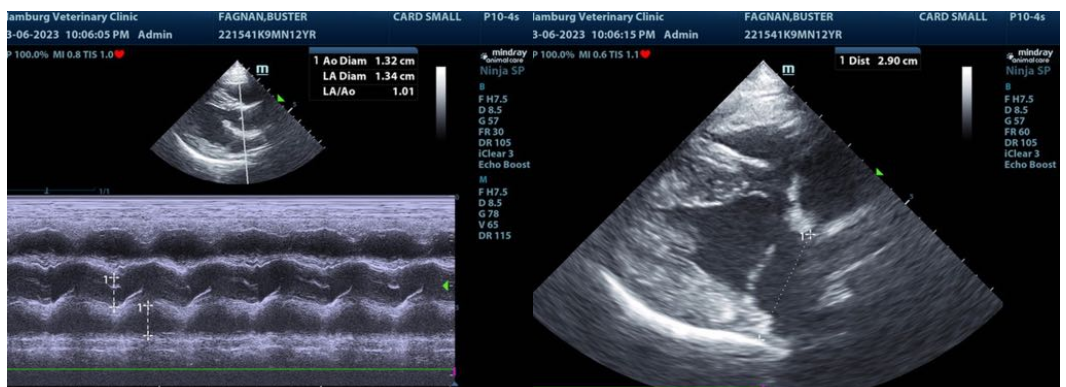
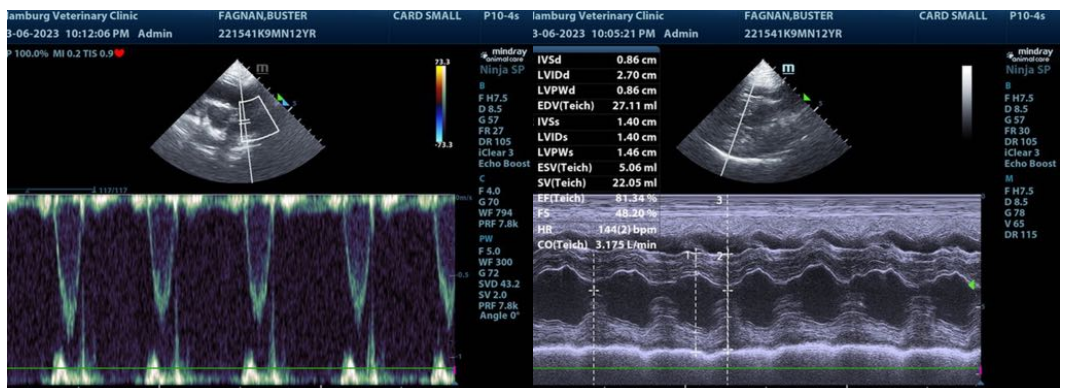
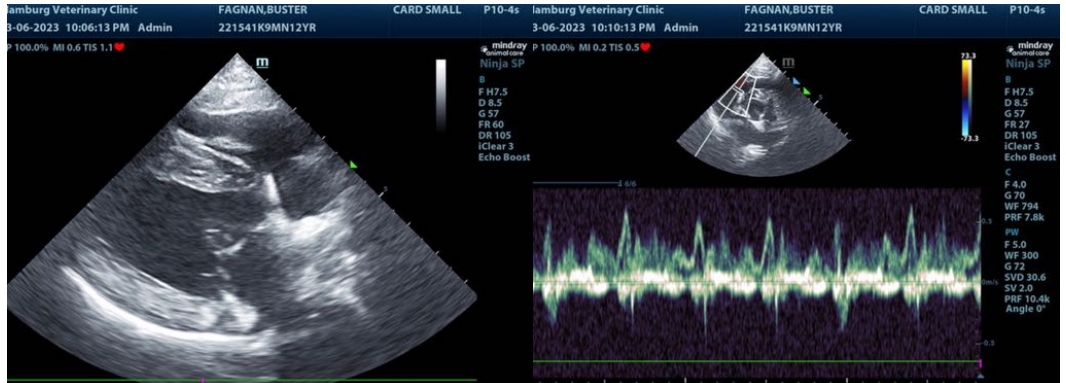
Hamburg VC

**REFERRING VET**

Dr. Martens

**INTERPRETATION OF THE FINDINGS & FURTHER RECOMMENDATIONS**

No specific therapy is recommended. A recheck is recommended in a year or earlier if murmur grade increases.



**INVOICE**

43116

**DATE**

3/6/23



**PATIENT**

Buster Fagnan

**SPECIES**

Canine

**BREED**

Jack Russell

**SEX**

Neutered male

**AGE**

12 years

**WEIGHT**

15 lbs

**INTERPRETED BY**

Eric Lindquist, DMV  
DABVP, Cert. IVUSS

**IMAGING PERFORMED BY**

JK

**HOSPITAL NAME**

Hamburg VC

**REFERRING VET**

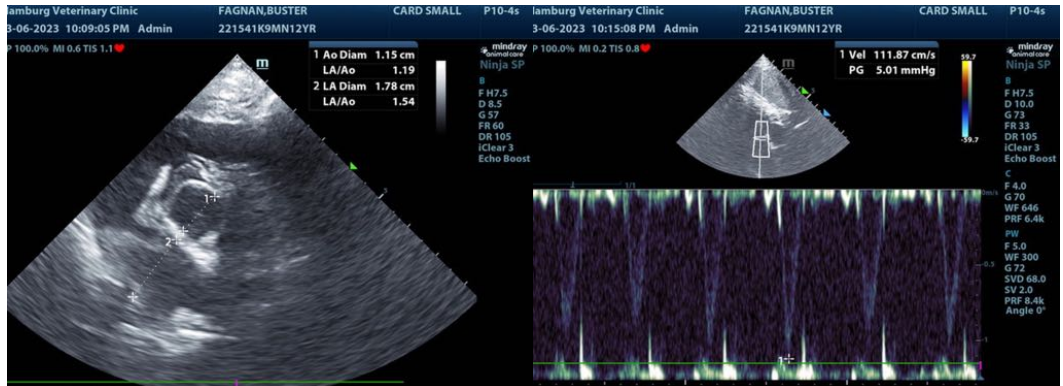
Dr. Martens

**INVOICE**

43116

**DATE**

3/6/23



The information and recommendations provided are based on the images presented by the referring veterinarian/sonographer. No evaluation can be communicated regarding pathology that was not visible in the image/video clips provided.

Thank you for this referral. If the clinical or image interpretation does not parallel your findings or if I can be of any further assistance please contact me.

**Eric Lindquist, DMV, DABVP, Cert. IVUSS, CEO of SonoPath.com**  
info@SonoPath.com