



PATIENT

Itchy Yonskie

SPECIES

Canine

BREED

Dachshund Mix

SEX

Spayed female

AGE

14 years

WEIGHT

15.8 lbs

INTERPRETED BY

Eric Lindquist, DMV
DABVP, Cert. IVUSS

IMAGING PERFORMED BY

Dr. Anthony Smatt

HOSPITAL NAME

The Pets I Love

REFERRING VET

Dr. Szpicek

INVOICE

72236

DATE

3/5/26

PRESENTING CLINICAL SIGNS

- Patient came in for QOL for 2 months. PU/PD. Occasional vomiting, GI signs. History of heart murmur. Mandibular lymph node is enlarged. Hyperparathyroidism diagnosed 5/2025.

ULTRASONOGRAPHIC EXAMINATION OF THE THYROID

A hypoechoic nodule that measured 0.64 x 0.43 cm was noted at the cranial pole of the left thyroid lobe. This is consistent with thyroid adenoma. The remainder of the left thyroid gland was unremarkable with uniform parenchyma. The salivary glands, esophagus and regional tissue is unremarkable.

The region of the right thyroid lobe revealed an irregular, mineralized tissue. This cannot be definitively defined as thyroid tissue. However, it should be monitored and measured 1.1 x 0.8 cm.

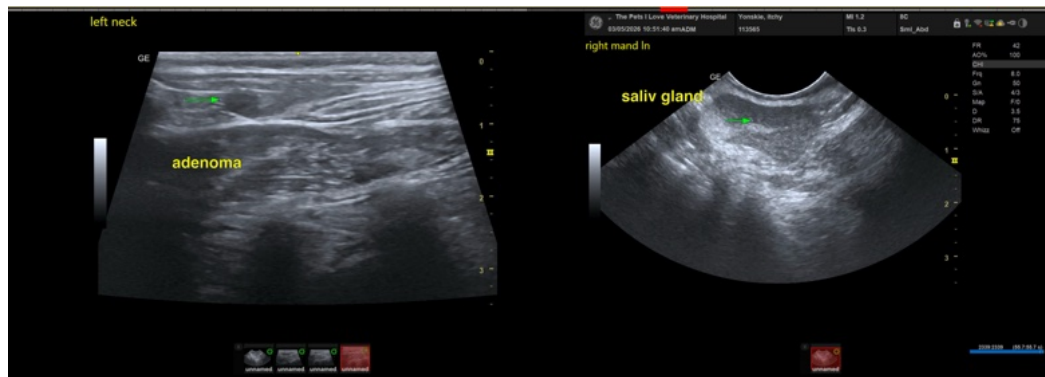ULTRASONOGRAPHIC FINDINGS

Left cranial parathyroid adenoma.

Mineralized tissue in the region of the right thyroid lobe.

INTERPRETATION OF THE FINDINGS & FURTHER RECOMMENDATIONS

CT would be ideal for surgical planning given the bilateral pathology.





PATIENT

Itchy Yonskie

SPECIES

Canine

BREED

Dachshund Mix

SEX

Spayed female

AGE

14 years

WEIGHT

15.8 lbs

INTERPRETED BY

Eric Lindquist, DMV
DABVP, Cert. IVUSS

IMAGING PERFORMED BY

Dr. Anthony Smatt

HOSPITAL NAME

The Pets I Love

REFERRING VET

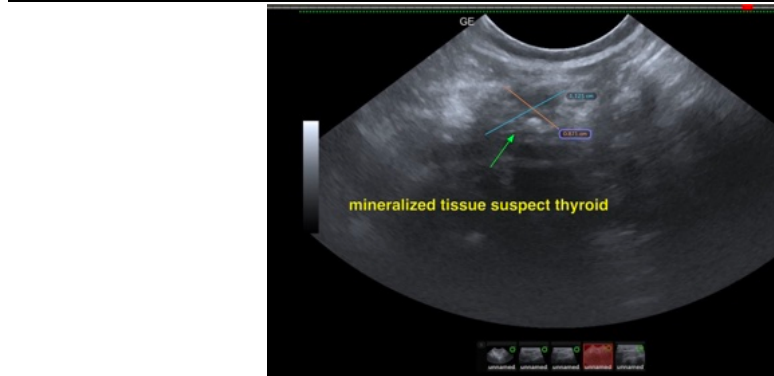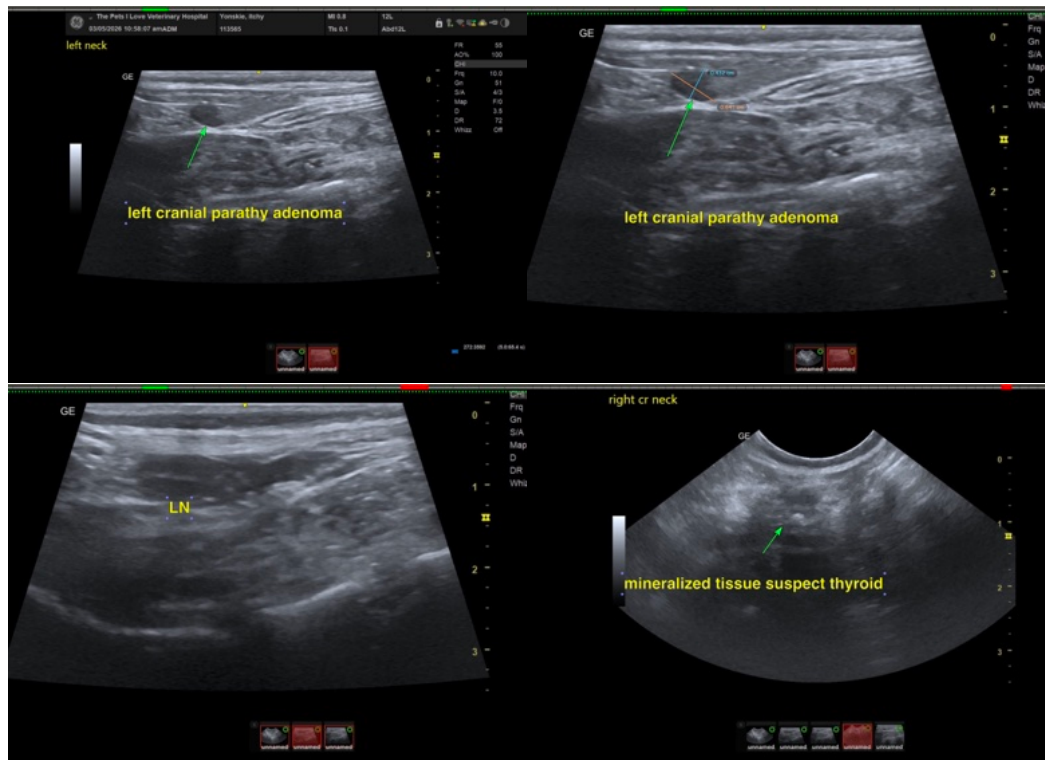
Dr. Szpicek

INVOICE

72236

DATE

3/5/26



The information and recommendations provided are based on the images presented by the referring veterinarian/sonographer. No evaluation can be communicated regarding pathology that was not visible in the image/video clips provided.

Thank you for this referral. If the clinical or image interpretation does not parallel your findings or if I can be of any further assistance please contact me.

Eric Lindquist, DMV, DABVP (CFM), Cert. IVUSS, CEO of SonoPath.com

info@SonoPath.com