



PATIENT

Emmi Takehara

SPECIES

Canine

BREED

Chihuahua

SEX

Spayed Female

AGE

16 Years

WEIGHT

12 Lbs.

INTERPRETED BY

Eric Lindquist, DMV
DABVP, Cert. IVUSS

IMAGING PERFORMED BY

Dallas Reynolds

HOSPITAL NAME

Lone Mtn. AH

REFERRING VET

Dr. Munoz

INVOICE

14194

DATE

3/5/22

PRESENTING CLINICAL SIGNS

History: Low BG on bloodwork. Glucose/insulin ratio suggestive of insulinoma. P has a history of heart murmur and currently on Vetmedin.

ULTRASONOGRAPHIC EXAMINATION OF THE ABDOMEN

Urinary System

The **urinary bladder**, trigone, and pelvic urethra presented normal thicknesses and normal tone. The ureters were not visible which is normal. No uroliths or sediment were visualized and anechoic urine was present. No evidence of inflammatory or neoplastic changes were noted. Ureteral papillae were normal.

The **kidneys** revealed largely normal size and structure, corticomedullary definition and ratio (cortex 1/3 of medulla) were essentially maintained with some mild age-related loss of curvilinear patterns regarding the capsule and C/M junction. The cortices presented largely uniform texture with some increased echogenicity expected for his age patient. Medullary structure differed distinctly from that of the cortex and no evidence of pelvic dilation was present. The right kidney measured 4.0 cm. The left kidney measured 4.0 cm.

Adrenal Glands

The region of the **right adrenal gland** was unremarkable.
The **left adrenal gland** was slightly enlarged, measuring 0.7 cm.

Spleen

The **spleen** presented a smooth homogeneous parenchyma hyperechoic to liver and renal cortical parenchyma. The capsule was smooth without noticeable expansion or deviation from within the spleen or adjacent pathology. The splenic vasculature demonstrated normal volume without signs of congestion or thrombosis. No sonographic evidence of acute or chronic inflammatory, neoplastic, or infarctual changes were noted.

Liver

The **liver** revealed multifocal, hypoechoic nodular changes with disrupted architecture. Given the patient history, metastatic insulinoma is a strong potential. Coalescing nodules created a 2.4 cm left cranial mass as well as multifocal nodules elsewhere, up to 1.2 cm. The gallbladder revealed a minor amount of excessive debris.

Gastrointestinal

Examination of the **gastrointestinal tract** revealed a stomach and intestine free of stasis, of normal wall thickness, acceptable curvilinear mural detail, and peristaltic activity. Small and large intestine demonstrated normal luminal chyme and stool consistency respectively. No obstructive or overt infiltrative disease was noted. No associated abnormal lymphatic activity was noted.

Pancreas

An isoechoic nodule (approximately 7.0 mm) was noted in the right limb of the **pancreas**, this may represent primary lesion. The remainder of the pancreas was unremarkable.



PATIENT

Emmi Takehara

SPECIES

Canine

BREED

Chihuahua

SEX

Spayed Female

AGE

16 Years

WEIGHT

12 Lbs.

INTERPRETED BY

Eric Lindquist, DMV
DABVP, Cert. IVUSS

IMAGING PERFORMED BY

Dallas Reynolds

HOSPITAL NAME

Lone Mtn. AH

REFERRING VET

Dr. Munoz

INVOICE

14194

DATE

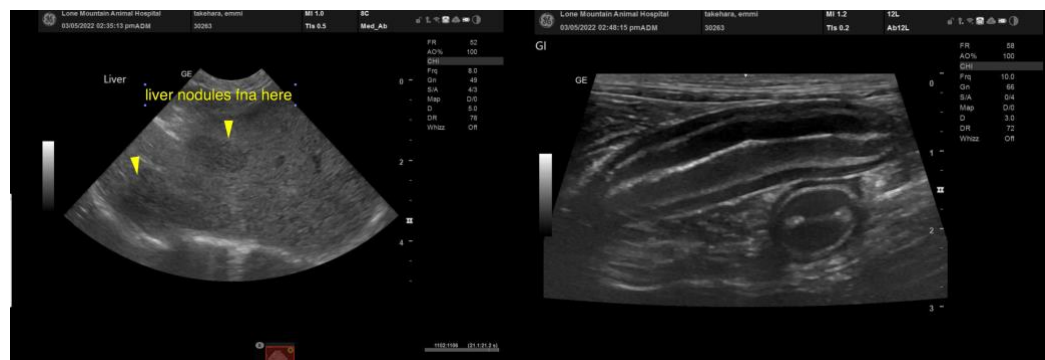
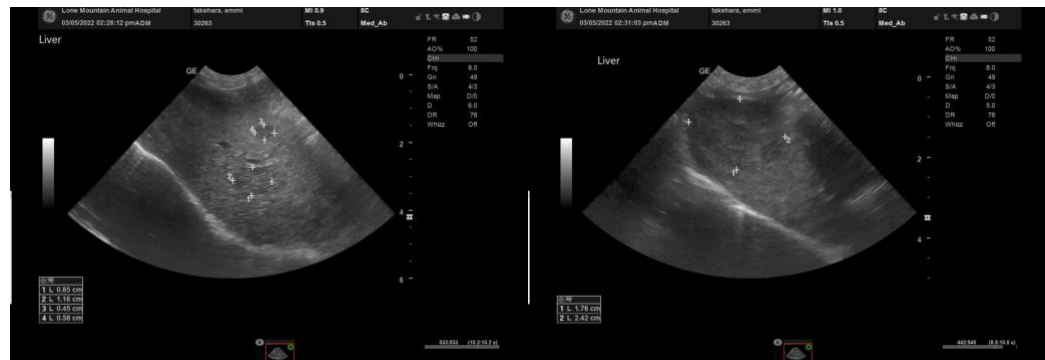
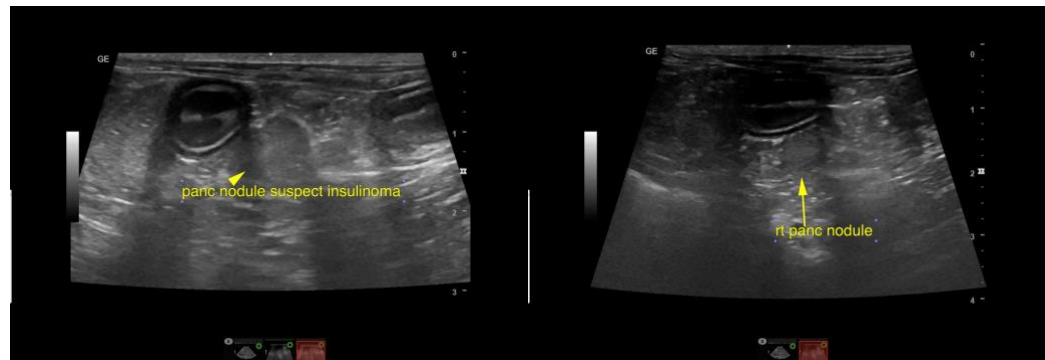
3/5/22

ULTRASONOGRAPHIC FINDINGS

- Undefined hepatic nodules, moderately disruptive, strong potential for metastatic disease
- Minor gallbladder debris
- Pancreatic nodule
- Slightly enlarged left adrenal gland
- Age-related renal changes

INTERPRETATION OF THE FINDINGS & FURTHER RECOMMENDATIONS

Ultrasound guided FNA of the pancreatic nodule and liver nodules warranted for staging purposes.





PATIENT

Emmi Takehara

SPECIES

Canine

BREED

Chihuahua

SEX

Spayed Female

AGE

16 Years

WEIGHT

12 Lbs.

INTERPRETED BY

Eric Lindquist, DMV
DABVP, Cert. IVUSS

IMAGING PERFORMED BY

Dallas Reynolds

HOSPITAL NAME

Lone Mtn. AH

REFERRING VET

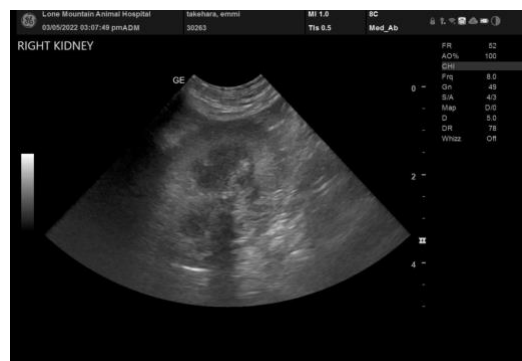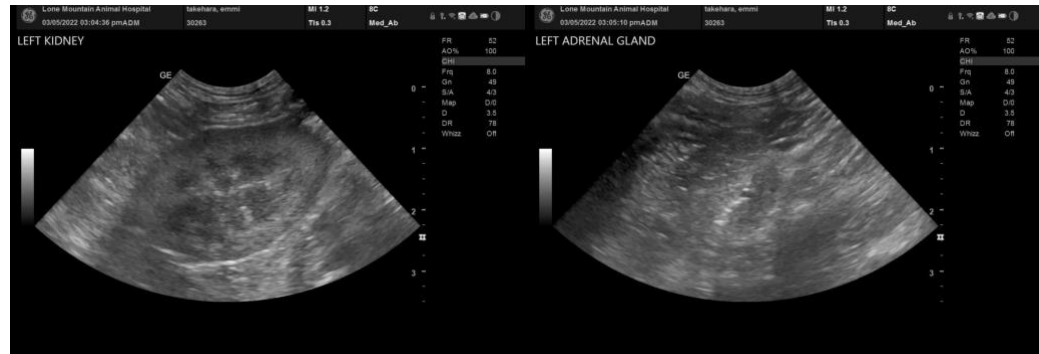Dr. Munoz

INVOICE

14194

DATE

3/5/22




The information and recommendations provided are based on the images presented by the referring veterinarian. No evaluation can be communicated regarding pathology that was not visible in the image/video clips provided.

Thank you for this referral. If the clinical or image interpretation does not parallel your findings or if I can be of any further assistance please contact me.

Eric Lindquist, DMV, DABVP, Cert. IVUSS, CEO of SonoPath.com
info@SonoPath.com

The following is an applicable excerpt from the *Curbside Guide to Diagnosis & Treatment of Sonographic Disease* offered by SonoPath.com Lindquist, Frank, Lobetti, and Modler.

An essential quick guide for every general practitioner and sonographer.





PATIENT

Emmi Takehara

Hypoglycemic Syndrome: Insulinoma and Other

<http://www.sonopath.com/Hypoglycemia>

SPECIES

Canine

BREED

Chihuahua

SEX

Spayed Female

AGE

16 Years

WEIGHT

12 Lbs.

INTERPRETED BY

Eric Lindquist, DMV
DABVP, Cert. IVUSS

IMAGING PERFORMED BY

Dallas Reynolds

HOSPITAL NAME

Lone Mtn. AH

REFERRING VET

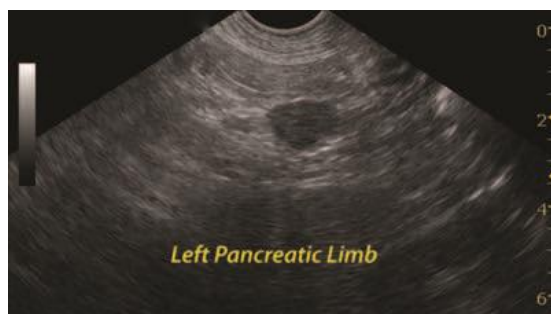Dr. Munoz

INVOICE

14194

DATE

3/5/22



Short axis of the left pancreatic limb in a dog with an insulinoma seen as an ovoid hypoechoic mass lesion expanding the pancreatic capsule.

Description: Hypoglycemia can be found incidentally or associated with non-specific clinical signs, such as listlessness and weakness. It is essential to consider the multiple differentials for hypoglycemia in order to avoid a potential hypoglycemic crisis. One must perform a rapid and efficient workup to arrive at a diagnosis and prescribe the proper therapy.

Differentials for hypoglycemia include: laboratory or handling error; sepsis; toxins (e.g. xylitol, ethylene glycol); hunting dog hypoglycemia; Addison's disease; polycythemia; liver failure; poorly regulated diabetes mellitus; and neoplasia (e.g. leiomyosarcoma, hepatic, lymphoma, and insulinoma).

Once other causes of hypoglycemia have been ruled out, one may initiate an investigation into the possibility of insulinoma. Insulinoma is a tumor of the pancreas that originates in the beta cells and leads to the unregulated secretion of insulin and hypoglycemic syndrome. The tumor can be a malignant carcinoma or a more benign form of adenoma. There is, however, controversy regarding the exact histopathology associated with insulinoma types.

Insulinoma patients are usually middle-aged dogs. Half of all cases present with metastasis to the lymph nodes, liver, and mesentery at the time of diagnosis. There are 3 stages of insulinoma:

Stage 1: Pancreatic localization

Stage 2: Pancreas and lymph nodes with a median survival time (MST) of 1.5 years

Stage 3: Organ metastasis with an MST of 6 months.



PATIENT

Emmi Takehara

Clinical Signs: Neuroglycopenia syndrome results in lethargy, ataxia, collapse, and seizures. Catecholamine release from hypoglycemia leads to hunger, behavior changes, and muscle tremors. Postprandial exacerbation of clinical signs can occur.

SPECIES

Canine

Diagnostics: When investigating for insulinoma, one should use a fluoride-containing tube (i.e., a grey top tube) to obtain an accurate glucose level. A fasting glucose level below 60 mg/dl is diagnostic for hypoglycemia. Insulinoma is indicated when one observes the Whipple's triad of hypoglycemia, clinical signs consistent are with hypoglycemia, and the latter resolve with the administration of dextrose.

BREED

Chihuahua

SEX

Spayed Female

Fasting insulin and glucose ratio: A high normal to elevated insulin level with glucose < 60 mg/dl is diagnostic for insulinoma.

AGE

16 Years

Imaging: Localizing the lesion with staging is best approached by ultrasound. The ability to localize the lesion may be highly operator- and/or machine-dependent given the often small or even microscopic nature of insulinoma, especially early on in the disease. Primary or secondary lesions associated with insulinoma can often be identified with higher resolution sonography. Appropriate ultrasound-guided sampling (FNA or core biopsy) can be performed of any enlarged lymph node or hepatic nodule if a primary pancreatic lesion is not seen.

WEIGHT

12 Lbs.

INTERPRETED BY

Eric Lindquist, DMV
DABVP, Cert. IVUSS

Computed tomography (CT) with contrast is likely more sensitive than the average sonographer when it comes to assessing insulinoma.

IMAGING PERFORMED BY

Dallas Reynolds

Tumor staging and histopathological characterization in conjunction with the Ki67 biomarker index will yield solid criteria for the prognostic evaluation of insulinoma.

HOSPITAL NAME

Lone Mtn. AH

Treatment:

In cases of emergency hypoglycemic crisis, apply corn syrup to the gums. Administer a dextrose bolus (0.5g/kg IV) and maintain 2.5-10% dextrose solution. If cerebral edema occurs, one should administer dexamethasone (2 mg/kg IV) and give mannitol (0.5 mg/kg IV) over a 20-minute period.

REFERRING VET

Dr. Munoz

One should perform a surgical pancreatectomy if the tumor is localized (i.e., stage 1 insulinoma). Given that the lesion may be difficult to locate with the naked surgical eye or via palpation, the surgical procedure can be enhanced by intraoperative ultrasound.

INVOICE

14194

DATE

3/5/22

In cases of stage 2 and 3 insulinoma, administer prednisolone (0.25 mg/kg PO BID). A glucagon IV infusion has also been suggested; it should be infused with saline at 5 mg/kg/min for refractory cases. If prednisone is not adequate, one can supplement with benzothiadiazide diazoxide (5 mg/kg PO BID).



PATIENT

Emmi Takehara

Patients should be fed small, frequent portions of a diet high in fat, complex carbohydrates, and protein.

SPECIES

Canine

Chemotherapy: In some cases, the use of alloxan (65 mg/ kg IV) has been shown to be helpful.

BREED

Chihuahua

Conclusion: The largest study of insulinoma patients identified a general MST of 547 days; however, the MST was 785 days for those undergoing pancreatectomy and 1316 days for those that relapsed after surgery and received treatment with prednisone. Other studies have reported an MST of 258 days with pancreatectomy. All of these results indicate that insulinoma is treatable. Using ultrasonography for staging and histopathological characterization is essential in order to determine whether the appropriate treatment should be surgical, medical, or both.

SEX

Spayed Female

AGE

16 Years

Short axis of the left pancreatic limb in a cat with an insulinoma seen as a complex heterogenous mass lesion expanding the pancreatic capsule (between calipers). Note the mass effect of the tumor displacing the transverse colon caudally.

WEIGHT

12 Lbs.

INTERPRETED BY

Eric Lindquist, DMV
DABVP, Cert. IVUSS

IMAGING PERFORMED BY

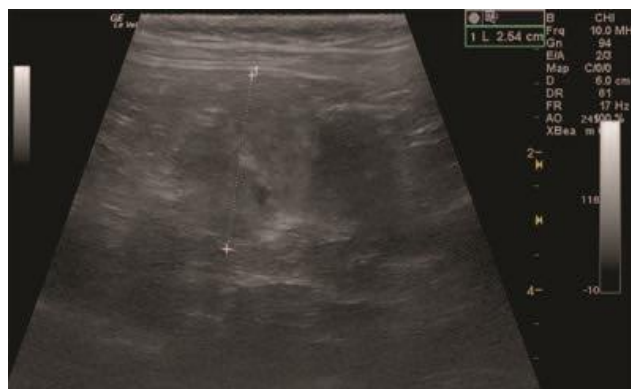Dallas Reynolds

HOSPITAL NAME

Lone Mtn. AH

REFERRING VET

Dr. Munoz

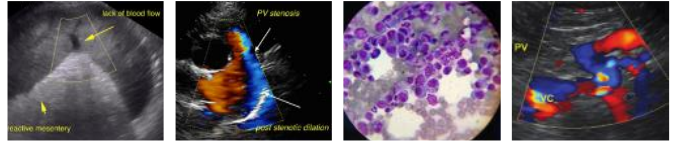


INVOICE

14194

DATE

3/5/22



PATIENT

Emmi Takehara

SPECIES

Canine

BREED

Chihuahua

SEX

Spayed Female

AGE

16 Years

WEIGHT

12 Lbs.

INTERPRETED BY

Eric Lindquist, DMV
DABVP, Cert. IVUSS

IMAGING PERFORMED BY

Dallas Reynolds

HOSPITAL NAME

Lone Mtn. AH

REFERRING VET

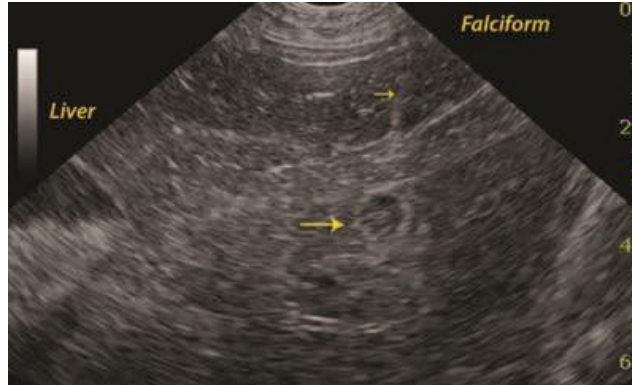Dr. Munoz

INVOICE

14194

DATE

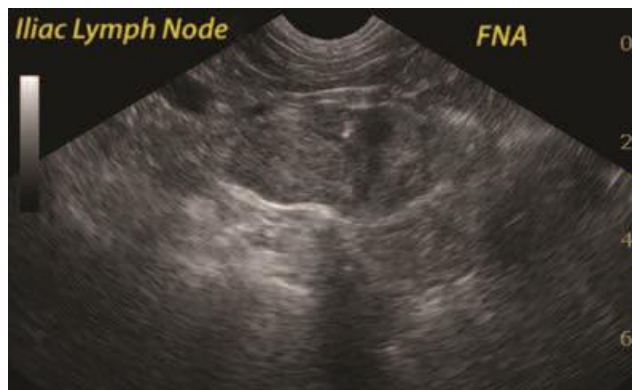
3/5/22



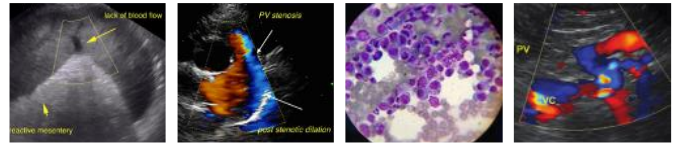
Subxiphoidal short axis of the liver in a dog with an insulinoma during ultrasound guided sampling of a suspected metastatic lesion.

The needle trajectory is seen as a hyperechoic line (small arrow) approaching the hypoechoic nodule (large arrow) within the liver parenchyma.

Long axis of the medial iliac lymph node during needle aspiration in a dog with multifocal metastatic spread of an insulinoma. The echogenic needle tip is seen within the lymph node. The metastatic lymph node is enlarged, rounded, hypoechoic and heterogenous. The primary metastatic loci in insulinoma are the regional lymph nodes (hepatic, pancreaticoduodenal, gastric) and the liver. Hence, metastatic insulinoma lesions in the iliac lymph node in this case was not a typical occurrence.



References:



PATIENT

Buishand FO, Kik M, Kirpensteijn J. Evaluation of clinico-pathological criteria and the Ki67 index as prognostic indicators in canine insulinoma. *Vet J* 2010;185:62-67.

Emmi Takehara

SPECIES

Fischer JR, Smith SA, Harkin KR: Glucagon constant-rate infusion: A novel strategy for management of hyperinsulinemic-hypoglycemia crisis in the dog. *J Am Anim Hosp Assoc* 2000;36:27-32.

Canine

BREED

Polton GA, White RN, Brearley MJ, et al. Improved survival in a retrospective cohort of 28 dogs with insulinoma. *J Small Anim Pract* 2000;48:151-56.

Chihuahua

Steiner JM, Bruyette DS: Canine insulinoma. *Compend Contin Educ Pract Vet* 1996;18:31-36.

SEX

Tobin RL, Nelson RW, Lucroy MD, et al. Outcome of surgical versus medical treatment of dogs with beta cell neoplasia: 39 cases (1990-1997). *JAVMA* 1999;215:226-30.

Spayed Female

AGE

16 Years

WEIGHT

12 Lbs.

INTERPRETED BY

Eric Lindquist, DMV
DABVP, Cert. IVUSS

**IMAGING
PERFORMED BY**

Dallas Reynolds

HOSPITAL NAME

Lone Mtn. AH

REFERRING VET

Dr. Munoz

INVOICE

14194

DATE

3/5/22