



PATIENT

The Dude Markowitz

SPECIES

Feline

BREED

DSH

SEX

Neutered Male

AGE

15 Years

WEIGHT

10.65 lbs

INTERPRETED BY

Eric Lindquist, DMV,
DABVP (CFM), Cert.
IVUSS

IMAGING PERFORMED BY

Dr. Celene Hendricks

HOSPITAL NAME

Grove Small Animal
Hospital

REFERRING VET

Dr. Celene Hendricks

INVOICE

73391

DATE

3/4/26

PRESENTING CLINICAL SIGNS

Progressive weight loss over the past year. March 2025 was 13#, weight 2/25/26 was 10.6#. Well managed hyperthyroid.

Abnormal PE/Chem/CBC/UA Results: Last labwork 2/13/26 -psl 41 (8-26) cpk 850 (56-529) bun 44 (14-36) T4 1.9

ULTRASONOGRAPHIC EXAMINATION OF THE ABDOMEN

Urinary System

The **urinary bladder**, trigone, and pelvic urethra presented normal thicknesses and normal tone. The ureters were not visible which is normal. No uroliths or sediment were visualized and anechoic urine was present. No evidence of inflammatory or neoplastic changes were noted. Ureteral papillae were normal. The pelvic urethra was imaged 1.0 cm beyond the cystourethral junction.

The **kidneys** revealed largely normal size and structure, corticomedullary definition and ratio (cortex 1/3 of medulla) were essentially maintained with some age-related loss of curvilinear patterns regarding the capsule and C/M junction. The cortices presented largely uniform texture with some increased echogenicity expected for his age patient. Medullary structure differed distinctly from that of the cortex and no evidence of pelvic dilation was present. Right kidney measured 3.8 cm. Left kidney measured 3.3 cm. Pinpoint mineralizations noted in both kidneys, non-obstructive.

Adrenal Glands

The regions of the **adrenal glands** were unremarkable.

Spleen

The **spleen** presented a smooth homogeneous parenchyma hyperechoic to liver and renal cortical parenchyma. The capsule was smooth without noticeable expansion or deviation from within the spleen or adjacent pathology. The splenic vasculature demonstrated normal volume without signs of congestion or thrombosis. No sonographic evidence of acute or chronic inflammatory, neoplastic, or infarctual changes were noted.

Liver

The **liver** images from right and left intercostal as well as subcostal views revealed subjectively normal liver size, contour, and structure. Some age-related parenchymal remodeling was noted but likely not clinically significant at this time. Vascular and biliary tracts were of normal volume and no evidence of congestion was noted. The gallbladder presented some dependent debris with essentially normal contour. The cystic and common bile ducts were normal. No overt evidence of active inflammatory, infiltrative or regenerative pathology was noted but should be paired with current or past LE elevations regarding any clinical significance to this presentation. The hepatic lymph nodes were unremarkable.

Gastrointestinal

Examination of the **gastrointestinal tract** revealed a stomach and intestine free of stasis, of normal wall thickness, acceptable curvilinear mural detail, and peristaltic activity. Small and large intestine demonstrated normal luminal chyme and stool consistency respectively. No obstructive or overt infiltrative disease was noted. No associated abnormal lymphatic activity was noted.



PATIENT

The Dude Markowitz

SPECIES

Feline

BREED

DSH

SEX

Neutered Male

AGE

15 Years

WEIGHT

10.65 lbs

INTERPRETED BY

Eric Lindquist, DMV,
DABVP (CFM), Cert.
IVUSS

IMAGING PERFORMED BY

Dr. Celene Hendricks

HOSPITAL NAME

Grove Small Animal
Hospital

REFERRING VET

Dr. Celene Hendricks

INVOICE

73391

DATE

3/4/26

Pancreas

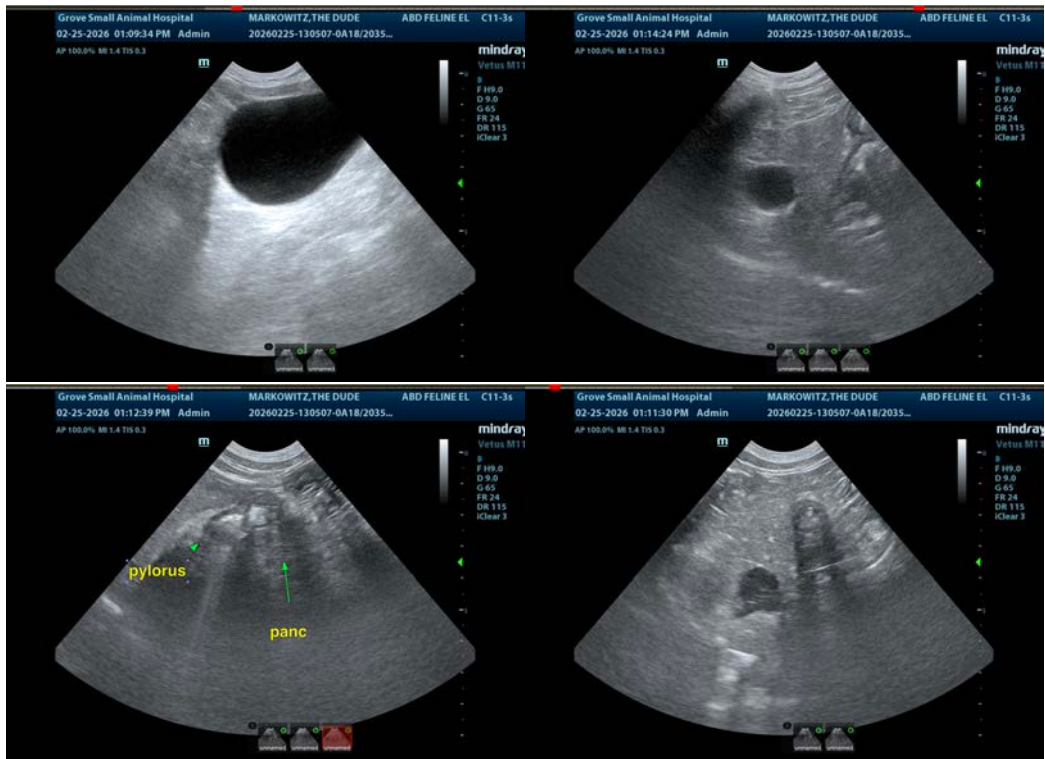
The base and limbs of the **pancreas** were observed to be largely isoechoic to surrounding omental fat. Some parenchymal remodeling, however, with mild deviation from curvilinear normalcy was observed. Pancreatic duct and capsular irregularities were present consistent with age related changes. If pain upon imaging (+ Murphy sign) was present or if the patient is focally painful in subxyphoid palpation then low-grade smoldering chronic pancreatitis should be suspected.

ULTRASONOGRAPHIC FINDINGS

- Mild to moderate degenerative renal changes.
- Age related hepatic and pancreatic changes.

INTERPRETATION OF THE FINDINGS & FURTHER RECOMMENDATIONS

Non-specific geriatric changes largely expected for this age patient. The cause of weight loss does not have a direct visceral link. Maldigestion panel, three view chest radiographs and full CNS examination is recommended to examine for occult disease that could be responsible for the weight loss. Evaluation for competitive eating environments should also be considered.





PATIENT

The Dude Markowitz

SPECIES

Feline

BREED

DSH

SEX

Neutered Male

AGE

15 Years

WEIGHT

10.65 lbs

INTERPRETED BY

Eric Lindquist, DMV,
DABVP (CFM), Cert.
IVUSS

IMAGING PERFORMED BY

Dr. Celene Hendricks

HOSPITAL NAME

Grove Small Animal
Hospital

REFERRING VET

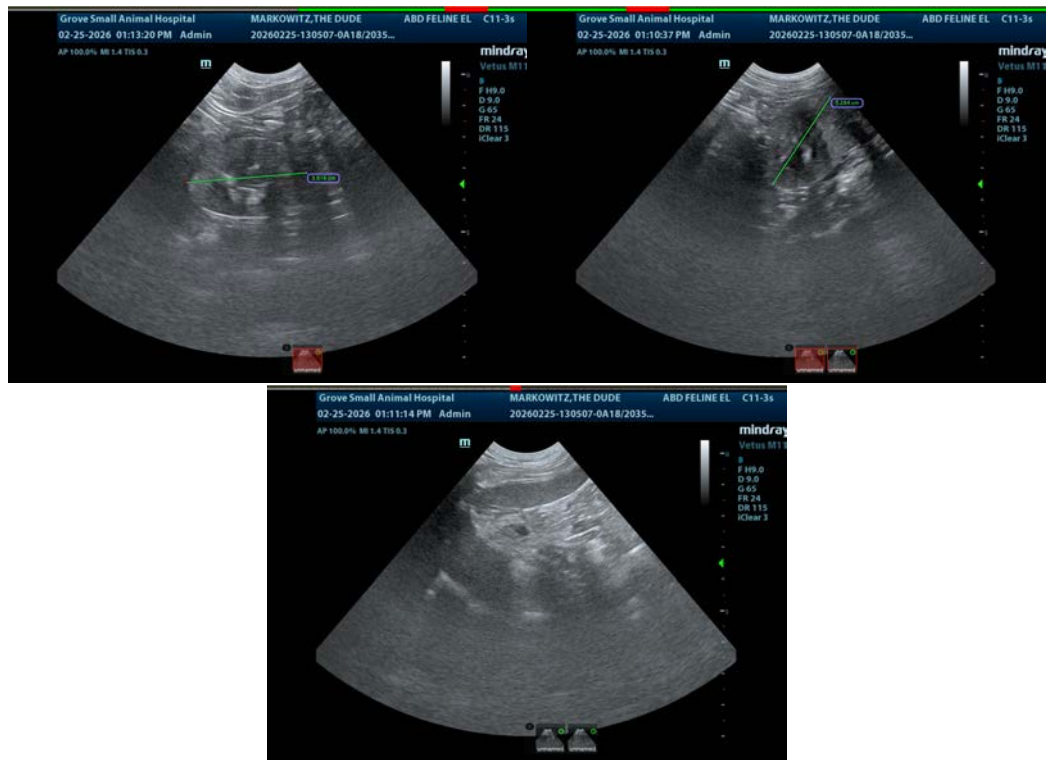
Dr. Celene Hendricks

INVOICE

73391

DATE

3/4/26



The information and recommendations provided are based on the images presented by the referring veterinarian/sonographer. No evaluation can be communicated regarding pathology that was not visible in the image/video clips provided.

Thank you for this referral. If the clinical or image interpretation does not parallel your findings or if I can be of any further assistance please contact me.

Eric Lindquist, DMV, DABVP(CFM), Cert. IVUSS,
CEO, Owner, Founder -- SonoPath.com
info@SonoPath.com