



## PATIENT

Mariposa Fryer

## SPECIES

Canine

## BREED

Beauceron

## SEX

Spayed Female

## AGE

10 Years

## WEIGHT

72.8 lbs

## INTERPRETED BY

Eric Lindquist, DMV,  
DABVP (CFM), Cert.  
IVUSS

## IMAGING PERFORMED BY

Dr. Laura Klaassen

## HOSPITAL NAME

Animal Care Group of  
Lake Oswego

## REFERRING VET

Dr. Laura Klaassen

## INVOICE

73392

## DATE

3/4/26

## PRESENTING CLINICAL SIGNS

Screening due to age.

Abnormal PE/Chem/CBC/UA Results: Labs unremarkable

## ULTRASONOGRAPHIC EXAMINATION OF THE HEART & ABDOMEN

CANINE CARDIAC PARAMETERS	MR VMAX (m/s)	TR VMAX (m/s)	LA/AO (M-Mode)	LA/AO (Heart Base; Swe)	FS (%)	EF (%)	EPSS (cm)
NORMAL PARAMETER	4.5-5.5	<2.7	1.3	Up to 1.6	28-40	40-100	<0.6
PATIENT	--	--	1.1	1.5	25	--	0.1
CANINE CARDIAC PARAMETERS	HR (BPM)	AV VMAX (m/s)	PV MAX (m/s)	BODY WEIGHT (lbs)	LAD LA MAX 4 Chamber	LVIDd Avg; 2D and m-mode short axis (cm)	LVIDs Avg; 2D and m-mode short axis (cm)
NORMAL PARAMETER	50-100	0.7-1.7	0.7-1.6				
PATIENT	--	--	--	72.8	--	3.8	--

### Cardiac Presentation

The echocardiogram in this patient demonstrated normal **left atrial** size based on 3 separate methods of LA evaluation. The cranial and caudal **mitral** valve leaflets presented normal linear structure, extension in systole, and union in diastole with normal kinesis. The **left ventricle** presented normal volumes, yet contractility was slightly subnormal. This may be a normal variant; however, hypothyroidism and Addison's should be considered. The **myocardium** presented normal echogenicity without subjective evidence of significant fibrotic or ischemic disease. The **left ventricular outflow** tract demonstrated normal laminar flow and subjective structural integrity. The **right atrium** and auricle revealed normal size, structure and content. No evidence of masses was noted. **Tricuspid** valvular assessment demonstrated adequate linear morphology and kinesis. The **right ventricle** was of normal size (1/3 diameter of LV), chordae structure, myocardial echogenicity and thickness. **Pulmonary outflow** tract assessment revealed normal valve structure, laminar flow, and diameter (approx. 1:1 pa/ao ratio). No visible **pericardial** or free pleura fluid was noted. The cranial **mediastinum** and **pericardial and extra-cardiac regions** were free of masses in the visible window.

### Urinary System

The **urinary bladder**, trigone, and pelvic urethra presented normal thicknesses and normal tone. The ureters were not visible which is normal. No uroliths or sediment were visualized and anechoic urine was present. No evidence of inflammatory or neoplastic changes were noted. Ureteral papillae were normal.



## PATIENT

Mariposa Fryer

## SPECIES

Canine

## BREED

Beauceron

## SEX

Spayed Female

## AGE

10 Years

## WEIGHT

72.8 lbs

## INTERPRETED BY

Eric Lindquist, DMV,  
DABVP (CFM), Cert.  
IVUS

## IMAGING PERFORMED BY

Dr. Laura Klaassen

## HOSPITAL NAME

Animal Care Group of  
Lake Oswego

## REFERRING VET

Dr. Laura Klaassen

## INVOICE

73392

## DATE

3/4/26

The **kidneys** revealed normal size and structure, corticomedullary definition and ratio for this age. The cortices presented largely uniform texture with normal echogenic relationship to liver and spleen. Medullary structure differed distinctly from the cortex and no evidence of pelvic dilation was present. The capsules were acceptably uniform without significant irregularities. Left kidney measured 7.3 cm. Right kidney measured 6.9 cm.

### **Adrenal Glands**

The **left adrenal gland** was visualized and recognized as having normal shape, size, position and echogenicity for this breed. The phrenic vasculature, glandular echogenicity and detail were unremarkable. Capsule, cortex, and medullary definition were normal for this age patient. Left adrenal gland measured 0.75 cm.

The region of the **right adrenal gland** was imaged, no evident pathology.

### **Spleen**

The **spleen** was folded upon itself cranially and caudally. It presented a smooth homogeneous parenchyma hyperechoic to liver and renal cortical parenchyma. The capsule was smooth without noticeable expansion or deviation from within the spleen or adjacent pathology. The splenic vasculature demonstrated normal volume without signs of congestion or thrombosis. No sonographic evidence of acute or chronic inflammatory, neoplastic, or infarctual changes were noted.

### **Liver**

The **liver** images from right and left intercostal as well as subcostal views revealed subjectively normal liver size, contour, and structure. Some age-related parenchymal remodeling was noted but likely not clinically significant at this time. Vascular and biliary tracts were of normal volume and no evidence of congestion was noted. The gallbladder presented some dependent debris with essentially normal contour. The cystic and common bile ducts were normal. No overt evidence of active inflammatory, infiltrative or regenerative pathology was noted but should be paired with current or past LE elevations regarding any clinical significance to this presentation. The hepatic lymph nodes were unremarkable.

### **Gastrointestinal**

Examination of the **gastrointestinal tract** revealed a stomach and intestine free of stasis, of normal wall thickness, acceptable curvilinear mural detail, and peristaltic activity. Small and large intestine demonstrated normal luminal chyme and stool consistency respectively. No obstructive or overt infiltrative disease was noted. No associated abnormal lymphatic activity was noted.

### **Pancreas**

The base and limbs of the **pancreas** were observed to be largely isoechoic to surrounding omental fat. Pancreatic duct and capsular contour were acceptably normal and parenchyma respected normal curvilinear patterns. No overt evidence of active inflammatory or neoplastic disease was noted.

## ULTRASONOGRAPHIC FINDINGS

- Normal cardiac structure, likely normal function with subnormal contractility.
- Age related hepatic remodeling.
- Folded spleen.



## PATIENT

Mariposa Fryer

## SPECIES

Canine

## BREED

Beauceron

## SEX

Spayed Female

## AGE

10 Years

## WEIGHT

72.8 lbs

## INTERPRETED BY

Eric Lindquist, DMV,  
DABVP (CFM), Cert.  
IVUS

## IMAGING PERFORMED BY

Dr. Laura Klaassen

## HOSPITAL NAME

Animal Care Group of  
Lake Oswego

## REFERRING VET

Dr. Laura Klaassen

## INVOICE

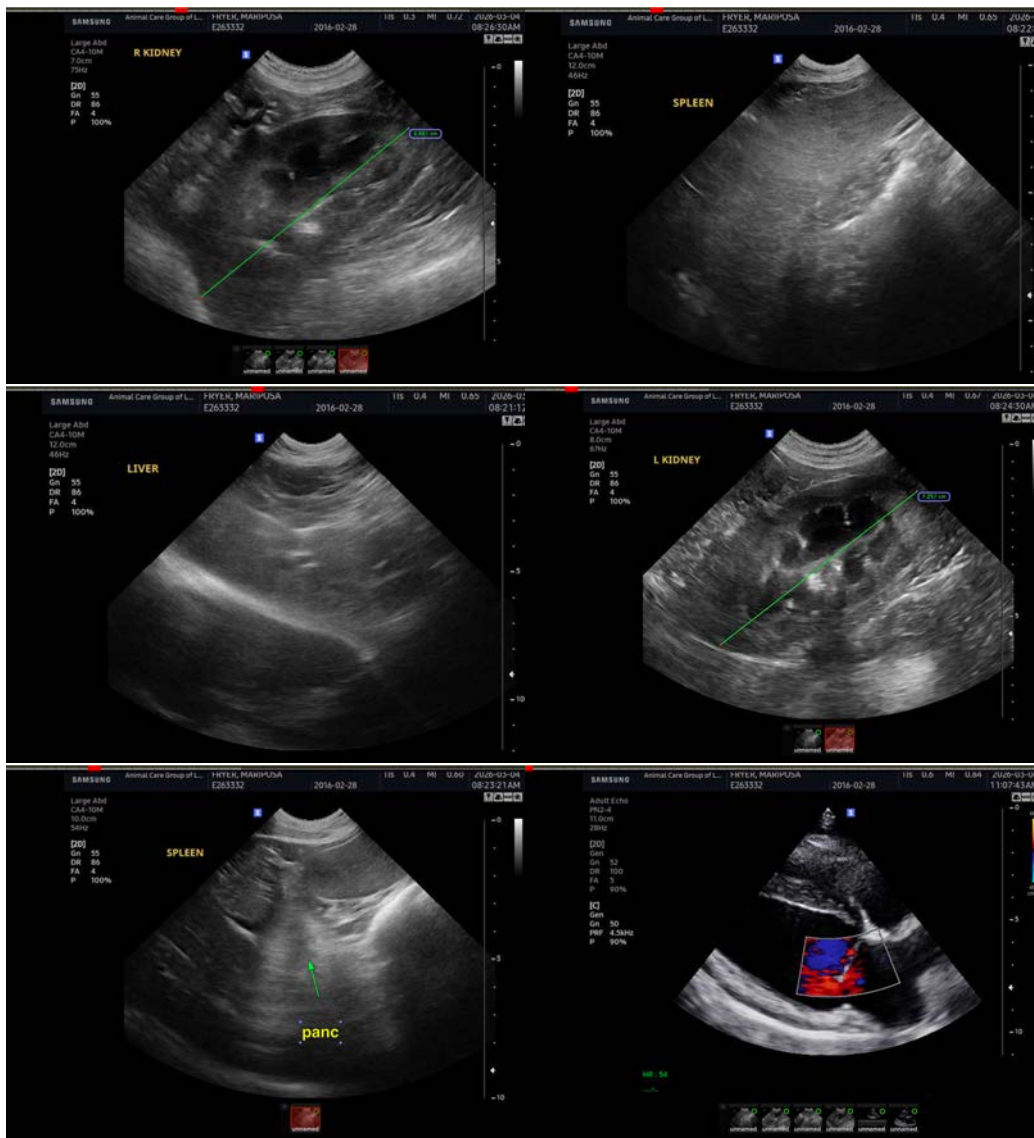
73392

## DATE

3/4/26

## INTERPRETATION OF THE FINDINGS & FURTHER RECOMMENDATIONS

Athletic patients can have subnormal contractility. However, other causes of subnormal contractility such as hypothyroidism and Addison's should be considered, though not overtly suspected.





**PATIENT**

Mariposa Fryer

**SPECIES**

Canine

**BREED**

Beauceron

**SEX**

Spayed Female

**AGE**

10 Years

**WEIGHT**

72.8 lbs

**INTERPRETED BY**

Eric Lindquist, DMV,  
DABVP (CFM), Cert.  
IVUSS

**IMAGING  
PERFORMED BY**

Dr. Laura Klaassen

**HOSPITAL NAME**

Animal Care Group of  
Lake Oswego

**REFERRING VET**

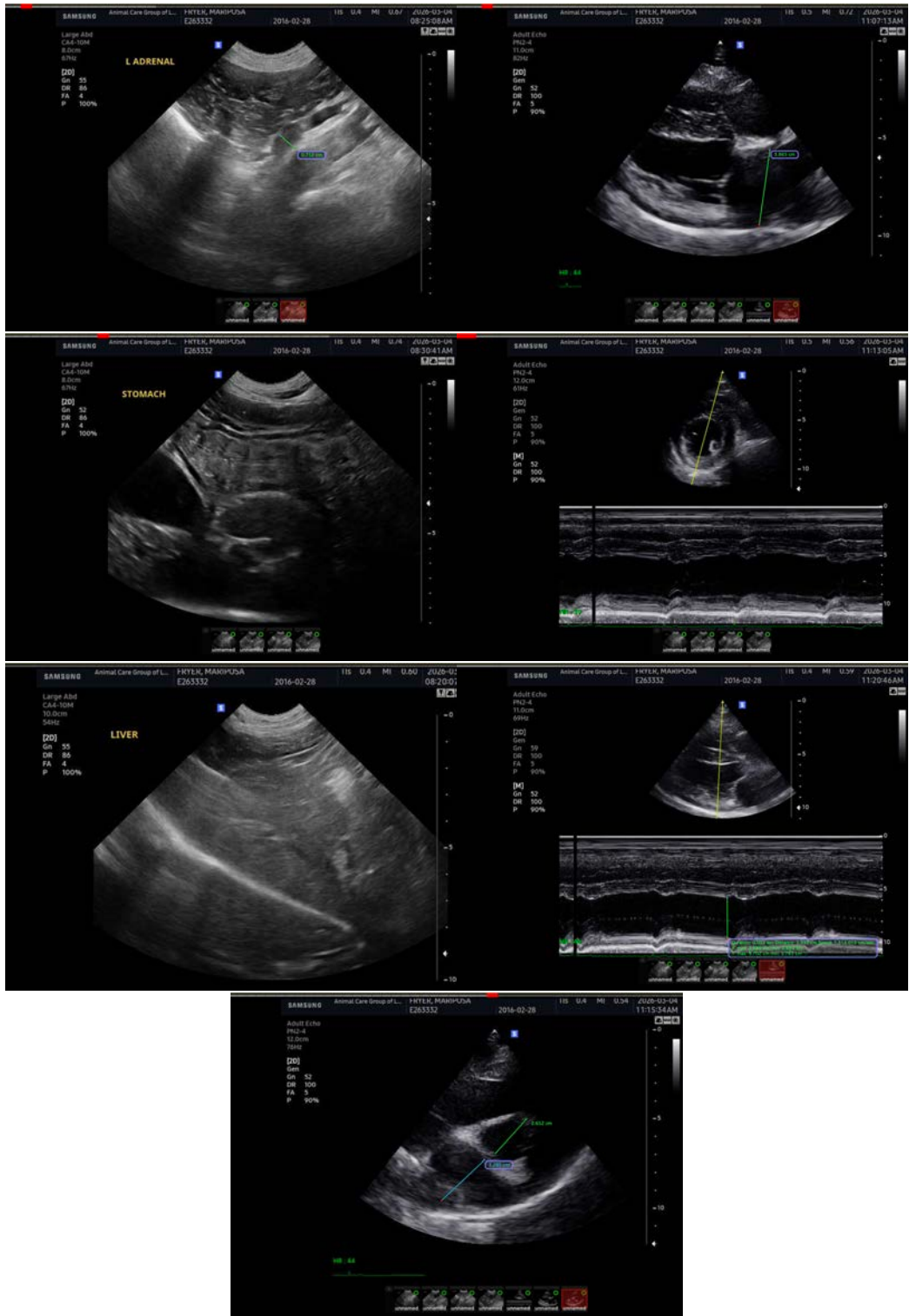
Dr. Laura Klaassen

**INVOICE**

73392

**DATE**

3/4/26





## PATIENT

Mariposa Fryer

## SPECIES

Canine

## BREED

Beauceron

## SEX

Spayed Female

## AGE

10 Years

## WEIGHT

72.8 lbs

## INTERPRETED BY

Eric Lindquist, DMV,  
DABVP (CFM), Cert.  
IVUSS

## IMAGING PERFORMED BY

Dr. Laura Klaassen

## HOSPITAL NAME

Animal Care Group of  
Lake Oswego

## REFERRING VET

Dr. Laura Klaassen

## INVOICE

73392

## DATE

3/4/26

The information and recommendations provided are based on the images presented by the referring veterinarian/sonographer. No evaluation can be communicated regarding pathology that was not visible in the image/video clips provided.

Thank you for this referral. If the clinical or image interpretation does not parallel your findings or if I can be of any further assistance please contact me.

**Eric Lindquist**, DMV, DABVP(CFM), Cert. IVUSS,  
CEO, Owner, Founder -- SonoPath.com  
[info@SonoPath.com](mailto:info@SonoPath.com)