



<b>PATIENT</b>	<b>PRESENTING CLINICAL SIGNS</b>
Merengue Underdog	Rescue pet came in for exam 2 weeks ago. Skin and ear infections but OK wt. eating and drinking OK. Most likely intact female. Large, very firm mass palpated mid ventral abdomen, second smaller mass above it.
<b>SPECIES</b>	Abnormal PE/Chem/CBC/UA Results: Chemistry Profile-WTL
Canine	<b>ULTRASONOGRAPHIC EXAMINATION OF THE ABDOMEN</b>
<b>BREED</b>	<b>Urinary System</b>
Poodle X	The <b>urinary bladder</b> , trigone, and pelvic urethra presented normal thicknesses and normal tone. The ureters were not visible which is normal. No uroliths or sediment were visualized and anechoic urine was present. No evidence of inflammatory or neoplastic changes were noted. Ureteral papillae were normal.
<b>SEX</b>	The <b>kidneys</b> revealed normal size and structure, corticomedullary definition and ratio for this age. The cortices presented largely uniform texture with normal echogenic relationship to liver and spleen. Medullary structure differed distinctly from the cortex and no evidence of pelvic dilation was present. The capsules were acceptably uniform without significant irregularities. The left kidney measured 4.0 cm.
Female	
<b>AGE</b>	
10 Years	<b>Adrenal Glands</b>
	The <b>left adrenal gland</b> was mildly enlarged and slightly irregular, measuring 7.0 mm at maximum width. The <b>right adrenal gland</b> measured 0.80 cm at the cranial pole and 0.60 cm at the caudal pole.
<b>WEIGHT</b>	<b>Spleen</b>
21.4	The <b>spleen</b> was folded upon itself cranially, unremarkable otherwise.
<b>INTERPRETED BY</b>	<b>Liver</b>
Eric Lindquist, DMV	The <b>liver</b> revealed slight increased portal markings with normal size and contour. The gallbladder was unremarkable.
DABVP, Cert. IVUSS	<b>Gastrointestinal</b>
<b>IMAGING PERFORMED BY</b>	Examination of the <b>gastrointestinal tract</b> revealed a stomach and intestine free of stasis, of normal wall thickness, acceptable curvilinear mural detail, and peristaltic activity. Small and large intestine demonstrated normal luminal chyme and stool consistency respectively. No obstructive or overt infiltrative disease was noted. No associated abnormal lymphatic activity was noted.
Dr. Laurel Logas	<b>Pancreas</b>
<b>HOSPITAL NAME</b>	The base and limbs of the <b>pancreas</b> were observed to be largely isoechoic to surrounding omental fat. Pancreatic duct and capsular contour were acceptably normal and parenchyma respected normal curvilinear patterns. No overt evidence of active inflammatory or neoplastic disease was noted.
Bradenton VH	<b>Other</b>
<b>REFERRING VET</b>	At least one, if not two decomposing fetuses appear to be present in the caudal abdomen. No heart beats noted, and tissues appeared to be significantly irregular with loss of structural detail, which would suggest fetal death. The larger structure appears to be at least 6-8 cm in length.
Dr. Laurel Logas	
<b>INVOICE</b>	
35955	
<b>DATE</b>	
3/4/22	



**PATIENT**

Merengue Underdog

**ULTRASONOGRAPHIC FINDINGS**

- At least one partially mummified fetus

**SPECIES**

Canine

**INTERPRETATION OF THE FINDINGS & FURTHER RECOMMENDATIONS**

Recommend ovariohysterectomy in this patient.

**BREED**

Poodle X

**SEX**

Female

**AGE**

10 Years

**WEIGHT**

21.4

**INTERPRETED BY**

Eric Lindquist, DMV

DABVP, Cert. IVUSS

**IMAGING PERFORMED BY**

Dr. Laurel Logas

**HOSPITAL NAME**

Bradenton VH

**REFERRING VET**

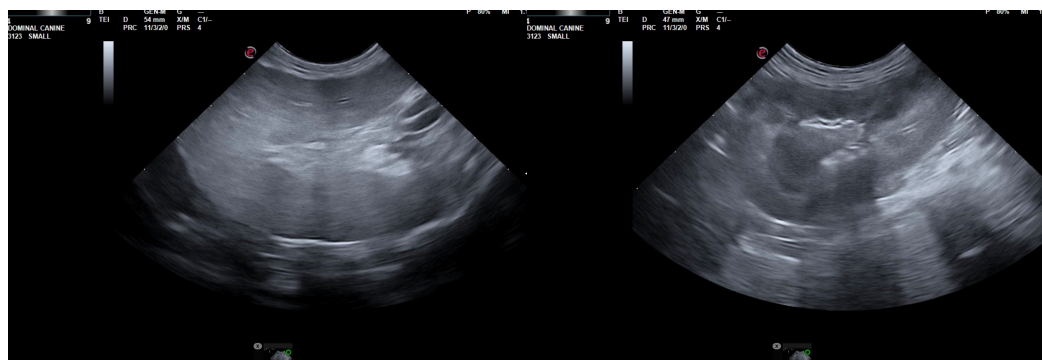
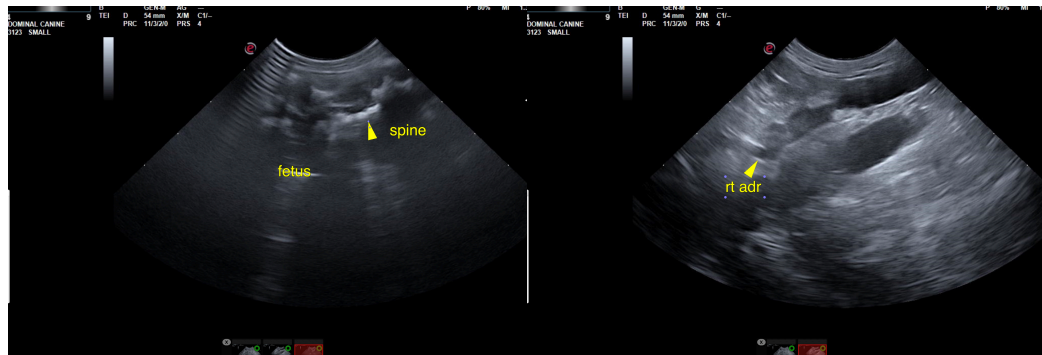
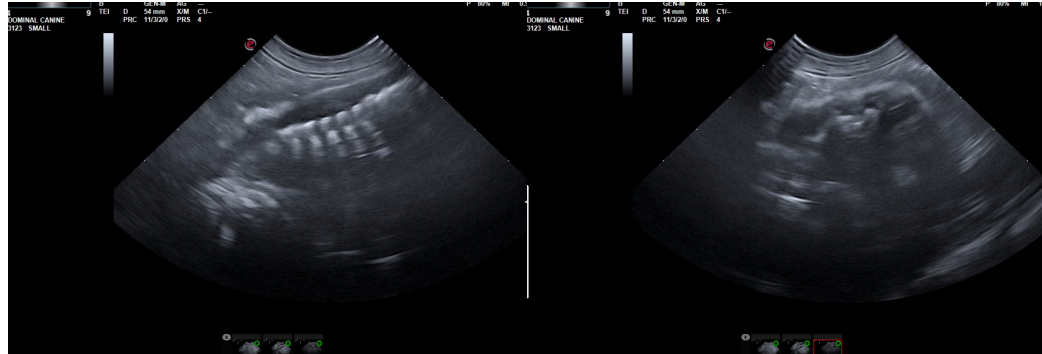
Dr. Laurel Logas

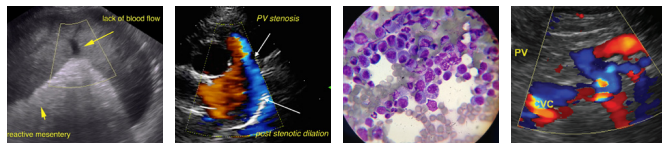
**INVOICE**

35955

**DATE**

3/4/22





**PATIENT**

Merengue Underdog

**SPECIES**

Canine

**BREED**

Poodle X

**SEX**

Female

**AGE**

10 Years

**WEIGHT**

21.4

**INTERPRETED BY**

Eric Lindquist, DMV

DABVP, Cert. IVUSS

**IMAGING PERFORMED BY**

Dr. Laurel Logas

**HOSPITAL NAME**

Bradenton VH

**REFERRING VET**

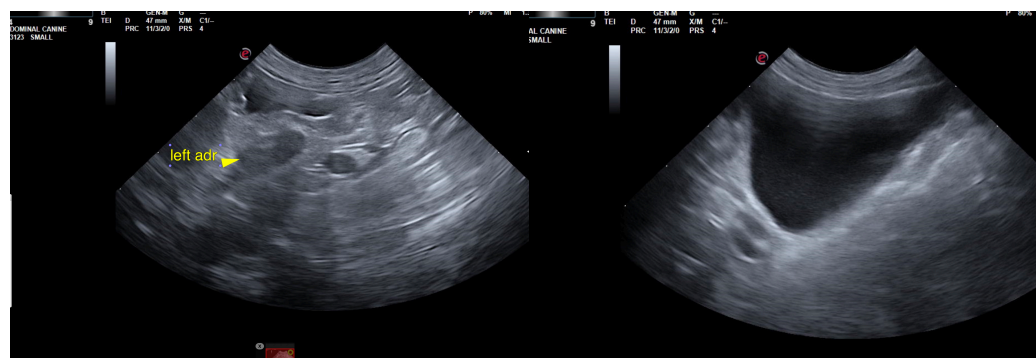
Dr. Laurel Logas

**INVOICE**

35955

**DATE**

3/4/22



The information and recommendations provided are based on the images presented by the referring veterinarian/sonographer. No evaluation can be communicated regarding pathology that was not visible in the image/video clips provided.

Thank you for this referral. If the clinical or image interpretation does not parallel your findings or if I can be of any further assistance please contact me.

**Eric Lindquist, DMV, DABVP, Cert. IVUSS, CEO of SonoPath.com**

[info@SonoPath.com](mailto:info@SonoPath.com)