



## PATIENT

Paco Johnson

## SPECIES

Feline

## BREED

Domestic Shorthair

## SEX

Neutered male

## AGE

10 years

## WEIGHT

14.6 lbs

## INTERPRETED BY

Eric Lindquist, DMV  
DABVP, Cert. IVUSS

## IMAGING PERFORMED BY

Dr. Hougentogler

## HOSPITAL NAME

K Vet AC

## REFERRING VET

Dr. Hougentogler

## INVOICE

73972

## DATE

3/31/26

## PRESENTING CLINICAL SIGNS

- No symptoms; patient has elevated BNP on routine bloodwork
- BAR; BCS 6/9; no abnormalities on exam
- Appetite: Good
- Was given 200mg of gabapentin 1 hour prior to echo
- Temperature: \_100.9\_ Pulse: \_200\_ RR: \_60\_ mm: \_pink\_ Pulse Quality: \_regular\_
- Diagnostics: Systolic BP: 105 (Used Doppler after Gabapentin) Total T4: 1.7 ProBNP: 280 Creatinine: 1.6

## ULTRASONOGRAPHIC EXAMINATION OF THE HEART

The echocardiogram in this patient demonstrated normal **left atrial** size based on 3 separate LA measurements. The cranial and caudal **mitral** valve leaflets presented normal linear structure and kinetics. The **left ventricle** presented normal thicknesses with linear contour and was not dilated nor restricted. The **myocardium** presented normal echogenicity without subjective evidence of significant fibrotic or ischemic disease. **Contractility** of the ventricular walls was adequate and in normal range for this patient evidenced by the fractional shortening measurement and subjective evaluation of the different regions and angles of the myocardium. The **left ventricular outflow** tract demonstrated normal laminar flow and subjective structural integrity. The **right atrium** and auricle revealed normal size, structure and content. No evidence of masses was noted or chamber overload. **Tricuspid** valvular assessment demonstrated adequate linear morphology and kinetics. The **right ventricle** was of normal size (1/3 diameter of LV), chordae structure, myocardial echogenicity and thickness. **Pulmonic** tract assessment revealed normal valve structure, laminar flow, and diameter (approx.1:1 pa/ao ratio). No visible **pericardial** or free pleura fluid was noted or extra cardiac pathology in the visible planes. The cranial **mediastinum and pericardial regions** were free of masses in the visible window.

FELINE CARDIAC PARAMETERS	BODY WEIGHT	HR (BPM)	IVSd (cm)	LVIDd (cm)	LVWd (cm)	FS (%)	EF (%)
NORMAL PARAMETER	-----	150-240	0.3-0.6	1.0-2.1	0.25-0.6	35-67	80-100
PATIENT	14.6 lbs	NM	0.5	1.2	0.5	45	80
FELINE CARDIAC PARAMETERS	LA/AO (M-mode)	LA/AO HEART BASE (Sisson)	LAD LA MAX 4 Chamber		LVOT VEL. (m/s)	RVOT VEL. (m/s)	IVRT (m)
NORMAL PARAMETER	<1.5	1.6	0.7-1.7		<1.6	<1.3	40-60
PATIENT	1.1	1.1	NM		1.2	0.8	NM
Adapted from June Boon, Veterinary Echocardiography, 1998 Sisson D et al. JVIM 1991; 5: 232, Jacobs et al. Am J Vet Res 1985; 46:1705							

## ULTRASONOGRAPHIC FINDINGS



**PATIENT**

Normal echocardiogram.

Paco Johnson

**SPECIES**

**INTERPRETATION OF THE FINDINGS & FURTHER RECOMMENDATIONS**

Feline

There was no evidence of pathology.

**BREED**

Domestic Shorthair

**SEX**

Neutered male

**AGE**

10 years

**WEIGHT**

14.6 lbs

**INTERPRETED BY**

Eric Lindquist, DMV  
DABVP, Cert. IVUSS

**IMAGING PERFORMED BY**

Dr. Hougentogler

**HOSPITAL NAME**

K Vet AC

**REFERRING VET**

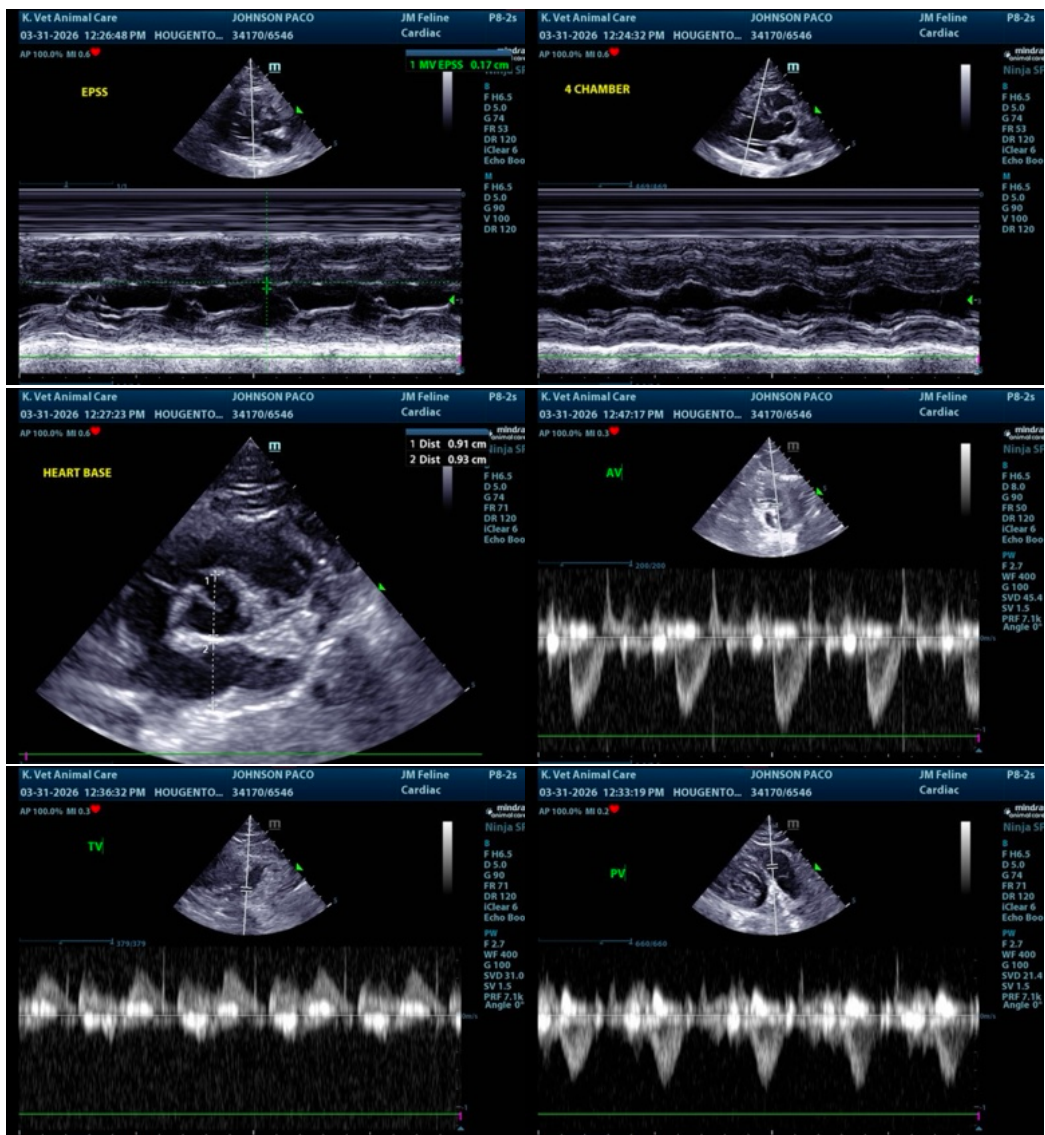
Dr. Hougentogler

**INVOICE**

73972

**DATE**

3/31/26





## PATIENT

Paco Johnson

## SPECIES

Feline

## BREED

Domestic Shorthair

## SEX

Neutered male

## AGE

10 years

## WEIGHT

14.6 lbs

## INTERPRETED BY

Eric Lindquist, DMV  
DABVP, Cert. IVUSS

## IMAGING PERFORMED BY

Dr. Hougentogler

## HOSPITAL NAME

K Vet AC

## REFERRING VET

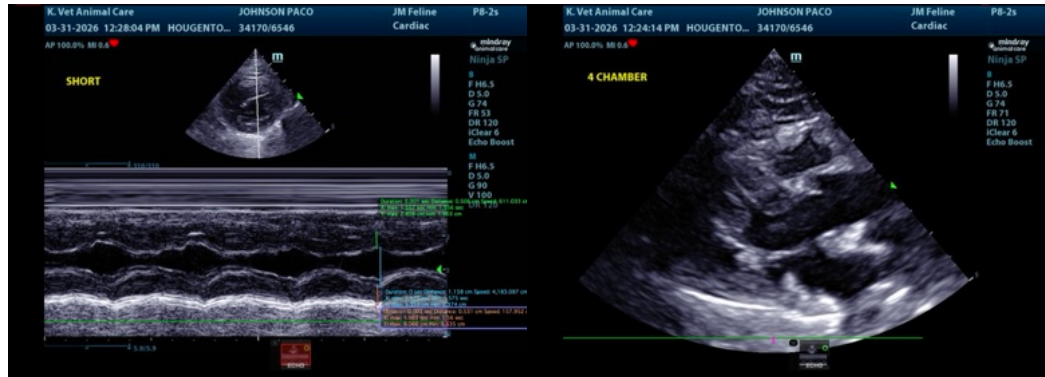
Dr. Hougentogler

## INVOICE

73972

## DATE

3/31/26



The information and recommendations provided are based on the images presented by the referring veterinarian/sonographer. No evaluation can be communicated regarding pathology that was not visible in the image/video clips provided.

Thank you for this referral. If the clinical or image interpretation does not parallel your findings or if I can be of any further assistance please contact me.

Eric Lindquist, DMV, DABVP (CFM), Cert. IVUSS, CEO of SonoPath.com

[info@SonoPath.com](mailto:info@SonoPath.com)