



## PATIENT

Oliver Trudeau

## SPECIES

Canine

## BREED

Shih Tzu

## SEX

Neutered male

## AGE

13 years

## WEIGHT

11.5 lbs

## INTERPRETED BY

Eric Lindquist, DMV  
DABVP, Cert. IVUSS

## IMAGING PERFORMED BY

Dr. Trudeau

## HOSPITAL NAME

Vetcetera AH

## REFERRING VET

Dr. Trudeau

## INVOICE

73966

## DATE

3/31/26

## PRESENTING CLINICAL SIGNS

- Doctors pet. Follow u/s for a left adrenal gland tumor. PU/PD did not last - currently not PU/PD. Serial BP were done initially with hypertension evident over a 3 day period done at home - ex: 208/76 MAP 131; 203/106 MAP 153
- So until tests returned I started basic ACE-I even though not the drug of choice 5mg BID and his BP are still slightly increased but improved to : 167/88 MAP 116; 180/126 MAP 141, 122/97 MAP 108. Opted to hold off on any other medications at this time until a definitive Dx
- Metanephrine / Creatinine (Urine) 282 ( 18 - 359 ug/g) Normetanephrine / Creatinine (Urine) 226 (28 - 380 ug/g) BP - as above USG - remained above 1.020 LDDS: pre: 93 (28-166) 4 hrs 37 (28-166) 8 hrs 28 (28-166)

## ULTRASONOGRAPHIC EXAMINATION OF THE ABDOMEN

### Adrenal Glands

Further images of the left adrenal gland were submitted. There was evident phrenic vein invasion with mid gland nodular changes. The contour was swollen and irregular.

## ULTRASONOGRAPHIC FINDINGS

Left adrenal mass with phrenic vein invasion.

## INTERPRETATION OF THE FINDINGS & FURTHER RECOMMENDATIONS

Left adrenalectomy is strongly recommended. Carcinoma is likely given the metanephrine levels. Paraneoplastic hypertension is suspected with potential Cushing's.

Internal medicine consult can be utilized through SonoPath.com. You can select the internal medicine drop down at <http://spa.sonopath.com/>.

One of the world's top internists & SonoPath associate Dr. Remo Lobetti BVSc, MMedVet, PhD, DECVIM can evaluate your case through SonoPath. <https://sonopath.com/resources/sonopath-services/internal-medicine-teleconsultation-services>



## PATIENT

Oliver Trudeau

## SPECIES

Canine

## BREED

Shih Tzu

## SEX

Neutered male

## AGE

13 years

## WEIGHT

11.5 lbs

## INTERPRETED BY

Eric Lindquist, DMV  
DABVP, Cert. IVUSS

## IMAGING PERFORMED BY

Dr. Trudeau

## HOSPITAL NAME

Vetcetera AH

## REFERRING VET

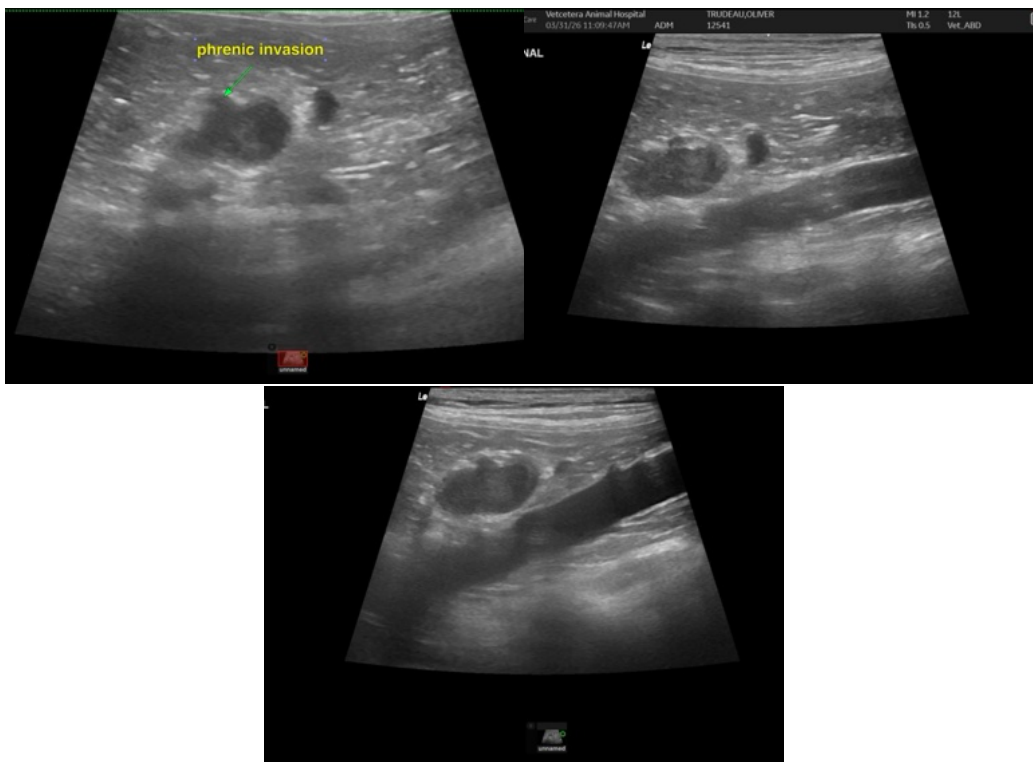
Dr. Trudeau

## INVOICE

73966

## DATE

3/31/26



The information and recommendations provided are based on the images presented by the referring veterinarian/sonographer. No evaluation can be communicated regarding pathology that was not visible in the image/video clips provided.

Thank you for this referral. If the clinical or image interpretation does not parallel your findings or if I can be of any further assistance please contact me.

Eric Lindquist, DMV, DABVP (CFM), Cert. IVUSS, CEO of SonoPath.com

[info@SonoPath.com](mailto:info@SonoPath.com)