



## PATIENT

Lucy Bertram

## SPECIES

Canine

## BREED

Golden Retriever

## SEX

Spayed female

## AGE

10 years

## WEIGHT

83 lbs

## INTERPRETED BY

Eric Lindquist, DMV  
DABVP, Cert. IVUSS

## IMAGING PERFORMED BY

Dr. Fisher

## HOSPITAL NAME

Cape Coral Pet Vet

## REFERRING VET

Dr. Fisher

## INVOICE

73971

## DATE

3/31/26

## PRESENTING CLINICAL SIGNS

- Wellness AUS

## ULTRASONOGRAPHIC EXAMINATION OF THE ABDOMEN

### Urinary System

The **urinary bladder**, trigone, and pelvic urethra presented normal thicknesses and normal tone. The ureters were not visible which is normal. No uroliths or sediment were visualized and anechoic urine was present. No evidence of inflammatory or neoplastic changes was noted. Ureteral papillae were normal.

The **kidneys** revealed normal size and structure, corticomedullary definition and ratio for this age. The cortices presented largely uniform texture with normal echogenic relationship to liver and spleen. Medullary structure differed distinctly from the cortex and no evidence of pelvic dilation was present. The capsules were acceptably uniform without significant irregularities. The left kidney measured 6.6 cm. The right kidney measured 4.8 cm.

### Adrenal Glands

Both **adrenal glands** were visualized and recognized as having normal shape, size, position and echogenicity for this breed. The phrenic vasculature, glandular echogenicity and detail were unremarkable. Capsule, cortex, and medullary definition were normal for this age patient. The left adrenal gland measured 0.6 cm. The right adrenal gland measured 0.65 cm.

### Spleen

The **spleen** presented a smooth homogeneous parenchyma hyperechoic to liver and renal cortical parenchyma. The capsule was smooth without noticeable expansion or deviation from within the spleen or adjacent pathology. The splenic vasculature demonstrated normal volume without signs of congestion or thrombosis. No sonographic evidence of acute or chronic inflammatory, neoplastic, or infarctual changes was noted.

### Liver

Exam of the cranial abdomen demonstrated excessive **liver** size, swollen contour, with conserved uniform architecture. Multi-focal nodular changes were noted. The parenchyma was hyperechoic compared to falciform fat echogenicity was diffusely isoechoic to the spleen and falciform fat. The gallbladder and common bile duct were unremarkable.



## PATIENT

Lucy Bertram

## SPECIES

Canine

## BREED

Golden Retriever

## SEX

Spayed female

## AGE

10 years

## WEIGHT

83 lbs

## INTERPRETED BY

Eric Lindquist, DMV  
DABVP, Cert. IVUSS

## IMAGING PERFORMED BY

Dr. Fisher

## HOSPITAL NAME

Cape Coral Pet Vet

## REFERRING VET

Dr. Fisher

## INVOICE

73971

## DATE

3/31/26

## Gastrointestinal

Examination of the **gastrointestinal tract** revealed a stomach and intestine free of stasis, of normal wall thickness, acceptable curvilinear mural detail, and peristaltic activity. Small and large intestine demonstrated normal luminal chyme and stool consistency respectively. No obstructive or overt infiltrative disease was noted. No associated abnormal lymphatic activity was noted.

## Pancreas

The base and limbs of the **pancreas** were observed to be largely isoechoic to surrounding omental fat. Pancreatic duct and capsular contour were acceptably normal and parenchyma respected normal curvilinear patterns. No overt evidence of active inflammatory or neoplastic disease was noted.

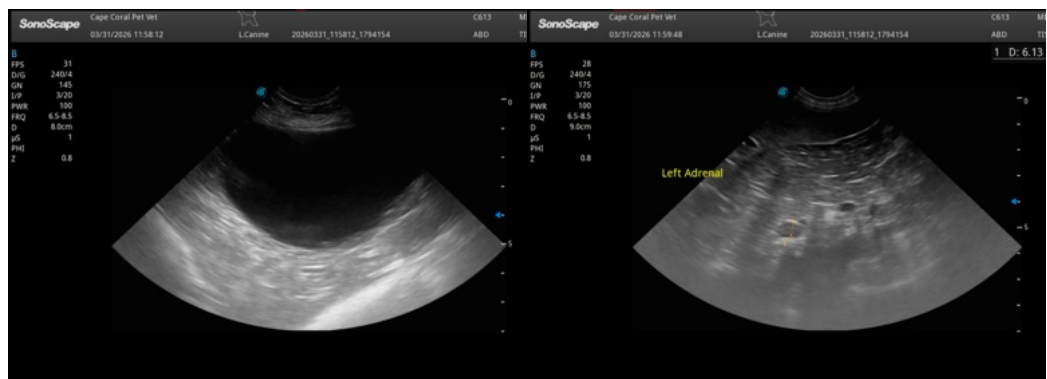
## ULTRASONOGRAPHIC FINDINGS

Vacuolar hepatopathy liver pattern with FNA for further definition.

Otherwise, unremarkable abdomen.

## INTERPRETATION OF THE FINDINGS & FURTHER RECOMMENDATIONS

FNA of the liver is recommended for further definition.





## PATIENT

Lucy Bertram

## SPECIES

Canine

## BREED

Golden Retriever

## SEX

Spayed female

## AGE

10 years

## WEIGHT

83 lbs

## INTERPRETED BY

Eric Lindquist, DMV  
DABVP, Cert. IVUSS

## IMAGING PERFORMED BY

Dr. Fisher

## HOSPITAL NAME

Cape Coral Pet Vet

## REFERRING VET

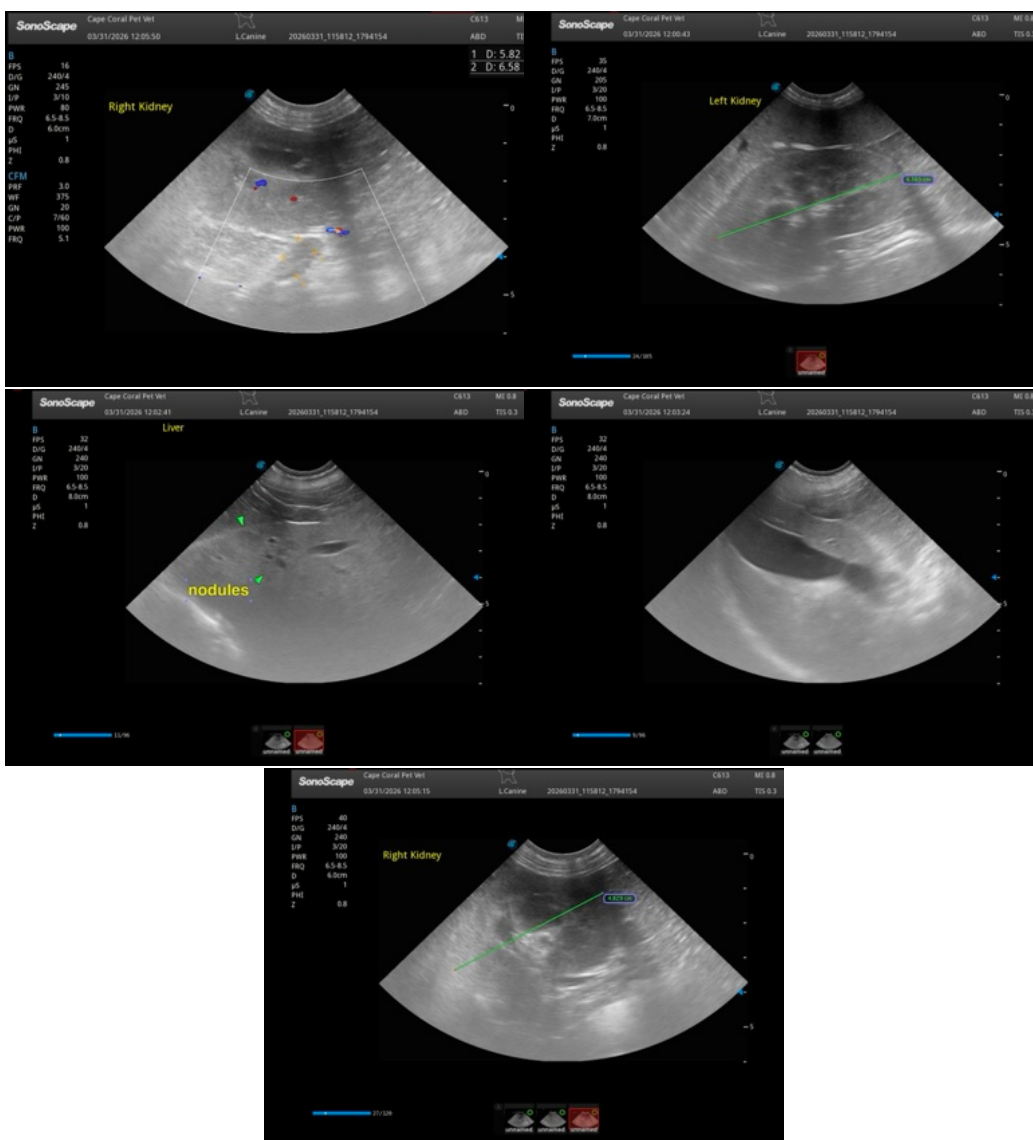
Dr. Fisher

## INVOICE

73971

## DATE

3/31/26



The information and recommendations provided are based on the images presented by the referring veterinarian/sonographer. No evaluation can be communicated regarding pathology that was not visible in the image/video clips provided.

Thank you for this referral. If the clinical or image interpretation does not parallel your findings or if I can be of any further assistance please contact me.

Eric Lindquist, DMV, DABVP (CFM), Cert. IVUSS, CEO of SonoPath.com

[info@SonoPath.com](mailto:info@SonoPath.com)