



PATIENT

Abbie Gutierrez

SPECIES

Canine

BREED

Boxer

SEX

Spayed female

AGE

4 years

WEIGHT

80 lbs

INTERPRETED BY

Eric Lindquist, DMV
DABVP, Cert. IVUSS

IMAGING PERFORMED BY

Jeremiah Gabriel

HOSPITAL NAME

Central Jersey AH

REFERRING VET

Dr. Gabriel

INVOICE

73944

DATE

3/31/26

PRESENTING CLINICAL SIGNS

- bloody diarrhea
- anorexia for 2 days

ULTRASONOGRAPHIC EXAMINATION OF THE ABDOMEN

Urinary System

The **urinary bladder**, trigone, and pelvic urethra presented normal thicknesses and normal tone. The ureters were not visible which is normal. No uroliths or sediment were visualized and anechoic urine was present. No evidence of inflammatory or neoplastic changes was noted. Ureteral papillae were normal.

The **kidneys** revealed normal size and structure, corticomedullary definition and ratio for this age. The cortices presented largely uniform texture with normal echogenic relationship to liver and spleen. Medullary structure differed distinctly from the cortex and no evidence of pelvic dilation was present. The capsules were acceptably uniform without significant irregularities. The left kidney measured 4.9 cm. The right kidney measured 5.0 cm.

Adrenal Glands

The right adrenal gland was not visualized. Further evaluation under sedation is indicated. The left adrenal gland was uniform and measured 0.7 cm.

Spleen

The **spleen** presented a smooth homogeneous parenchyma hyperechoic to liver and renal cortical parenchyma. The capsule was smooth without noticeable expansion or deviation from within the spleen or adjacent pathology. The splenic vasculature demonstrated normal volume without signs of congestion or thrombosis. No sonographic evidence of acute or chronic inflammatory, neoplastic, or infarctual changes was noted.

Liver

The **liver** images submitted revealed subjectively normal liver size, contour, and structure. Parenchymal echogenicity was naturally coarse and hypoechoic to the spleen. Vascular and biliary tracts were of normal volume with no evidence of congestion. The gallbladder presented acceptably thin walls with primarily anechoic content. The cystic and common bile ducts were normal. No pathological hepatic lymphadenopathy was evident. No overt structural evidence of inflammatory, infiltrative or regenerative pathology was evident.



PATIENT

Abbie Gutierrez

SPECIES

Canine

BREED

Boxer

SEX

Spayed female

AGE

4 years

WEIGHT

80 lbs

INTERPRETED BY

Eric Lindquist, DMV
DABVP, Cert. IVUSS

IMAGING PERFORMED BY

Jeremiah Gabriel

HOSPITAL NAME

Central Jersey AH

REFERRING VET

Dr. Gabriel

INVOICE

73944

DATE

3/31/26

Gastrointestinal

Examination of the **gastrointestinal tract** revealed a stomach and intestine free of stasis, of normal wall thickness, acceptable curvilinear mural detail, and peristaltic activity. Small and large intestine demonstrated normal luminal chyme and stool consistency respectively. No obstructive or overt infiltrative disease was noted. No associated abnormal lymphatic activity was noted.

Pancreas

The base and limbs of the **pancreas** were observed to be largely isoechoic to surrounding omental fat. Pancreatic duct and capsular contour were acceptably normal and parenchyma respected normal curvilinear patterns. No overt evidence of active inflammatory or neoplastic disease was noted.

Free Abdomen

The cranial abdomen revealed acoustic attenuation. An undefined structure was noted in the right cranial abdomen. Further sedation is indicated under sedation.

ULTRASONOGRAPHIC FINDINGS

Acoustic attenuation was an issue with portions of the cranial abdomen, particularly the right cranial abdomen.

Undefined structure in the right cranial abdomen.

There was no evidence of structural GI disease.

INTERPRETATION OF THE FINDINGS & FURTHER RECOMMENDATIONS

Differentials for diarrhea include occult parasitism. Dietary indiscretion, dietary intolerance, antibiotic responsive colitis, intestinal dysbiosis and occult Addison's should all be considered as causes of diarrhea in this patient. A hydrolyzed diet trial may be in this patient's best interest +/- probiotics. 24-hour NPO and reintroduction of bland diet indicated. I recommend a baseline cortisol or ACTH stimulation test, a fresh fecal smear and fecal floatation analysis if not already performed



PATIENT

Abbie Gutierrez

SPECIES

Canine

BREED

Boxer

SEX

Spayed female

AGE

4 years

WEIGHT

80 lbs

INTERPRETED BY

Eric Lindquist, DMV
DABVP, Cert. IVUSS

IMAGING PERFORMED BY

Jeremiah Gabriel

HOSPITAL NAME

Central Jersey AH

REFERRING VET

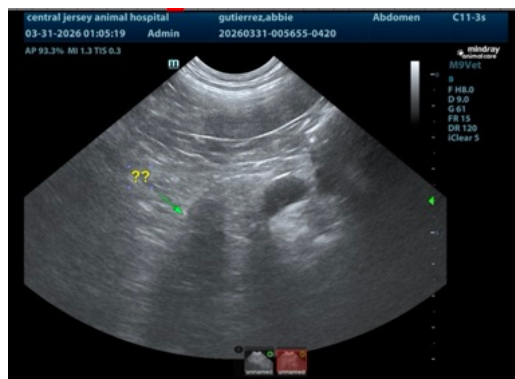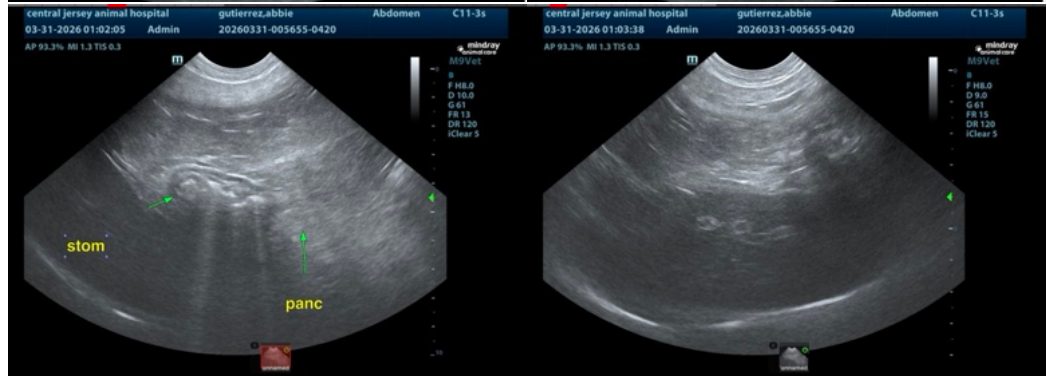
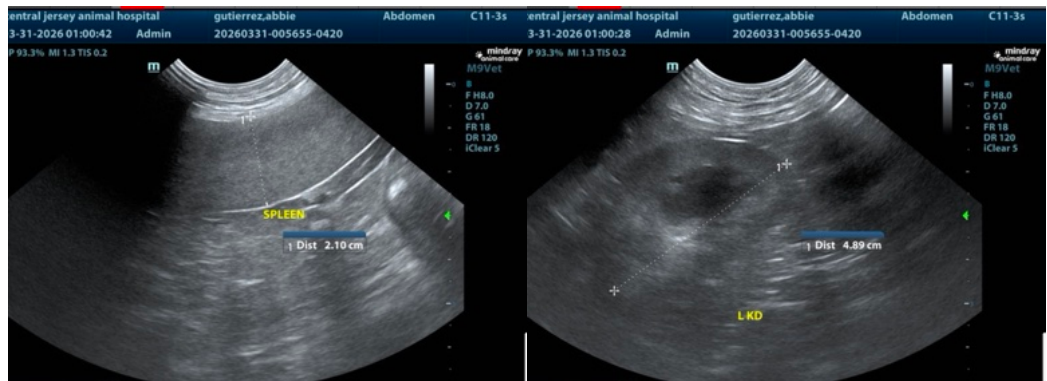
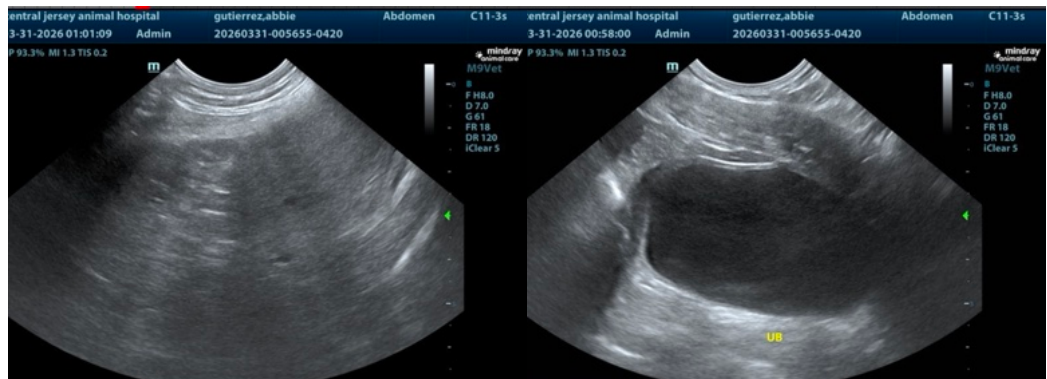
Dr. Gabriel

INVOICE

73944

DATE

3/31/26





PATIENT

Abbie Gutierrez

SPECIES

Canine

BREED

Boxer

SEX

Spayed female

AGE

4 years

WEIGHT

80 lbs

INTERPRETED BY

Eric Lindquist, DMV
DABVP, Cert. IVUSS

IMAGING PERFORMED BY

Jeremiah Gabriel

HOSPITAL NAME

Central Jersey AH

REFERRING VET

Dr. Gabriel

INVOICE

73944

DATE

3/31/26

The information and recommendations provided are based on the images presented by the referring veterinarian/sonographer. No evaluation can be communicated regarding pathology that was not visible in the image/video clips provided.

Thank you for this referral. If the clinical or image interpretation does not parallel your findings or if I can be of any further assistance please contact me.

Eric Lindquist, DMV, DABVP (CFM), Cert. IVUSS, CEO of SonoPath.com

info@SonoPath.com