

**DATE PRESENTING CLINICAL SIGNS**

3/31/23

History: Chronic intermittent vomiting for a year. Does not improve with diet change, omeprazole, or Cerenia. P eats twice daily and no consistency to when she vomits. Typically, late afternoon/evening. O has switched from fish to chicken with no improvement.

**PATIENT**

Ivy Shepard

Current Medications: Cerenia 60mg SID PRN.

Lab Results: July 2022 all WNLs. None performed since.

**SPECIES**

Date of Previous IntraPet Ultrasound: No previous.

Canine

Sedation: IV sedation.

**BREED**

Stat Report: Not requested.

Imaging Performed By: Rachel Brillhart, RDMS.

Mixed Breed

**ULTRASONOGRAPHIC EXAMINATION OF THE ABDOMEN****SEX****Urinary System**

Spayed Female

The **urinary bladder**, trigone, and pelvic urethra presented normal thicknesses and normal tone. The ureters were not visible which is normal. No uroliths or sediment were visualized and anechoic urine was present. No evidence of inflammatory or neoplastic changes were noted. Ureteral papillae were normal.

**AGE**

1/1/14

The **kidneys** revealed normal size and structure, corticomedullary definition and ratio for this age. The cortices presented largely uniform texture with normal echogenic relationship to liver and spleen. Medullary structure differed distinctly from the cortex and no evidence of pelvic dilation was present. The capsules were acceptably uniform without significant irregularities. The right kidney measured 5.73 cm. The left kidney measured 5.72 cm.

**WEIGHT**

55 Pounds

**Adrenal Glands****INTERPRETED BY**

Both **adrenal glands** were visualized and recognized as having normal shape, size, position and echogenicity for this breed. The phrenic vasculature, glandular echogenicity and detail were unremarkable. Capsule, cortex, and medullary definition were normal for this age patient. The left adrenal gland measured 3.72 cm x 0.52 cm at the caudal pole and 0.51 cm at the cranial pole. The right adrenal gland measured 3.12 cm x 0.53 cm at the caudal pole and 0.66 cm at the cranial pole.

Eric Lindquist, DMV  
DABVP, Cert. IVUSS**HOSPITAL NAME****Spleen**

Homeward Bound VS

The **spleen** was largely normal with occasional hypoechoic, mildly disruptive nodules, measuring up to 1.14 cm. No capsular expansion was noted. Differentials include hyperplasia, emerging round cell neoplasia, emerging hemangiosarcoma are possible.

**REFERRING VET****Liver**

Dr. Sorum

The **liver** images submitted revealed subjectively normal liver size, contour, and structure. Parenchymal echogenicity was naturally coarse and hypoechoic to the spleen. Vascular and biliary tracts were of normal volume with no evidence of congestion. The gallbladder presented acceptably thin walls with primarily anechoic content. The cystic and common bile ducts were normal. No pathological hepatic lymphadenopathy was evident. No overt structural evidence of inflammatory, infiltrative or regenerative pathology was evident.

**INVOICE**

21878

**Gastrointestinal**

Examination of the **gastrointestinal tract** revealed a stomach and intestine free of stasis, of normal wall thickness, acceptable curvilinear mural detail, and peristaltic activity. Small and large intestine demonstrated

normal luminal chyme and stool consistency respectively. No obstructive or overt infiltrative disease was noted. No associated abnormal lymphatic activity was noted.

### **Pancreas**

The base and limbs of the **pancreas** were observed to be largely isoechoic to surrounding omental fat. Pancreatic duct and capsular contour were acceptably normal and parenchyma respected normal curvilinear patterns. No overt evidence of active inflammatory or neoplastic disease was noted.

### **Other**

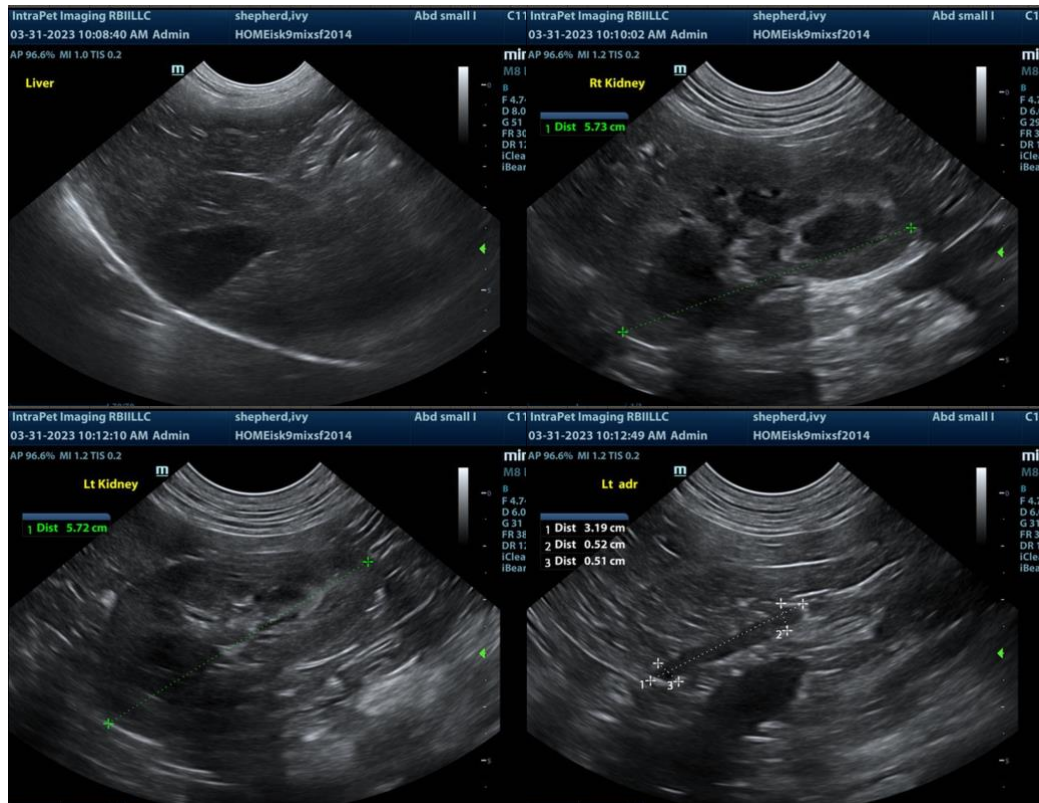
A rapid view of the **heart** revealed no evident pathology in the right auricle or pericardium. Contractility and volumes appear to be normal. No evidence of pericardial or pleural effusion.

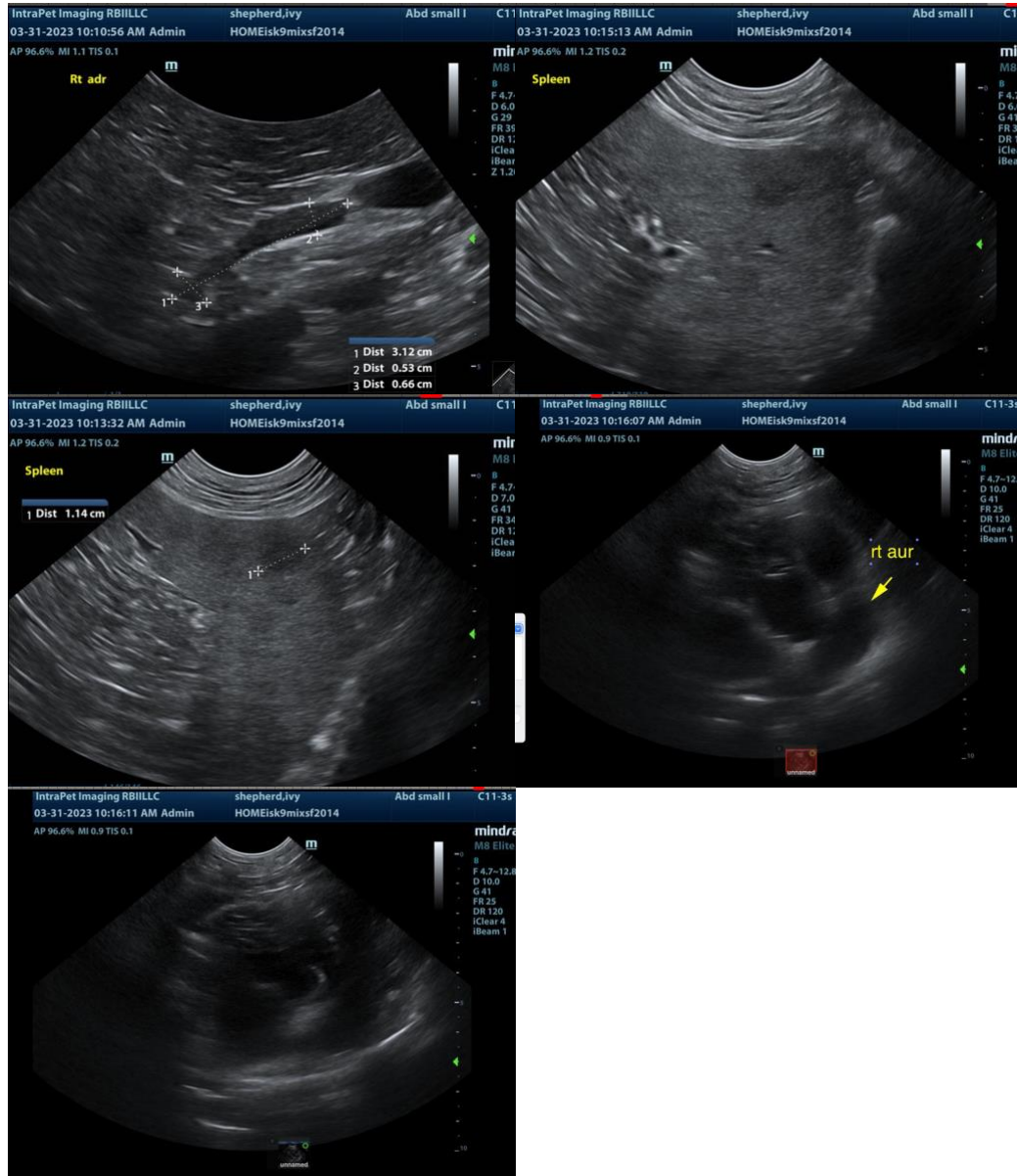
## **ULTRASONOGRAPHIC FINDINGS**

- Occasional hypoechoic, mildly disruptive nodules in the spleen. Differentials include hyperplasia, emerging round cell neoplasia or emerging hemangiosarcoma.

## **INTERPRETATION OF THE FINDINGS & FURTHER RECOMMENDATIONS**

The splenic nodules should be monitored over the next 3-4 weeks for any progression. FNA of the spleen is recommended for a cytological baseline.





The information and recommendations provided are based on the images presented by the referring veterinarian. No evaluation can be communicated regarding pathology that was not visible in the image/video clips provided.

Thank you for this referral. If the clinical or image interpretation does not parallel your findings or if I can be of any further assistance please contact me.

**Eric Lindquist**, DMV, DABVP, Cert. IVUSS, CEO of SonoPath.com  
info@SonoPath.com