

PATIENT

Cooper Troisi

SPECIES

Canine

BREED

Lab Retriever

SEX

Intact Male

AGE

13 Years 6 Months

WEIGHT

74 Pounds

INTERPRETED BY

Eric Lindquist, DMV
DABVP, Cert. IVUSS

IMAGING PERFORMED BY

John Ammeraal, DVM

HOSPITAL NAME

Sova AH

REFERRING VET

John Ammeraal, DVM

INVOICE

21870

DATE

3/31/23

PRESENTING CLINICAL SIGNS

History: Presented for anorexia a few days ago. Hx of chronic DJD elbows and hocks, On Meloxicam 3.75 mg SID for a few years, Amantadine 100 mg q 24 hrs. was on Finasteride 5 mg q 24 hours but that was stopped 6 months ago. Gets Gabapentin once in while but causes sedation

Abnormal PE/Chem/CBC/UA Results: Hind limbs weakness secondary LS disease, elbow/hock DJD Chemistry Aug 22 all normal Chemistry 03/30- BUN 61 mg/dL, Crea 2.6 mg/dL, SDMA 17.3 UPC 1.2, WBC 4-10, RBC 11-20 USG 1.029- Free Catch Urine culture - sample obtained today and submitted via cyto

LIMITED ULTRASONOGRAPHIC EXAMINATION

Urinary System

The **urinary bladder** revealed a mild amount of suspended debris and overdistention at the time of the sonogram. No overt calculi were noted. Pelvic urethral dilation was noted.

The **prostate** was slightly enlarged, uniform, measuring 3.5 cm.

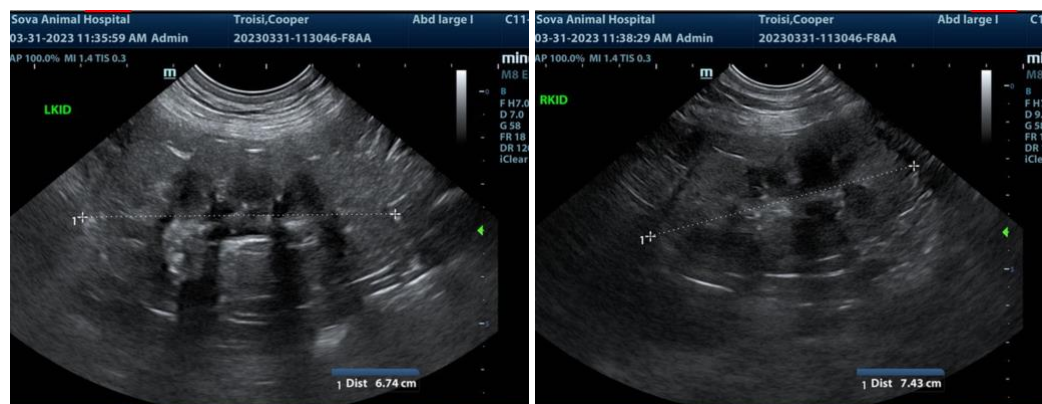The **kidneys** revealed irregular contour and multifocal cortical collapse. Areas of mineralization and pyelectasia were noted. The degenerative changes are subjectively near end-stage. The left kidney measured 6.74 cm. The right kidney measured 7.43 cm. Cortical infarcts and nonobstructive calculi were noted in both kidneys.

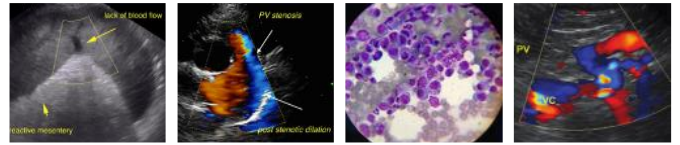
ULTRASONOGRAPHIC FINDINGS

- Chronic degenerative renal disease with pyelectasia and likely pyelonephritis
- Urinary bladder debris and pelvic urethral dilation
- Slightly enlarged prostate

INTERPRETATION OF THE FINDINGS & FURTHER RECOMMENDATIONS

72-hour IV fluid protocol, urine culture and blood pressures are indicated. Prognosis is guarded.





PATIENT

Cooper Troisi

SPECIES

Canine

BREED

Lab Retriever

SEX

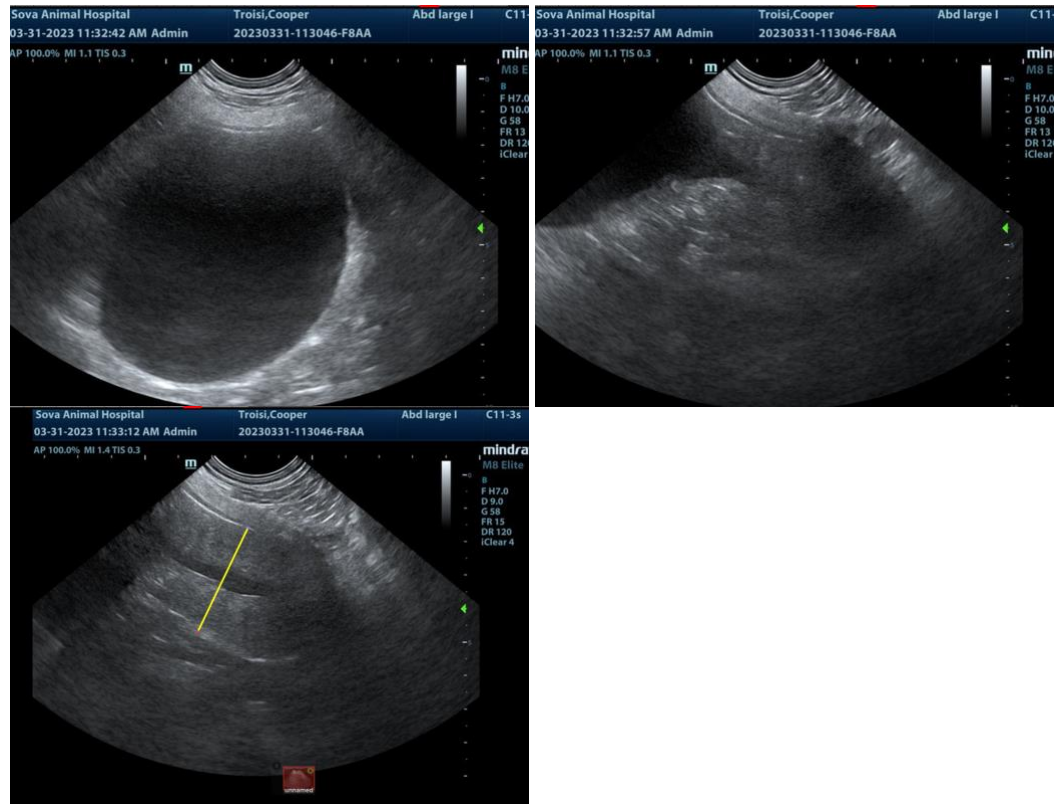
Intact Male

AGE

13 Years 6 Months

WEIGHT

74 Pounds



INTERPRETED BY

Eric Lindquist, DMV
DABVP, Cert. IVUSS

IMAGING PERFORMED BY

John Ammeraal, DVM

HOSPITAL NAME

Sova AH

REFERRING VET

John Ammeraal, DVM

INVOICE

21870

DATE

3/31/23

The information and recommendations provided are based on the images presented by the referring veterinarian. No evaluation can be communicated regarding pathology that was not visible in the image/video clips provided.

Thank you for this referral. If the clinical or image interpretation does not parallel your findings or if I can be of any further assistance please contact me.

Eric Lindquist, DMV, DABVP, Cert. IVUSS, CEO of SonoPath.com
info@SonoPath.com