



PATIENT PRESENTING CLINICAL SIGNS

Angel Martin Heart murmur, cardiomegaly weight loss dental disease joint disease

SPECIES Abnormal PE/Chem/CBC/UA Results: Heart Rate and Respiratory Rates Heart Rate: 150, Respiratory: 36/increased Blood Pressure Measurements None available Current Medications
Canine Furosemide 12.5mg 1/2 tab BID; Vetmedin 1.25mg 1/2 tab BID

BREED ULTRASONOGRAPHIC EXAMINATION OF THE HEART

Chihuahua

SEX

Spayed Female

AGE

15 Years

WEIGHT

5 Pounds

INTERPRETED BY

Eric Lindquist, DMV

DABVP, Cert. IVUSS

CANINE CARDIAC PARAMETERS	MR VMAX (m/s)	TR VMAX (m/s)	LA/AO (Boon method)	LA/AO (Heart Base; Swe)	FS (%)	EF (%)	EPSS (cm)
NORMAL PARAMETER	4.5-5.5	<2.7	1.3	<1.6	28-40	40-100	<0.6
PATIENT	5.0		1.27	1.8	50	83	NM
CANINE CARDIAC PARAMETERS	HR (BPM)	AV VMAX (m/s)	PV MAX (m/s)	BODY WEIGHT (kg)	LA 2D short axis Base view (cm)	LVIDd Avg; 2D and m-mode short axis (cm)	LVIDs Avg; 2D and m-mode short axis (cm)
NORMAL PARAMETER	50-100	0.7-1.7	0.7-1.6	BELOW	BELOW	BELOW	BELOW
PATIENT		1.3	0.81		2.65	2.96	

IMAGING PERFORMED BY

Sara Hansen

HOSPITAL NAME

Countryside AC

REFERRING VET

Dr. Cox

INVOICE

46354

DATE

3/31/23

Cardiac Presentation

The echocardiogram for this patient presented excessive **left atrial size** expressed both in the LA/AO and LA max measurements Chamber volumes and echogenicity were normal. The cranial and caudal **mitral** valve leaflets presented vegetative thickening consistent with endocardiosis. Doppler indicated measurable insufficiency. The **left ventricle** presented thicknesses with linear contour and was not dilated nor restricted. The **myocardium** presented normal echogenicity without subjective evidence of significant fibrotic or ischemic disease. **Contractility** of the ventricular walls was adequate and in normal range for this patient evidenced by the fractional shortening measurement and subjective evaluation of the different regions of the myocardium. The **left ventricular outflow** tract demonstrated normal laminar flow and subjective structural integrity. The **right atrium** and auricle revealed normal size, structure and content. No evidence of masses was noted or chamber overload. **Tricuspid** valvular assessment demonstrated adequate linear morphology. The **right ventricle** was of normal size (1/3 diameter of LV), chordae structure, myocardial echogenicity and thickness. **Pulmonic** tract assessment revealed normal valve structure, laminar flow, and diameter (approx. 1:1 pa/ao ratio). No visible **pericardial** or free pleura fluid was noted. No echographically detectable evidence of infiltrative disease was visible. The cranial **mediastinum and pericardial regions** were free of masses in the visible window.

ULTRASONOGRAPHIC FINDINGS

- Largely compensated mitral insufficiency under current protocol



PATIENT

Angel Martin

SPECIES

Canine

BREED

Chihuahua

SEX

Spayed Female

AGE

15 Years

WEIGHT

5 Pounds

INTERPRETED BY

Eric Lindquist, DMV
DABVP, Cert. IVUSS

IMAGING PERFORMED BY

Sara Hansen

HOSPITAL NAME

Countryside AC

REFERRING VET

Dr. Cox

INVOICE

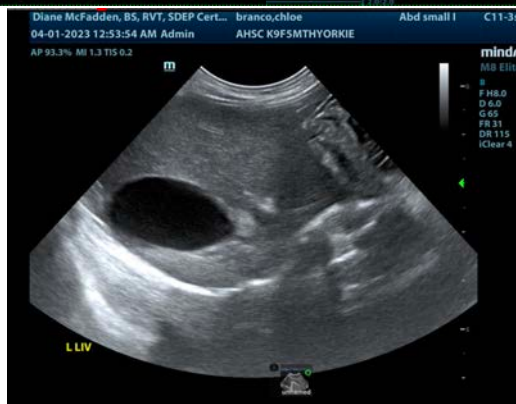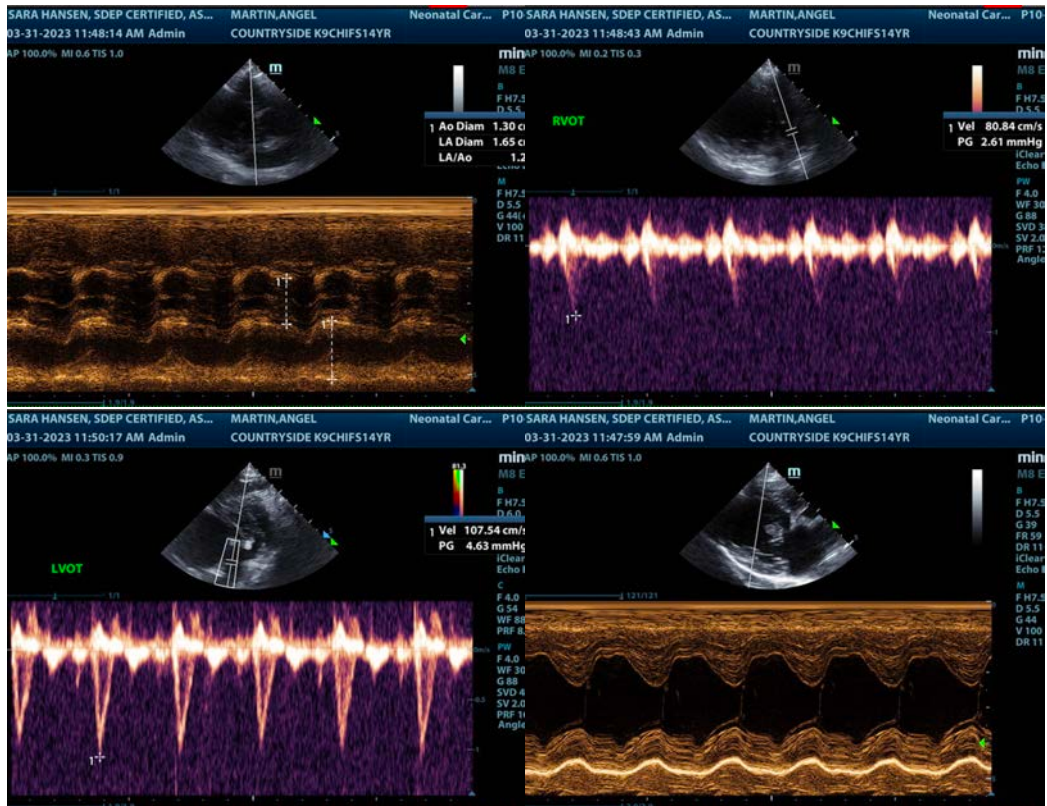
46354

DATE

3/31/23

INTERPRETATION OF THE FINDINGS & FURTHER RECOMMENDATIONS

n Recommend consideration of ACE inhibitor therapy at 0.5 mg/kg SID progressing to BID. Evaluation of left atrial size was best performed in LA max position.





PATIENT

Angel Martin

The information and recommendations provided are based on the images presented by the referring veterinarian/sonographer. No evaluation can be communicated regarding pathology that was not visible in the image/video clips provided.

SPECIES

Canine

Thank you for this referral. If the clinical or image interpretation does not parallel your findings or if I can be of any further assistance please contact me.

BREED

Chihuahua

Eric Lindquist, DMV, DABVP, Cert. IVUSS, CEO of SonoPath.com

info@SonoPath.com

SEX

Spayed Female

AGE

15 Years

WEIGHT

5 Pounds

INTERPRETED BY

Eric Lindquist, DMV
DABVP, Cert. IVUSS

**IMAGING
PERFORMED BY**

Sara Hansen

HOSPITAL NAME

Countryside AC

REFERRING VET

Dr. Cox

INVOICE

46354

DATE

3/31/23