



**PATIENT**

Jake Gray

**PRESENTING CLINICAL SIGNS**

Presented for health cert. Arrhythmia noted on PE. He would become cyanotic in lateral recumbancy  
Abnormal PE/Chem/CBC/UA Results: Arrhythmia V tach noted on monitor HR approx 220-250 BP 144/118

**SPECIES**

Canine

**ULTRASONOGRAPHIC EXAMINATION OF THE HEART**

BREED	CANINE CARDIAC PARAMETERS	MR VMAX (m/s)	TR VMAX (m/s)	LA/AO (Boon method)	LA/AO (Heart Base; Swe)	FS (%)	EF (%)	EPSS (cm)
Chihuahua								
<b>SEX</b>	<b>NORMAL PARAMETER</b>	4.5-5.5	<2.7	1.3	<1.6	28-40	40-100	<0.6
Intact Male	<b>PATIENT</b>			1.2	1.4	~30		NM
AGE	CANINE CARDIAC PARAMETERS	HR (BPM)	AV VMAX (m/s)	PV MAX (m/s)	BODY WEIGHT (kg)	LA 2D short axis Base view (cm)	LVIDd Avg; 2D and m-mode short axis (cm)	LVIDs Avg; 2D and m-mode short axis (cm)
7 Years								
<b>WEIGHT</b>	<b>NORMAL PARAMETER</b>	50-100	0.7-1.7	0.7-1.6	BELOW	BELOW	BELOW	BELOW
6 Pounds	<b>PATIENT</b>	Variable	--	0.7		2.0	1.94	

**INTERPRETED BY**

Eric Lindquist, DMV  
DABVP, Cert. IVUSS

**Cardiac Presentation**

The cardiac presentation revealed severe tachyarrhythmia. Internal diameters, contractility and valvular structures appeared normal. No evidence of volume overload that is influencing the arrhythmia. No pericardial or pleural effusion noted.

**IMAGING PERFORMED BY**

Dr. Adrienne Waffle

**ULTRASONOGRAPHIC FINDINGS**

- Myocarditis or idiopathic arrhythmogenic activity suspected

**HOSPITAL NAME**

Torch Lake VC

**INTERPRETATION OF THE FINDINGS & FURTHER RECOMMENDATIONS**

Treatment should be based on EKG results +/- holter monitor.

**REFERRING VET**

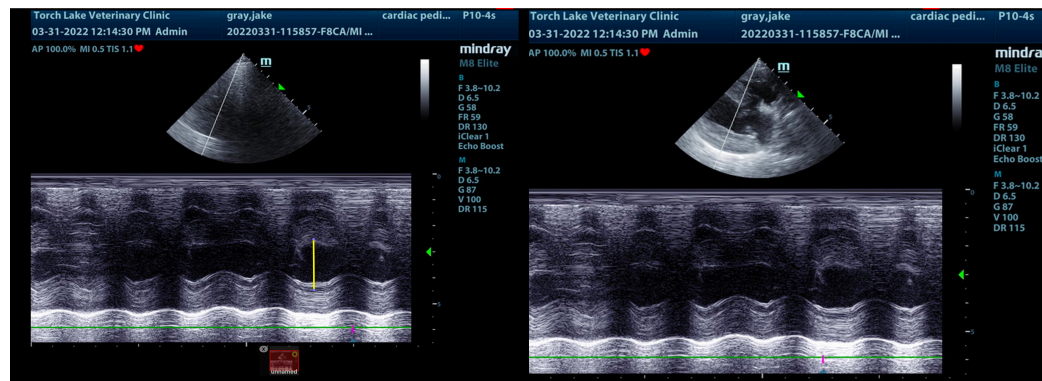
Dr. Adrienne Waffle

**INVOICE**

36615

**DATE**

3/31/22





**PATIENT**

Jake Gray

**SPECIES**

Canine

**BREED**

Chihuahua

**SEX**

Intact Male

**AGE**

7 Years

**WEIGHT**

6 Pounds

**INTERPRETED BY**

Eric Lindquist, DMV

DABVP, Cert. IVUSS

**IMAGING PERFORMED BY**

Dr. Adrienne Waffle

**HOSPITAL NAME**

Torch Lake VC

**REFERRING VET**

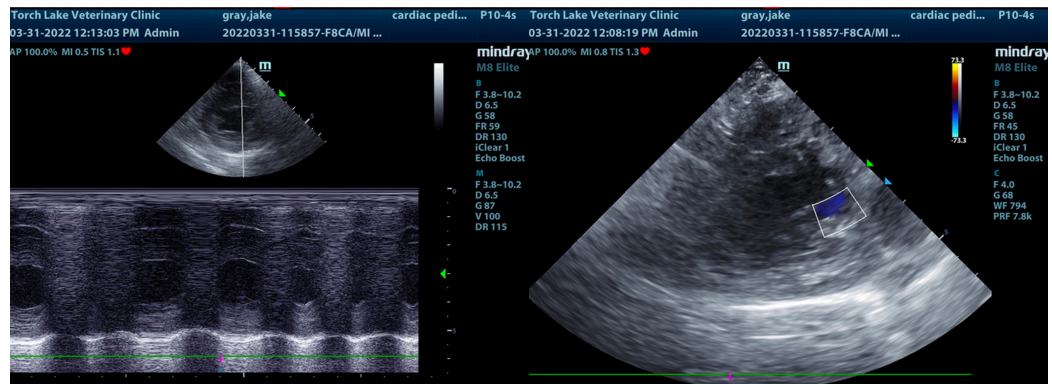
Dr. Adrienne Waffle

**INVOICE**

36615

**DATE**

3/31/22



The information and recommendations provided are based on the images presented by the referring veterinarian/sonographer. No evaluation can be communicated regarding pathology that was not visible in the image/video clips provided.

Thank you for this referral. If the clinical or image interpretation does not parallel your findings or if I can be of any further assistance please contact me.

Eric Lindquist, DMV, DABVP, Cert. IVUSS, CEO of SonoPath.com

[info@SonoPath.com](mailto:info@SonoPath.com)