

## PATIENT

Wylie Jordan

## SPECIES

Canine

## BREED

Standard Poodle

## SEX

Male

## AGE

6 years

## WEIGHT

57 lbs

## INTERPRETED BY

Eric Lindquist, DMV  
DABVP, Cert. IVUSS

## IMAGING PERFORMED BY

Katharine Nowland,  
DVM

## HOSPITAL NAME

TotalBond VH

## REFERRING VET

Dr. Nowland

## INVOICE

78380

## DATE

3/30/26

## PRESENTING CLINICAL SIGNS

- Patient presented with seizure activity last week. Started on phenobarbital. O wanted to pursue chest x-rays and abdominal ultrasound for workup prior to deciding on moving forward with an MRI.
- Abnormal PE/Chem/CBC/UA Results: Normal

## ULTRASONOGRAPHIC EXAMINATION OF THE ABDOMEN

### Urinary System

The **urinary bladder**, trigone, and pelvic urethra presented normal thicknesses and normal tone. The ureters were not visible which is normal. No uroliths or sediment were visualized and anechoic urine was present. No evidence of inflammatory or neoplastic changes was noted. Ureteral papillae were normal.

The **kidneys** revealed normal size and structure, corticomedullary definition and ratio for this age. The cortices presented largely uniform texture with normal echogenic relationship to liver and spleen. Medullary structure differed distinctly from the cortex and no evidence of pelvic dilation was present. The capsules were acceptably uniform without significant irregularities. The left kidney measured 6.28 cm. The right kidney measured 6.83 cm.

### Adrenal Glands

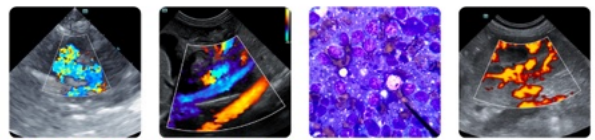
The **left adrenal gland** was visualized and recognized as having normal shape, size, position and echogenicity for this breed. The phrenic vasculature, glandular echogenicity and detail were unremarkable. Capsule, cortex, and medullary definition were normal for this age patient. The left adrenal gland measured 0.69 cm. The right adrenal gland was not visualized; however, the region of the right adrenal gland revealed no evidence of pathology.

### Spleen

The **spleen** revealed slight heterogenous changes with uniform enlargement. There were no evident masses.

### Liver

The **liver** images submitted revealed subjectively normal liver size, contour, and structure. Parenchymal echogenicity was naturally coarse and hypoechoic to the spleen. Vascular and biliary tracts were of normal volume with no evidence of congestion. The gallbladder presented acceptably thin walls with primarily anechoic content. The cystic and common bile ducts were normal. No pathological hepatic lymphadenopathy was evident. No overt structural evidence of inflammatory, infiltrative or regenerative pathology was evident.



**PATIENT**

Wylie Jordan

**SPECIES**

Canine

**BREED**

Standard Poodle

**SEX**

Male

**AGE**

6 years

**WEIGHT**

57 lbs

**INTERPRETED BY**

Eric Lindquist, DMV  
DABVP, Cert. IVUSS

**IMAGING PERFORMED BY**

Katharine Nowland,  
DVM

**HOSPITAL NAME**

TotalBond VH

**REFERRING VET**

Dr. Nowland

**INVOICE**

78380

**DATE**

3/30/26

**Gastrointestinal**

Examination of the **gastrointestinal tract** revealed a stomach and intestine free of stasis, of normal wall thickness, acceptable curvilinear mural detail, and peristaltic activity. Small and large intestine demonstrated normal luminal chyme and stool consistency respectively. No obstructive or overt infiltrative disease was noted. No associated abnormal lymphatic activity was noted.

**Pancreas**

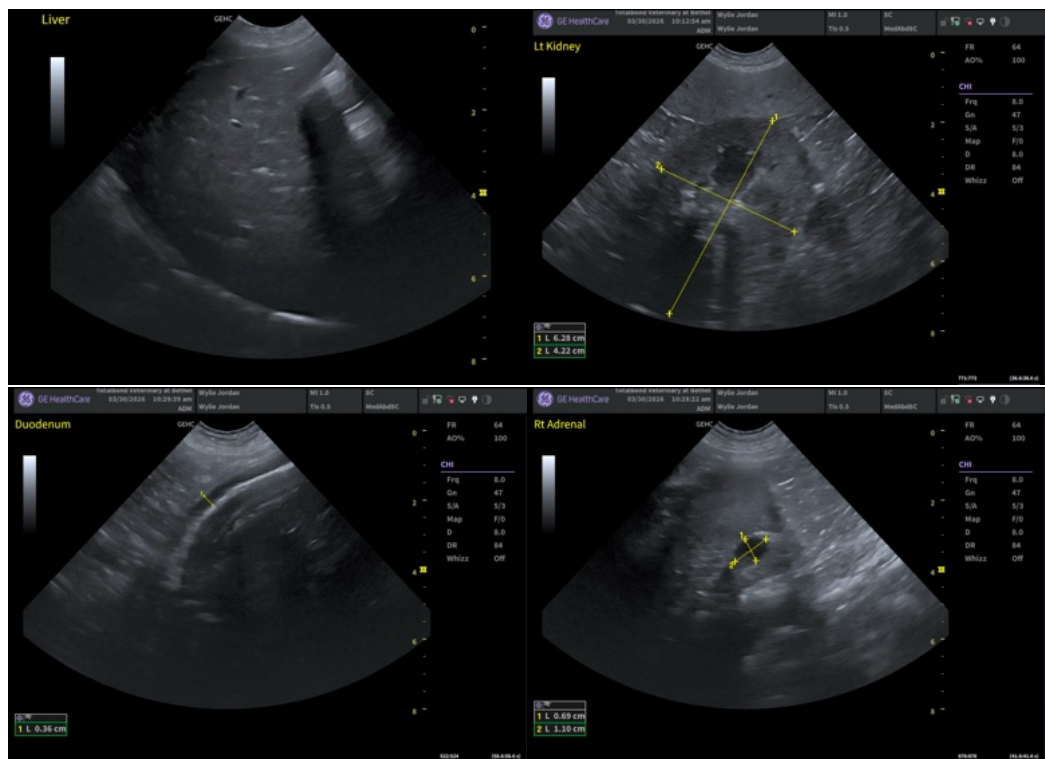
The base and limbs of the **pancreas** were observed to be largely isoechoic to surrounding omental fat. Pancreatic duct and capsular contour were acceptably normal and parenchyma respected normal curvilinear patterns. No overt evidence of active inflammatory or neoplastic disease was noted.

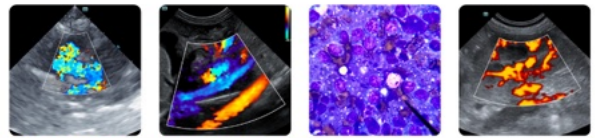
**ULTRASONOGRAPHIC FINDINGS**

Structurally unremarkable abdomen.

**INTERPRETATION OF THE FINDINGS & FURTHER RECOMMENDATIONS**

There was no evidence of pathology. The cause of seizure activity does not have an abdominal source.





## PATIENT

Wylie Jordan

## SPECIES

Canine

## BREED

Standard Poodle

## SEX

Male

## AGE

6 years

## WEIGHT

57 lbs

## INTERPRETED BY

Eric Lindquist, DMV  
DABVP, Cert. IVUSS

## IMAGING PERFORMED BY

Katharine Nowland,  
DVM

## HOSPITAL NAME

TotalBond VH

## REFERRING VET

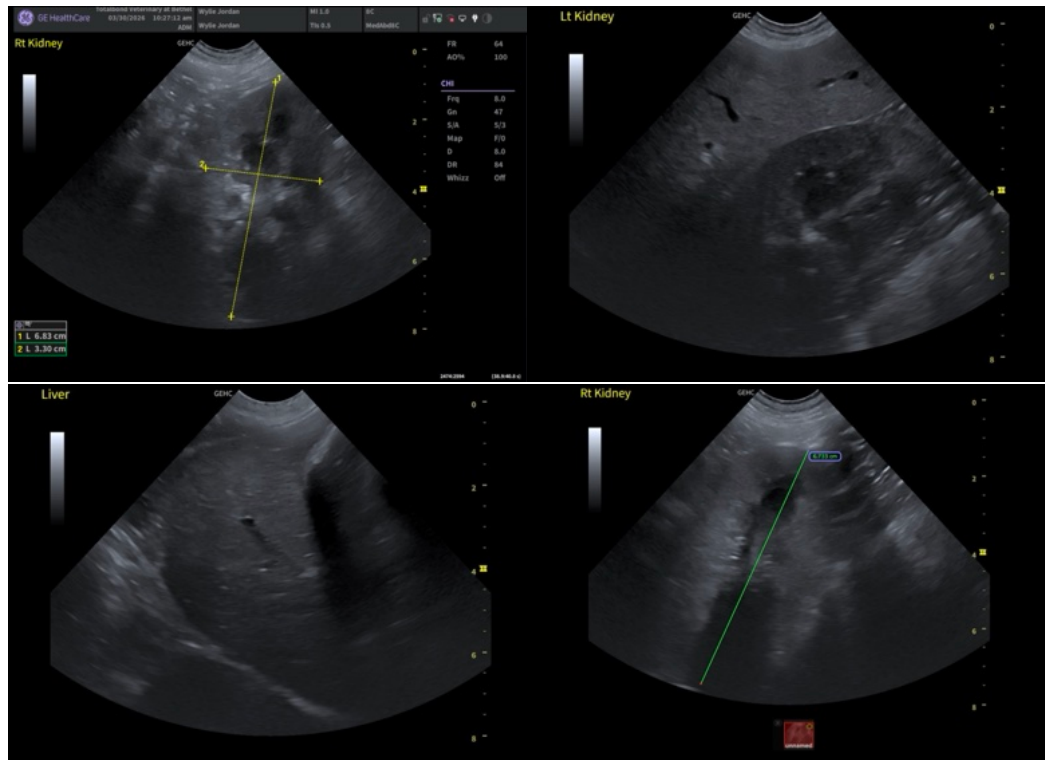
Dr. Nowland

## INVOICE

78380

## DATE

3/30/26



The information and recommendations provided are based on the images presented by the referring veterinarian/sonographer. No evaluation can be communicated regarding pathology that was not visible in the image/video clips provided.

Thank you for this referral. If the clinical or image interpretation does not parallel your findings or if I can be of any further assistance please contact me.

Eric Lindquist, DMV, DABVP (CFM), Cert. IVUSS, CEO of SonoPath.com

[info@SonoPath.com](mailto:info@SonoPath.com)