



## PATIENT

Sugar Shi

## SPECIES

Canine

## BREED

Alaskan Malamute

## SEX

Intact male

## AGE

11 years

## WEIGHT

95 lbs

## INTERPRETED BY

Eric Lindquist, DMV  
DABVP, Cert. IVUSS

## IMAGING PERFORMED BY

Dr. Li

## HOSPITAL NAME

Dr. Shen Li VS

## REFERRING VET

Dr. Li

## INVOICE

73902

## DATE

3/30/26

## PRESENTING CLINICAL SIGNS

- Progressive stiffness in all four limbs
- chronic small perianal draining tracts
- Benign tail base sebaceous growth
- Wellness check
- CBC/chem/lytes/T4 WNL 4dx fecal negative USG 1.011, no change in water intake, has been drinking a lot and urinating a lot for years.

## ULTRASONOGRAPHIC EXAMINATION OF THE ABDOMEN

### Urinary System

The **urinary bladder**, trigone, and pelvic urethra presented normal thicknesses and normal tone. The ureters were not visible which is normal. No uroliths or sediment were visualized and anechoic urine was present. No evidence of inflammatory or neoplastic changes was noted. Ureteral papillae were normal.

The **kidneys** revealed normal size and structure, corticomedullary definition and ratio for this age. The cortices presented largely uniform texture with normal echogenic relationship to liver and spleen. Medullary structure differed distinctly from the cortex and no evidence of pelvic dilation was present. The capsules were acceptably uniform without significant irregularities. The right kidney measured 7.26 cm. The left kidney measured 8.54 cm.

The **prostate** was uniformly enlarged with lobar swelling appeared to impinge upon the urethra and mildly deviate the descending colon. The prostatic tissue was hyperechoic containing focal areas of decreased echogenicity. These changes are suggestive of either chronic inflammatory episodes, benign cystic pathology or both. Underlying neoplasia cannot be completely ruled-out but is lower on the differential list. This presentation is most consistent with benign prostatic hyperplasia with possible active prostatitis. Neutering or off-label Finasteride (Propecia) (0.1-0.5 mg/kg Sid) treatment is indicated +/- FNA or prostatic wash cytology and culture.

### Adrenal Glands

The **adrenal glands** were not overtly visualized. However, the regions of the adrenal glands appeared unremarkable.

### Spleen

The **spleen** presented a smooth homogeneous parenchyma hyperechoic to liver and renal cortical parenchyma. The capsule was smooth without noticeable expansion or deviation from within the spleen or adjacent pathology. The splenic vasculature demonstrated normal volume without signs of congestion or thrombosis. No sonographic evidence of acute or chronic inflammatory, neoplastic, or infarctual changes was noted.



## PATIENT

Sugar Shi

## SPECIES

Canine

## BREED

Alaskan Malamute

## SEX

Intact male

## AGE

11 years

## WEIGHT

95 lbs

## INTERPRETED BY

Eric Lindquist, DMV  
DABVP, Cert. IVUSS

## IMAGING PERFORMED BY

Dr. Li

## HOSPITAL NAME

Dr. Shen Li VS

## REFERRING VET

Dr. Li

## INVOICE

73902

## DATE

3/30/26

## Liver

The **liver** images from right and left intercostal as well as subcostal views revealed subjectively normal liver size, contour, and structure. Some age-related parenchymal remodeling was noted but likely not clinically significant at this time. Vascular and biliary tracts were of normal volume and no evidence of congestion was noted. The gallbladder presented some dependent debris with essentially normal contour. The cystic and common bile ducts were normal. No overt evidence of active inflammatory, infiltrative or regenerative pathology was noted but should be paired with current or past LE elevations regarding any clinical significance to this presentation. The hepatic lymph nodes were unremarkable.

## Gastrointestinal

There was some residual chyme and gas was noted in the **stomach**, yet not pathological. This is consistent with post prandial presentation. Transit of chyme into the small intestine was normal. Curvilinear patterns were maintained throughout the GI tract. No evidence of pathology. Small and large intestine demonstrated normal luminal chyme and stool consistency respectively. No obstructive or overt infiltrative disease was noted. No associated abnormal lymphatic activity was noted.

## Pancreas

The base and limbs of the **pancreas** were observed to be largely isoechoic to surrounding omental fat. Pancreatic duct and capsular contour were acceptably normal and parenchyma respected normal curvilinear patterns. No overt evidence of active inflammatory or neoplastic disease was noted.

## ULTRASONOGRAPHIC FINDINGS

BPH prostate.

Otherwise, unremarkable geriatric abdomen.

## INTERPRETATION OF THE FINDINGS & FURTHER RECOMMENDATIONS

There was no evidence of significant disease. If any prostatic signs are present then neutering should be considered. The cause of PU/PD is unclear; however, sedation would be necessary to fully image the adrenal glands given the size of the patient.



**PATIENT**

Sugar Shi

**SPECIES**

Canine

**BREED**

Alaskan Malamute

**SEX**

Intact male

**AGE**

11 years

**WEIGHT**

95 lbs

**INTERPRETED BY**

Eric Lindquist, DMV  
DABVP, Cert. IVUSS

**IMAGING  
PERFORMED BY**

Dr. Li

**HOSPITAL NAME**

Dr. Shen Li VS

**REFERRING VET**

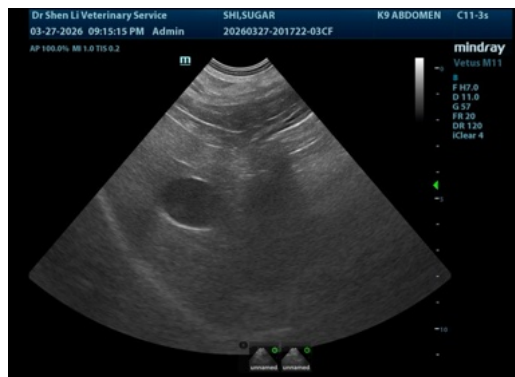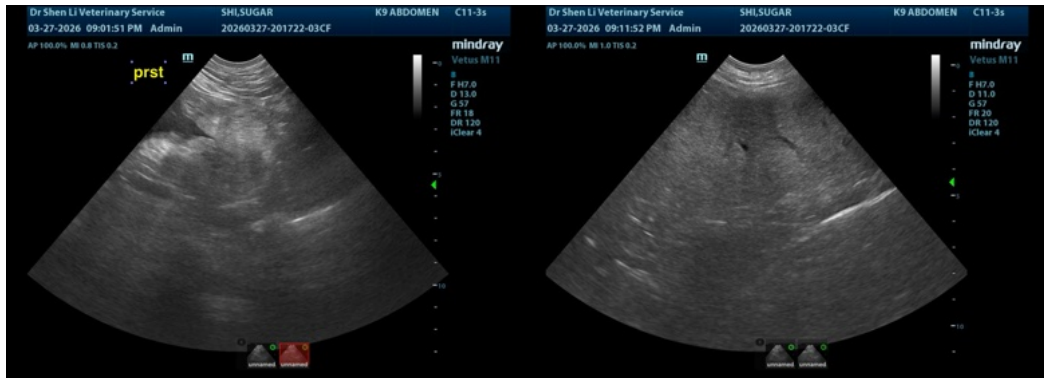
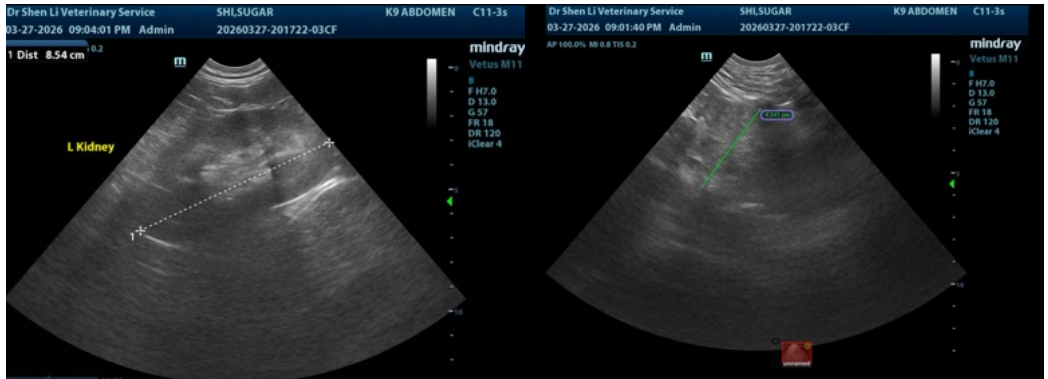
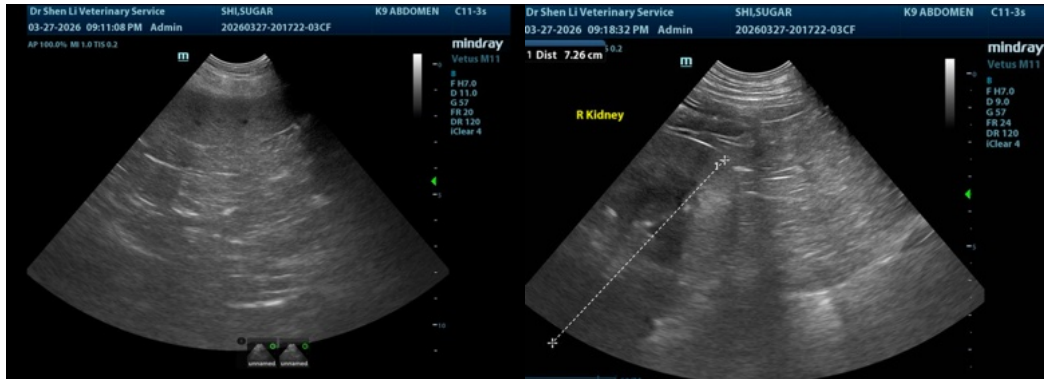
Dr. Li

**INVOICE**

73902

**DATE**

3/30/26





## PATIENT

Sugar Shi

## SPECIES

Canine

## BREED

Alaskan Malamute

## SEX

Intact male

## AGE

11 years

## WEIGHT

95 lbs

## INTERPRETED BY

Eric Lindquist, DMV  
DABVP, Cert. IVUSS

## IMAGING PERFORMED BY

Dr. Li

## HOSPITAL NAME

Dr. Shen Li VS

## REFERRING VET

Dr. Li

## INVOICE

73902

## DATE

3/30/26

The information and recommendations provided are based on the images presented by the referring veterinarian/sonographer. No evaluation can be communicated regarding pathology that was not visible in the image/video clips provided.

Thank you for this referral. If the clinical or image interpretation does not parallel your findings or if I can be of any further assistance please contact me.

Eric Lindquist, DMV, DABVP (CFM), Cert. IVUSS, CEO of SonoPath.com

[info@SonoPath.com](mailto:info@SonoPath.com)