

PATIENT

Remi Kelly

SPECIES

Canine

BREED

Lab

SEX

Spayed Female

AGE

8

WEIGHT

72

INTERPRETED BY

Eric Lindquist, DMV

DABVP, Cert. IVUSS

IMAGING PERFORMED BY

Tasha

HOSPITAL NAME

Dillsburg Vet Clinic

REFERRING VET

Dr. Crow

INVOICE

46330

DATE

3/30/23

PRESENTING CLINICAL SIGNS

Ruling out mass due to sudden onset of ventricular arrhythmia. On tylosan powder
Abnormal PE/Chem/CBC/UA Results: WNL

ULTRASONOGRAPHIC EXAMINATION OF THE ABDOMEN

Urinary System

The urinary bladder was not visualized.

The left kidney measured 6.0 cm.

The right kidney was not visualized.

Adrenal Glands

The adrenal glands were not visualized.

Spleen

Portions of the spleen were imaged, no obvious pathology.

Liver

The visible liver was unremarkable with normal parenchyma.

Gastrointestinal

The visible gastrointestinal tract was unremarkable.

Pancreas

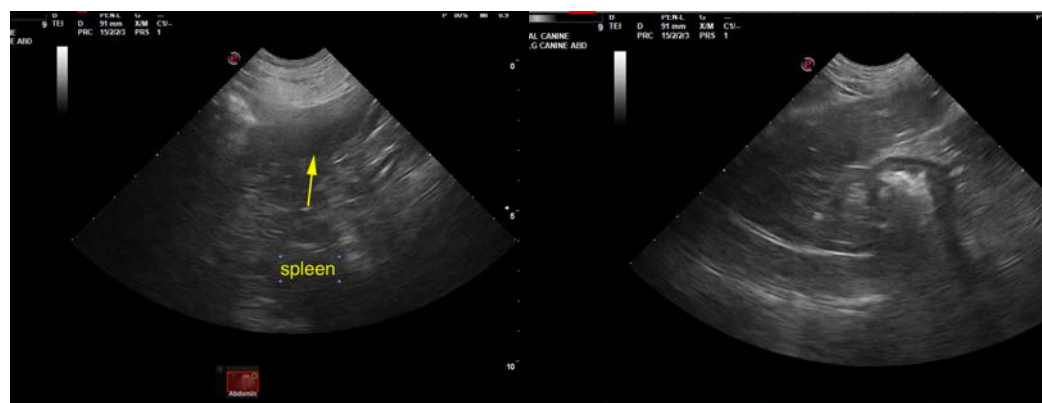The pancreas was not visualized.

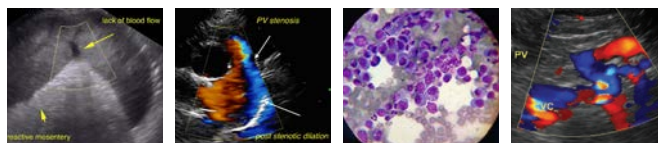
ULTRASONOGRAPHIC FINDINGS

- No visible global pathology

INTERPRETATION OF THE FINDINGS & FURTHER RECOMMENDATIONS

Interpretation of this case was exceedingly difficult owing to poor resolution. However, no global pathology evident.





PATIENT

Remi Kelly

SPECIES

Canine

BREED

Lab

SEX

Spayed Female

AGE

8

WEIGHT

72

INTERPRETED BY

Eric Lindquist, DMV

DABVP, Cert. IVUSS

IMAGING PERFORMED BY

Tasha

HOSPITAL NAME

Dillsburg Vet Clinic

REFERRING VET

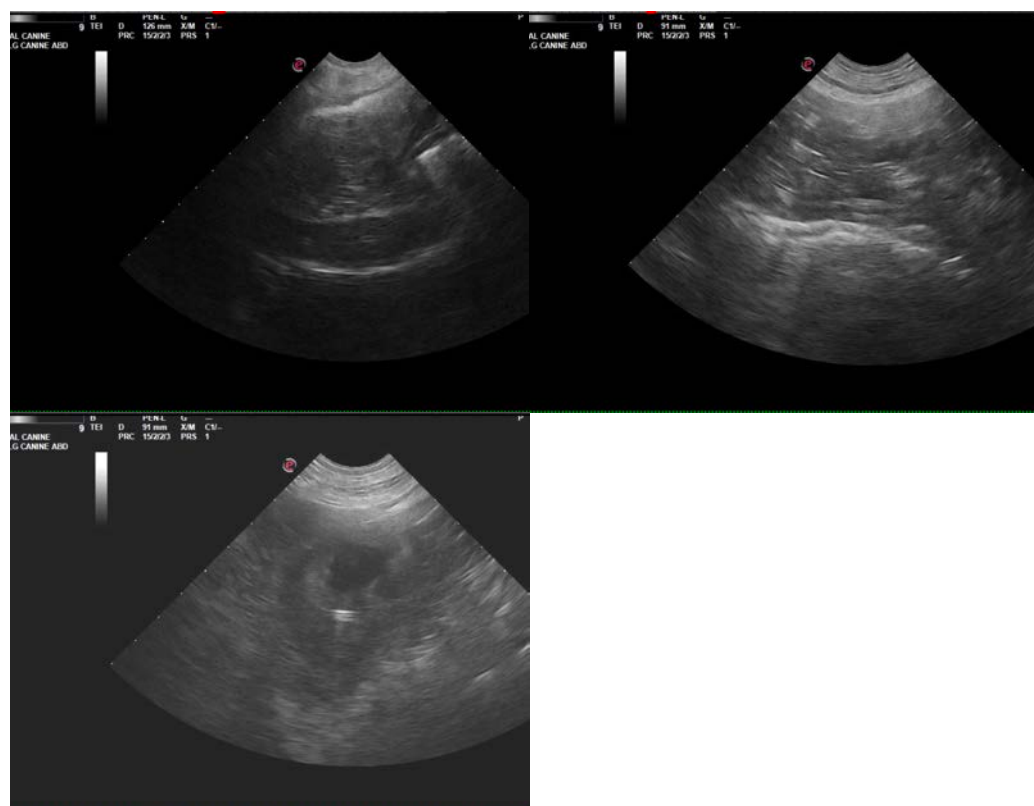
Dr. Crow

INVOICE

46330

DATE

3/30/23



The information and recommendations provided are based on the images presented by the referring veterinarian/sonographer. No evaluation can be communicated regarding pathology that was not visible in the image/video clips provided.

Thank you for this referral. If the clinical or image interpretation does not parallel your findings or if I can be of any further assistance please contact me.

Eric Lindquist, DMV, DABVP, Cert. IVUSS, CEO of SonoPath.com

info@SonoPath.com