



**PATIENT PRESENTING CLINICAL SIGNS**

**Pip Rau** History: Presented as a 12 week old kitten in Sept for hematuria, vomiting and lethargy, constipation. Had elevated BUN of 83 and normal creatinine of 1.3 at the time. Abdominal US done 9-9; pyelectasia, pyelonephritis, renal calculi in RK with echogenic debris. Subnormal blood flow Has been on kidney diet and doing well. Presented today for neuter and targeted us of kidneys, urinary bladder for monitoring

**Feline** Abnormal PE/Chem/CBC/UA Results: Normal labs 4 weeks ago; BUN 28, creatinine 1.2, USG 1.047

**BREED ULTRASONOGRAPHIC EXAMINATION OF THE ABDOMEN**

**Domestic Longhair**

**Urinary System**

**SEX**

**Neutered male**

The **urinary bladder**, trigone, and pelvic urethra presented normal thicknesses and normal tone. The ureters were not visible which is normal. No uroliths or sediment were visualized and anechoic urine was present. No evidence of inflammatory or neoplastic changes was noted. Ureteral papillae were normal.

**AGE**

**10 months**

The **kidneys** revealed hyperechoic medullary rim sign. The kidneys were normal in size with fairly normal contour. Pelvic mineralization was noted in the right kidney. The patient may be passing calculi periodically. The left kidney measured 3.28 cm. The right kidney measured 3.23 cm.

**WEIGHT**

**7.6 lbs**

**ULTRASONOGRAPHIC FINDINGS**

Medullary rim kidney with pelvic mineralization.

**INTERPRETED BY**

Eric Lindquist, DMV  
DABVP, Cert. IVUSS

**INTERPRETATION OF THE FINDINGS & FURTHER RECOMMENDATIONS**

The lower urinary tract was unremarkable, the bladder was near empty. Given the age of the patient, the renal mineralization and medullary rim sign I recommend bile acid profile. If elevated then assessment for portosystemic shunting is indicated as this is significantly abnormal for a 10 month old. Underlying FIP is also a potential given the medullary rim sign. Primary renal dysplasia is also possible. The prognosis is long term is guarded.

**IMAGING PERFORMED BY**

Dr. Carter

**HOSPITAL NAME**

Willamette VH

**REFERRING VET**

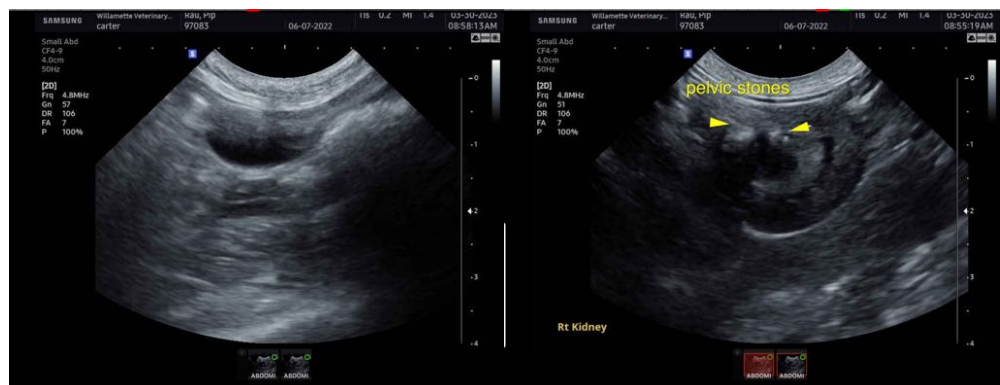Dr. Carter

**INVOICE**

43641

**DATE**

3/30/23





**PATIENT**

Pip Rau

**SPECIES**

Feline

**BREED**

Domestic Longhair

**SEX**

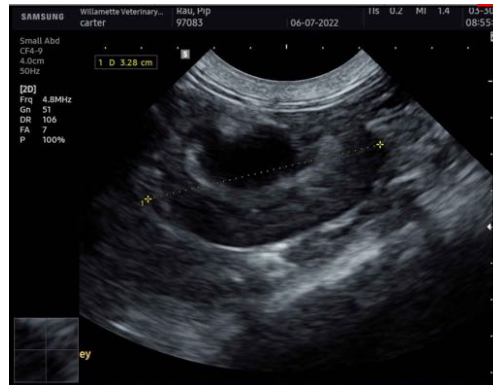
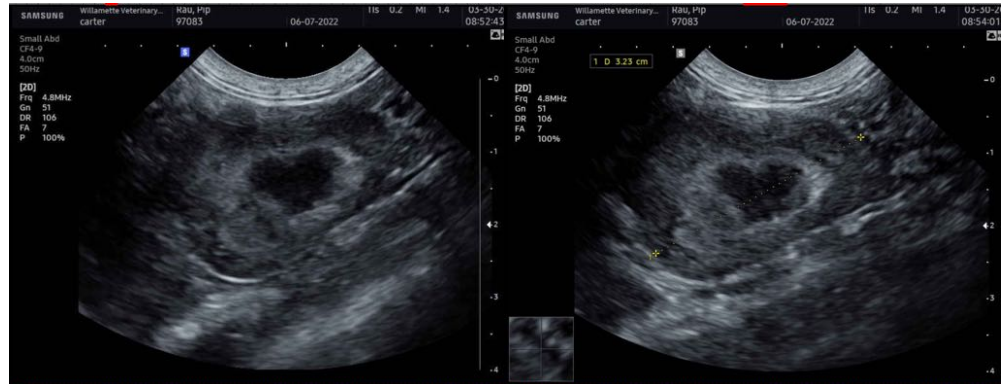Neutered male

**AGE**

10 months

**WEIGHT**

7.6 lbs



**INTERPRETED BY**

Eric Lindquist, DMV  
DABVP, Cert. IVUSS

**IMAGING PERFORMED BY**

Dr. Carter

**HOSPITAL NAME**

Willamette VH

**REFERRING VET**

Dr. Carter

**INVOICE**

43641

**DATE**

3/30/23

**The information and recommendations provided are based on the images presented by the referring veterinarian/sonographer. No evaluation can be communicated regarding pathology that was not visible in the image/video clips provided.**

Thank you for this referral. If the clinical or image interpretation does not parallel your findings or if I can be of any further assistance please contact me.

**Eric Lindquist, DMV, DABVP, Cert. IVUSS, CEO of SonoPath.com**  
info@SonoPath.com