

**DATE PRESENTING CLINICAL SIGNS**

3/30/23 Preoperative neuter. Persistently elevated ALT (160) for 2 months, Mild to moderate post bile acid elevation.

**PATIENT**

Bodie Bowman

Current Medications: None.

Lab Results: 2/13 - ALT 160. 3/27 - ALT 157. 2/16 - Bile acids pre&lt;1, Post 68.7

Date of Previous IntraPet Ultrasound: No previous.

Sedation: Not required to complete full diagnostic ultrasound.

**SPECIES**

Canine

Stat Report: Not requested.

Imaging Performed By: Rachel Brillhart, RDMS.

**BREED**

Toy Poodle

**ULTRASONOGRAPHIC EXAMINATION OF THE ABDOMEN****SEX**

Intact Male

**Urinary System**

The **urinary bladder**, trigone, and pelvic urethra presented normal thicknesses and normal tone. The ureters were not visible which is normal. No uroliths or sediment were visualized and anechoic urine was present. No evidence of inflammatory or neoplastic changes were noted. Ureteral papillae were normal. The prostate was uniform, measuring 2.09 cm.

**AGE**

8/6/22

The **kidneys** revealed normal size and structure, corticomedullary definition and ratio for this age. The cortices presented largely uniform texture with normal echogenic relationship to liver and spleen. Medullary structure differed distinctly from the cortex and no evidence of pelvic dilation was present. The capsules were acceptably uniform without significant irregularities. The left kidney measured 4.67 cm. The right kidney measured 4.1 cm.

**WEIGHT**

16 Pounds

**Adrenal Glands**

Both **adrenal glands** were visualized and recognized as having normal shape, size, position and echogenicity for this breed. The phrenic vasculature, glandular echogenicity and detail were unremarkable. Capsule, cortex, and medullary definition were normal for this age patient. The left adrenal gland measured 1.85 cm x 0.38 cm at the caudal pole and 0.33 cm at the cranial pole.

**INTERPRETED BY**Eric Lindquist, DMV  
DABVP, Cert. IVUS**Spleen**

The **spleen** presented a smooth homogeneous parenchyma hyperechoic to liver and renal cortical parenchyma. The capsule was smooth without noticeable expansion or deviation from within the spleen or adjacent pathology. The splenic vasculature demonstrated normal volume without signs of congestion or thrombosis. No sonographic evidence of acute or chronic inflammatory, neoplastic, or infarctual changes were noted.

**HOSPITAL NAME**

Everhart VH

**REFERRING VET**

Dr. Rubinstein

**Liver**

The **liver** was slightly subnormal in size (2.72 cm in short axis). Structurally unremarkable parenchyma was noted. Portal vein to vena cava ratio was 1:1, at 0.75 cm each. No evidence of intrahepatic or extrahepatic shunting. The gallbladder presented acceptably thin walls with primarily anechoic content. The cystic and common bile ducts were normal.

**INVOICE**

21860

**Gastrointestinal**

Examination of the **gastrointestinal tract** revealed a stomach and intestine free of stasis, of normal wall thickness, acceptable curvilinear mural detail, and peristaltic activity. Small and large intestine demonstrated normal luminal chyme and stool consistency respectively. No obstructive or overt infiltrative disease was noted. No associated abnormal lymphatic activity was noted.

### **Pancreas**

The base and limbs of the **pancreas** were observed to be largely isoechoic to surrounding omental fat. Pancreatic duct and capsular contour were acceptably normal and parenchyma respected normal curvilinear patterns. No overt evidence of active inflammatory or neoplastic disease was noted.

### **Other**

The **testicles** were imaged and found to be uniform with no evidence of pathology.

### **ULTRASONOGRAPHIC FINDINGS**

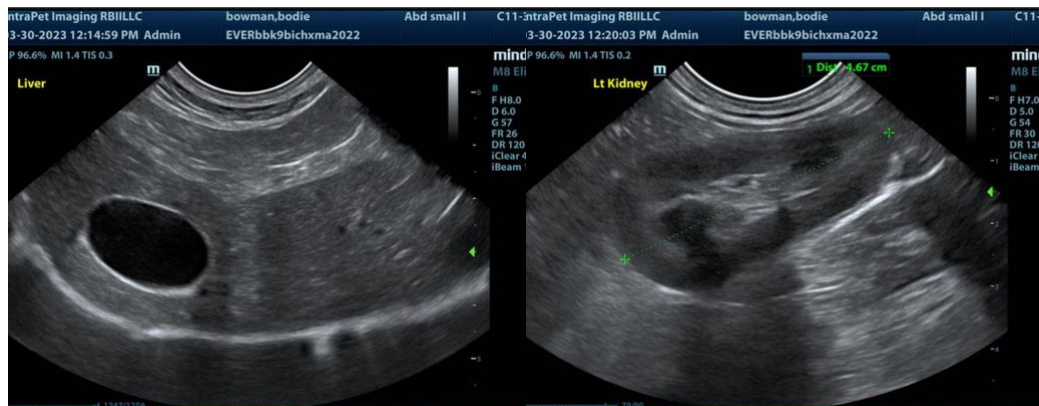
- Minor microhepatica with structurally unremarkable parenchyma- no evidence of macroscopic shunting

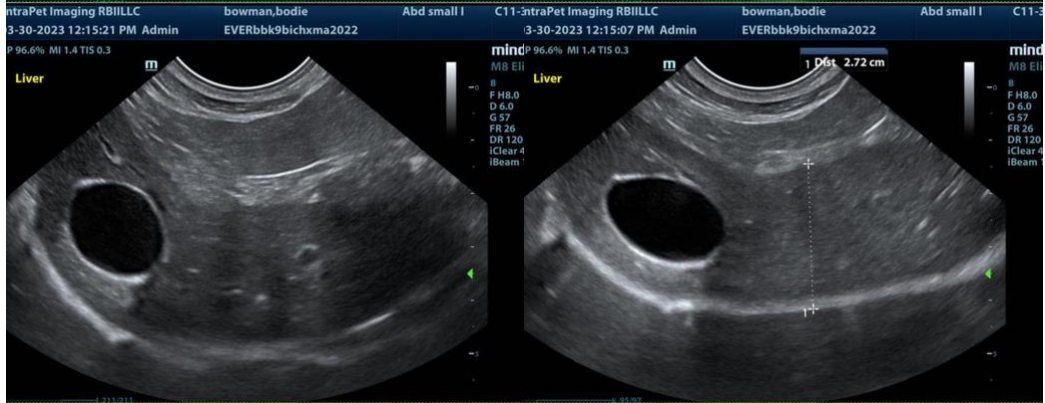
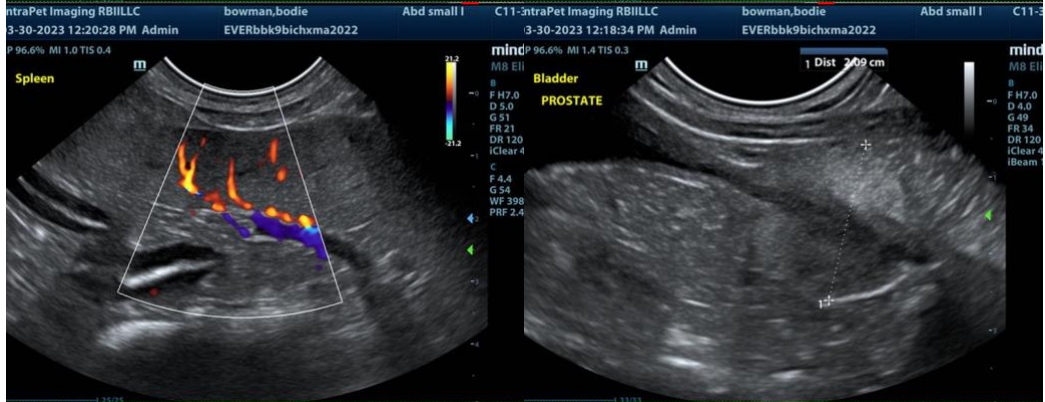
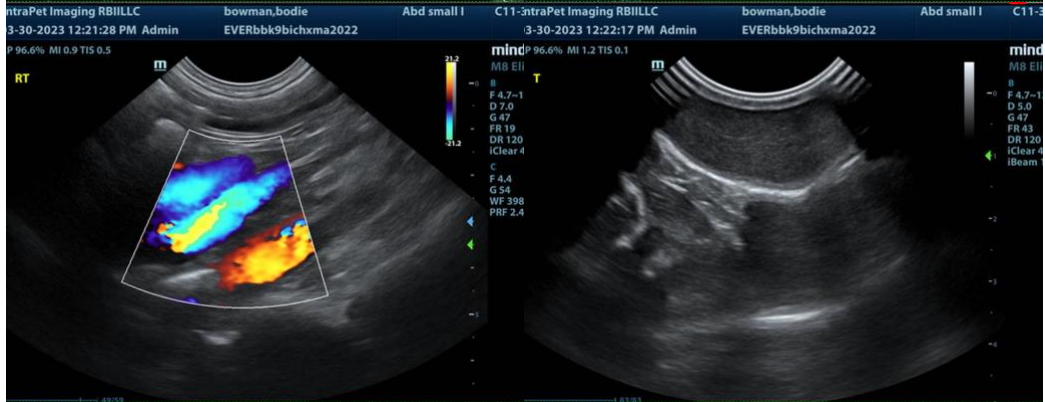
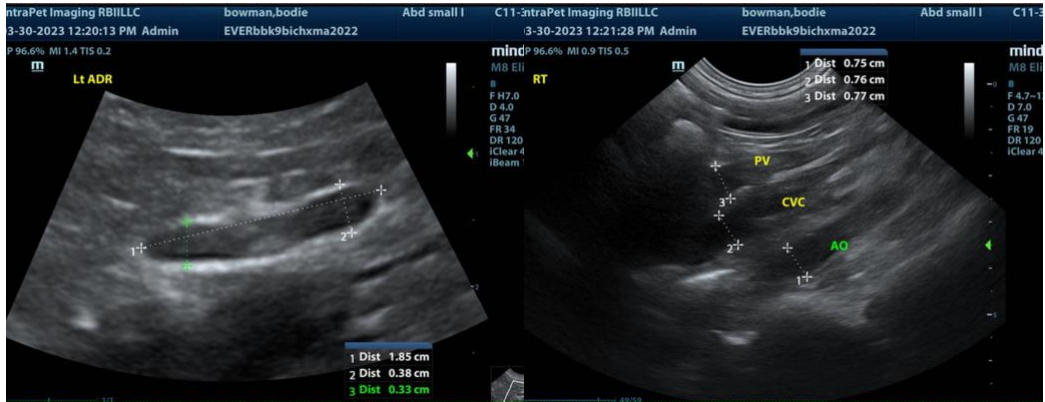
### **INTERPRETATION OF THE FINDINGS & FURTHER RECOMMENDATIONS**

Depending on the level of bile acid elevations, this may be a transient elevation or possible related to portal hypoplasia/microvascular dysplasia, that would necessitate core biopsy for a differential. Given the ALT elevations, reactive hepatopathy is likely or structurally unremarkable inflammatory hepatopathy. FNA could be considered to assess inflammatory cell type.

For an additional charge, internal medicine consult can be utilized through Sonopath.com. You can select the internal medicine drop down at <http://spa.sonopath.com/>.

One of the world's top internists & SonoPath associate Dr. Remo Lobetti BVSc, MMedVet, PhD, DECVIM can evaluate your case through SonoPath. <https://sonopath.com/resources/sonopath-services/internal-medicine-teleconsultation-services>





**The information and recommendations provided are based on the images presented by the referring veterinarian. No evaluation can be communicated regarding pathology that was not visible in the image/video clips provided.**

Thank you for this referral. If the clinical or image interpretation does not parallel your findings or if I can be of any further assistance please contact me.

**Eric Lindquist**, DMV, DABVP, Cert. IVUSS, CEO of SonoPath.com  
info@SonoPath.com