



**PATIENT PRESENTING CLINICAL SIGNS**

Barley Dobosz

History: Patient was diagnosed with Stage V Lymphoma in 10/22. He has just completed the 19 week CHOP protocol on 03/17 and is believed to be in remission at this time. At the time of diagnosis patients disease state was advanced with spread throughout his lungs, liver, spleen, bone marrow and he displayed ocular infiltration also. Patient was also suffering with hemorrhagic diarrhea and bowel infiltration was suspected. Widespread lymphadenopathy was present. P/e today unremarkable and patient is clinically normal at home. This is a routine post chemotherapy abdominal scan  
Abnormal PE/Chem/CBC/UA Results: 03/17: CBC and biochemistry WNL

**SPECIES**

Canine

**BREED**

Shih Tzu

**SEX**

Neutered male

**AGE**

4 years

**WEIGHT**

14.8 lbs

**INTERPRETED BY**

Eric Lindquist, DMV  
DABVP, Cert. IVUSS

**IMAGING PERFORMED BY**

Dr. Tudini

**HOSPITAL NAME**

East Aurora VH

**REFERRING VET**

Dr. Tudini

**INVOICE**

43651

**DATE**

3/30/23

**ULTRASONOGRAPHIC EXAMINATION OF THE ABDOMEN**

**Urinary System**

The **urinary bladder**, trigone, and pelvic urethra presented normal thicknesses and normal tone. The ureters were not visible which is normal. No uroliths or sediment were visualized and anechoic urine was present. No evidence of inflammatory or neoplastic changes was noted. Ureteral papillae were normal.

The **kidneys** revealed largely normal size and structure, corticomedullary definition and ratio (cortex 1/3 of medulla) were essentially maintained with some age-related loss of curvilinear patterns regarding the capsule and C/M junction. The cortices presented largely uniform texture with some increased echogenicity expected for his age patient. Medullary structure differed distinctly from that of the cortex and no evidence of pelvic dilation was present. The left kidney measured 3.8 cm. The right kidney measured 4.4 cm.

**Adrenal Glands**

Both **adrenal glands** were visualized and recognized as having normal shape, size, position and echogenicity for this breed. The phrenic vasculature, glandular echogenicity and detail were unremarkable. Capsule, cortex, and medullary definition were normal for this age patient. The left adrenal gland measured 1.7 x 0.44 cm. The right adrenal gland measured 1.52 x 0.28 cm.

**Spleen**

The **spleen** presented a smooth homogeneous parenchyma hyperechoic to liver and renal cortical parenchyma. The capsule was smooth without noticeable expansion or deviation from within the spleen or adjacent pathology. The splenic vasculature demonstrated normal volume without signs of congestion or thrombosis. No sonographic evidence of acute or chronic inflammatory, neoplastic, or infarctual changes was noted.

**Liver**

The **liver** images from right and left intercostal as well as subcostal views revealed subjectively normal liver size, contour, and structure. Some age-related parenchymal remodeling was noted but likely not clinically significant at this time. Vascular and biliary tracts were of normal volume and no evidence of congestion was noted. The gallbladder presented some dependent debris with essentially normal



**PATIENT**

Barley Dobosz

contour. The cystic and common bile ducts were normal. No overt evidence of active inflammatory, infiltrative or regenerative pathology was noted but should be paired with current or past LE elevations regarding any clinical significance to this presentation. The hepatic lymph nodes were unremarkable.

**SPECIES**

Canine

**Gastrointestinal**

Examination of the **gastrointestinal tract** revealed a stomach and intestine free of stasis, of normal wall thickness, acceptable curvilinear mural detail, and peristaltic activity. Small and large intestine demonstrated normal luminal chyme and stool consistency respectively. No obstructive or overt infiltrative disease was noted. No associated abnormal lymphatic activity was noted.

**BREED**

Shih Tzu

**SEX**

Neutered male

**Pancreas**

The base and limbs of the **pancreas** were observed to be largely isoechoic to surrounding omental fat. Pancreatic duct and capsular contour were acceptably normal and parenchyma respected normal curvilinear patterns. No overt evidence of active inflammatory or neoplastic disease was noted.

**AGE**

4 years

**ULTRASONOGRAPHIC FINDINGS**

Structurally unremarkable abdomen.

**WEIGHT**

14.8 lbs

**INTERPRETATION OF THE FINDINGS & FURTHER RECOMMENDATIONS**

There was no evidence of lesions that would be consistent with lymphoma.

**INTERPRETED BY**

Eric Lindquist, DMV  
DABVP, Cert. IVUSS

**IMAGING PERFORMED BY**

Dr. Tudini

**HOSPITAL NAME**

East Aurora VH

**REFERRING VET**

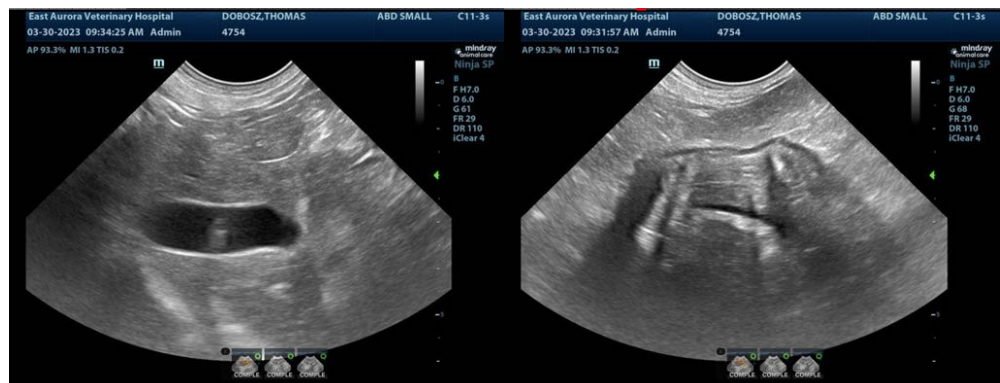Dr. Tudini

**INVOICE**

43651

**DATE**

3/30/23





**PATIENT**

Barley Dobosz

**SPECIES**

Canine

**BREED**

Shih Tzu

**SEX**

Neutered male

**AGE**

4 years

**WEIGHT**

14.8 lbs

**INTERPRETED BY**

Eric Lindquist, DMV  
DABVP, Cert. IVUSS

**IMAGING PERFORMED BY**

Dr. Tudini

**HOSPITAL NAME**

East Aurora VH

**REFERRING VET**

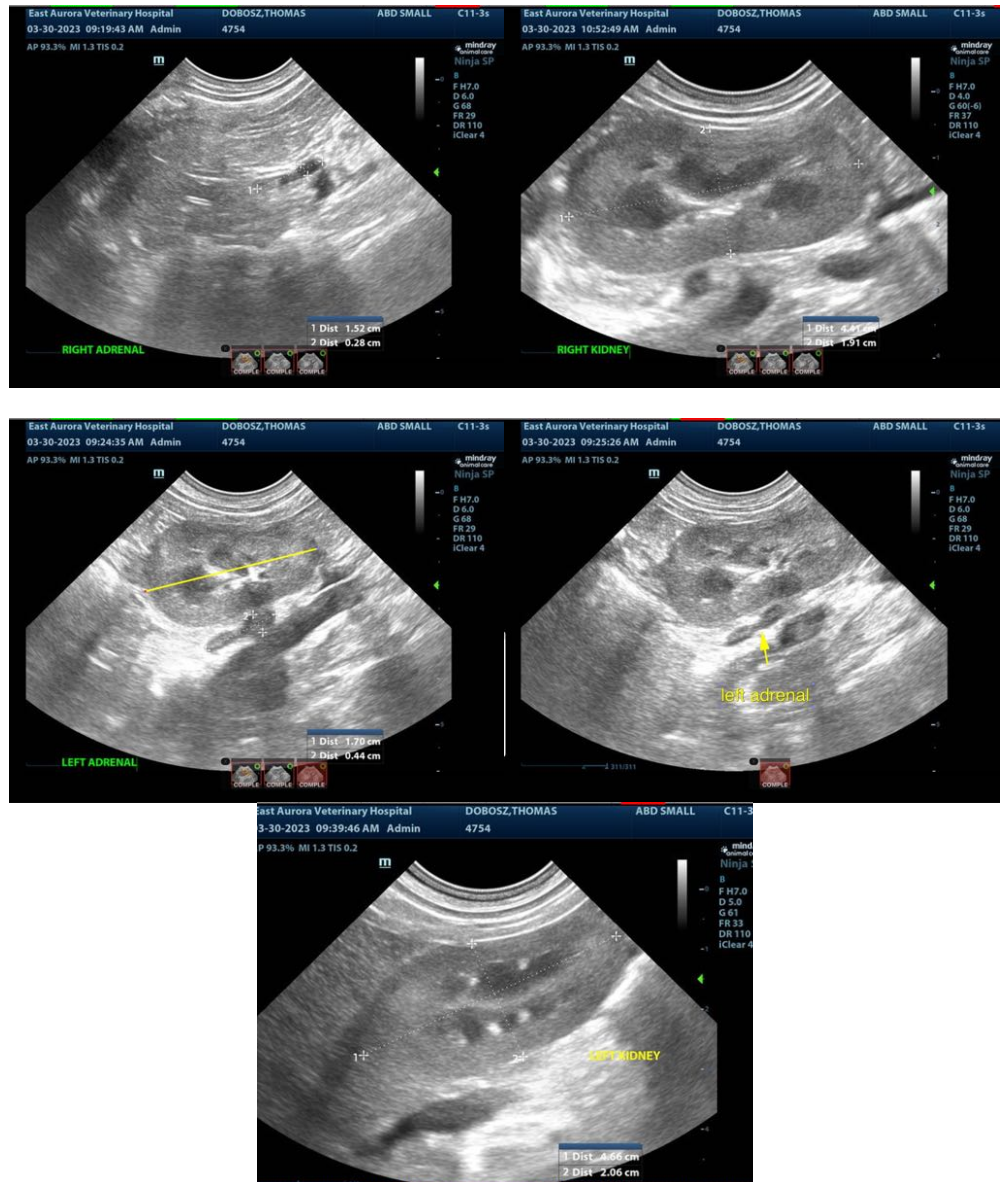
Dr. Tudini

**INVOICE**

43651

**DATE**

3/30/23



The information and recommendations provided are based on the images presented by the referring veterinarian/sonographer. No evaluation can be communicated regarding pathology that was not visible in the image/video clips provided.

Thank you for this referral. If the clinical or image interpretation does not parallel your findings or if I can be of any further assistance please contact me.

**Eric Lindquist, DMV, DABVP, Cert. IVUSS, CEO of SonoPath.com**  
info@SonoPath.com